



PATIENT

Hamilton Romano
Budejen

SPECIES

Canine

BREED

Mini Schnauzer

SEX

Male

AGE

8 years

WEIGHT

19 lbs

INTERPRETED BY

Kathleen Sennello DVM,
MS, Diplomate ACVIM
(Small Animal Internal
Medicine)

IMAGING PERFORMED BY

Dr. Casper

HOSPITAL NAME

Hometown Animal
Hospital - Florida

REFERRING VET

Dr. Gavin Casper

INVOICE

10862

DATE

12/4/2025

PRESENTING CLINICAL SIGNS

Clinically doing well. E/D normally. Exam overall nsf. Presented for annual wellness exam and proteinuria detected on UA sample. Repeat samples confirmed consistent proteinuria. Urine culture negative.

Abnormal PE/Chem/CBC/UA Results: UPCs -1.0 on 10/31, 1.46 on 11/19 BP (doppler) avg - 138mmHg.

ULTRASONOGRAPHIC EXAMINATION OF THE ABDOMEN

Urinary System

The urinary bladder is moderately distended with anechoic urine. The Bladder wall, trigone, ureteral papillae and visible urethra (to a depth of 2cm) appear normal with no evidence of wall thickening, mucosal irregularities, masses or cystic calculi.

The prostate is large (2.88 cm) and hyperechoic.

The left kidney has a normal shape and size (4.7 cm). Overall echogenicity is normal with adequate corticomedullary distinction and a typical 1:3 cortex:medulla ratio. There is no evidence of focal perinephric inflammation or effusion. There is no evidence of pyelectasia, nephroliths, infarcts or hydroureter. Renal vasculature is normal.

The right kidney has a normal shape and size (4.84 cm). Overall echogenicity is normal with adequate corticomedullary distinction and a typical 1:3 cortex:medulla ratio. There is no evidence of focal perinephric inflammation or effusion. There is no evidence of pyelectasia, nephroliths, infarcts or hydroureter. Renal vasculature is normal.

Adrenal Glands

The left adrenal gland is normal in size measuring 0.51 cm at the cranial pole and 0.49 cm at the caudal pole. It is observed in its normal position cranial to the left renal artery. It is normal in appearance (uniformly hypoechoic) and shape with no evidence of a mass effect.

The region of the right adrenal (between right cranial kidney and vena cava) is unremarkable, but the adrenal is not distinctly visualized. No evidence of a mass effect.

Spleen

The spleen is subjectively normal in size (1.9 cm) and the echotexture is homogenous. The splenic capsule is smooth with no visible irregularities. The blood flow through the hilus and splenic parenchyma appears normal. No focal parenchymal abnormalities are visualized.

Liver

The liver is normal in size, and normal in echogenicity with smooth peripheral margins. The parenchyma is heterogenous in echotexture with subtle, indistinct focal mottling. The visible portions of the vasculature and biliary tract appear normal. No focal nodules or cystic lesions are observed.



PATIENT

Hamilton Romano
Budejen

SPECIES

Canine

BREED

Mini Schnauzer

SEX

Male

AGE

8 years

WEIGHT

19 lbs

INTERPRETED BY

Kathleen Sennello DVM,
MS, Diplomate ACVIM
(Small Animal Internal
Medicine)

IMAGING PERFORMED BY

Dr. Casper

HOSPITAL NAME

Hometown Animal
Hospital - Florida

REFERRING VET

Dr. Gavin Casper

INVOICE

10862

DATE

12/4/2025

The gall bladder lumen is moderately distended. The wall of the gall bladder is not thickened and has a smooth mucosal surface. There is a moderate amount of non-organized echogenic debris. The cystic and common bile ducts are normal/not visible.

Gastrointestinal

The stomach contains minimal luminal contents. It measures at a normal thickness of <0.7cm with some variability due to the presence of rugal folds. The distinction of the gastric wall layers is adequate and there is no impression of reduced peristaltic activity. No masses or focal lesions were observed.

The visualized areas of duodenum, jejunum and ileum have a relatively uniform diameter with minimal fluid distension. Wall thickness is normal. Bowel loops follow a curvilinear path with distinct wall layering maintaining the typical 1:3 muscularis:mucosa layer ratio. The duodenum measured as normal (0.44 cm in wall thickness) and the jejunum measured as normal (0.27 cm.) Visualized peristalsis appears appropriate. There were no focal lesions consistent with obstruction or a mass effect observed.

Sections of colon are visualized with formed fecal material and gas shadowing distally. There is no observed focal or generalized colon wall thickening or loss of layering.

Pancreas

The pancreas is normal and isoechoic to surrounding mesentery. There is no evidence of nodules or cystic lesions. There is no evidence of regional mesenteric inflammation or fluid.

Free Abdomen

Evaluation of the peritoneal cavity did not reveal any evidence of effusion, or subjective lymphadenomegaly. The Medial iliac nodes appear normal and there was no evidence of a caudal aortic thrombus at the bifurcation. The omentum is of normal uniform echogenicity.

ULTRASONOGRAPHIC FINDINGS

- Heterogenous liver. The diffuse hepatic changes are non-specific and could be consistent with vacuolar hepatopathy, nodular hyperplasia, inflammatory/immune-mediated disease, infiltrative neoplasia (less likely) or other hepatopathy.
- Moderate gallbladder debris. The significance of the aggregated gallbladder debris is unclear. This could represent an early mucocele, cholestasis, or may be secondary to fasting but seems unlikely to be causing a current issue. Recommend continued monitoring.
- Large, hyperechoic prostate. Findings are normal for an intact male dog.

INTERPRETATION OF THE FINDINGS & FURTHER RECOMMENDATIONS

The changes observed on today's scan are relatively mild. Subjectively, the liver appears heterogenous. The significance of this in the absence of liver enzyme elevations is uncertain. Additionally, there's a moderate amount of debris in the gallbladder but no gallbladder wall thickening or significant inflammation. This is likely incidental at the time and continued monitoring is warranted.

The proteinuria reported is mild. If not already done, always evaluate a pooled urine sample from three



PATIENT

Hamilton Romano Budejen

SPECIES

Canine

BREED

Mini Schnauzer

SEX

Male

AGE

8 years

WEIGHT

19 lbs

INTERPRETED BY

Kathleen Sennello DVM, MS, Diplomate ACVIM (Small Animal Internal Medicine)

IMAGING PERFORMED BY

Dr. Casper

HOSPITAL NAME

Hometown Animal Hospital - Florida

REFERRING VET

Dr. Gavin Casper

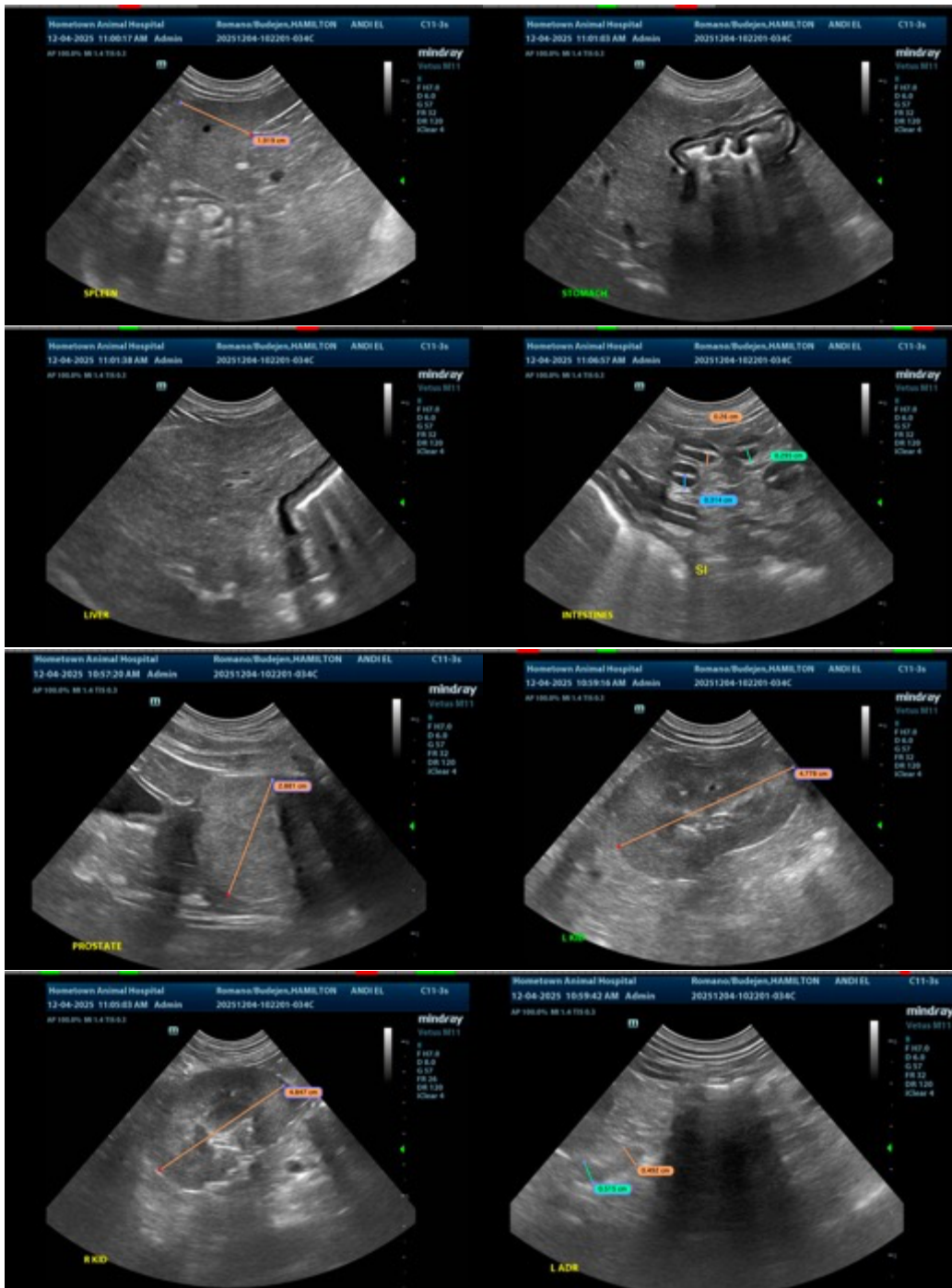
INVOICE

10862

DATE

12/4/2025

clean samples obtained at home as this will obtain a more accurate assessment of proteinuria over the day, and remove the stress factor of the clinic. Additionally, an active sample with a lot of sediment/debris can potentially increase the urine protein levels. Additionally, evaluation for some individuals could include vector borne disease testing and chest radiographs.





PATIENT

Hamilton Romano
Budejen

SPECIES

Canine

BREED

Mini Schnauzer

SEX

Male

AGE

8 years

WEIGHT

19 lbs

INTERPRETED BY

Kathleen Sennello DVM,
MS, Diplomate ACVIM
(Small Animal Internal
Medicine)

IMAGING PERFORMED BY

Dr. Casper

HOSPITAL NAME

Hometown Animal
Hospital - Florida

REFERRING VET

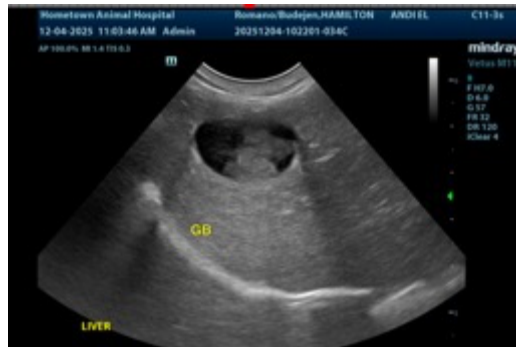Dr. Gavin Casper

INVOICE

10862

DATE

12/4/2025



The information and recommendations provided are based on the images presented by the referring veterinarian/sonographer. No evaluation can be communicated regarding pathology that was not visible in the image/video clips provided.

Thank you for this referral. If the clinical or image interpretation does not parallel your findings or if I can be of any further assistance please contact me.

Kathleen Sennello DVM,MS, Diplomate ACVIM (Small animal Internal Medicine)

info@sonopath.com