



DATE PRESENTING CLINICAL SIGNS

12/4/25 **Patient History:** Denver presented on 11/07/25 for his annual examination. At this visit, owner mentioned an approximately on week history of P having multiple urinary accidents in the house. O also perceived increased thirst. These accidents are conscious and O has not noticed straining.

PATIENT

Denver Harper

Current Medications: None.

Labwork Results: Labwork attached, reported as: Radiographs did not show radiopaque stones. Bloodwork unremarkable. Urinalysis unremarkable but repeatedly dilute (free-catch)

SPECIES

Canine

Date of Previous IntraPet Ultrasound: No previous.

Sedation: IM Zenalpha.

Stat Report: Not requested.

BREED

Imaging Performed by: Rachel Brillhart, RDMS.

Cattle Dog x

ULTRASONOGRAPHIC EXAMINATION OF THE ABDOMEN

SEX

Urinary System

Neutered Male

The urinary bladder is moderately distended with anechoic urine. The Bladder wall, trigone, ureteral papillae and visible urethra (to a depth of 2cm) appear normal with no evidence of wall thickening, mucosal irregularities, masses or cystic calculi.

AGE

9/18/12

The prostate is normal in size (0.51 cm) and shape for this neutered male dog. The parenchyma is homogenous and the external margins are smooth. The prostatic urethra appears normal with no evidence of irregularity, invasion, mass effect or calculi.

WEIGHT

24.4 kg

The left kidney has a normal shape and size (5.96 cm). Overall echogenicity is normal with adequate corticomedullary distinction and a typical 1:3 cortex:medulla ratio. There is no evidence of focal perinephric inflammation or effusion. There is no evidence of pyelectasia, nephroliths, infarcts or hydroureter. Renal vasculature is normal.

INTERPRETED BY

Kathleen Sennello DVM,
MS, Diplomate ACVIM
(Small Animal Internal
Medicine)

The right kidney has a normal shape and size (5.69 cm). Overall echogenicity is normal with adequate corticomedullary distinction and a typical 1:3 cortex:medulla ratio. There is no evidence of focal perinephric inflammation or effusion. There is no evidence of pyelectasia, nephroliths, infarcts or hydroureter. Renal vasculature is normal.

HOSPITAL NAME

Eastern Animal
Hospital

Adrenal Glands

The left adrenal gland is large and hypoechoic, measuring 1.01 cm at the cranial pole and 0.85 cm at the caudal pole. It is observed in its normal position cranial to the left renal artery. It is normal in appearance (uniformly hypoechoic) and shape with no evidence of a mass effect.

REFERRING VET

Dr. Aparicio-Massanett

The right adrenal gland is large and hypoechoic, measuring 1.04 cm at the cranial pole and 1.0 cm at the caudal pole. It is observed in its normal position between the cranial aspect of the right kidney and the caudal vena cava. It is normal in appearance (uniformly hypoechoic) and shape with no evidence of a mass effect.

INVOICE

72361

Spleen

The spleen is normal in size and shape. The blood flow through the hilus and splenic parenchyma appears normal. There is a hypoechoic nodule visualized within the parenchyma measuring 2.04 cm x 1.94 cm.

Liver

The liver is subjectively normal in size, and echogenicity with smooth peripheral margins. The parenchyma is homogenous echotexture. The visible portions of the vasculature and biliary tract appear normal. No focal nodules or cystic lesions are observed.

The gall bladder lumen is moderately distended. The wall of the gall bladder is not thickened and has a smooth mucosal surface. Luminal contents are mild and likely incidental at this time. The cystic and common bile ducts are normal/not visible.

Gastrointestinal

The stomach contains mild fluid/ingesta. It measures at a normal thickness of <0.7cm with some variability due to the presence of rugal folds. The distinction of the gastric wall layers is adequate and there is no impression of reduced peristaltic activity. No masses or focal lesions were observed.

The visualized areas of duodenum, jejunum and ileum have a relatively uniform diameter with minimal fluid distension. Wall thickness is normal. Bowel loops follow a curvilinear path with distinct wall layering maintaining the typical 1:3 muscularis:mucosa layer ratio. Duodenum wall measures 0.42 cm. Jejunum wall measures 0.35 cm. Visualized peristalsis appears appropriate. There were no focal lesions consistent with obstruction or a mass effect observed.

Sections of colon are visualized with formed fecal material and gas shadowing distally. There is no observed focal or generalized colon wall thickening or loss of layering.

Pancreas

The area of the pancreas is normal and isoechoic to surrounding mesentery. There is no evidence of nodules or cystic lesions. There is no evidence of regional mesenteric inflammation or fluid.

Free Abdomen

Evaluation of the peritoneal cavity did not reveal any evidence of effusion, or subjective lymphadenomegaly. The Medial iliac nodes appear normal and there was no evidence of a caudal aortic thrombus at the bifurcation. The omentum is of normal uniform echogenicity.

Other

The right auricle and pericardium were visualized and were unremarkable. No obvious pathology is visualized. If cardiac function evaluation is desired a full echocardiogram is warranted.

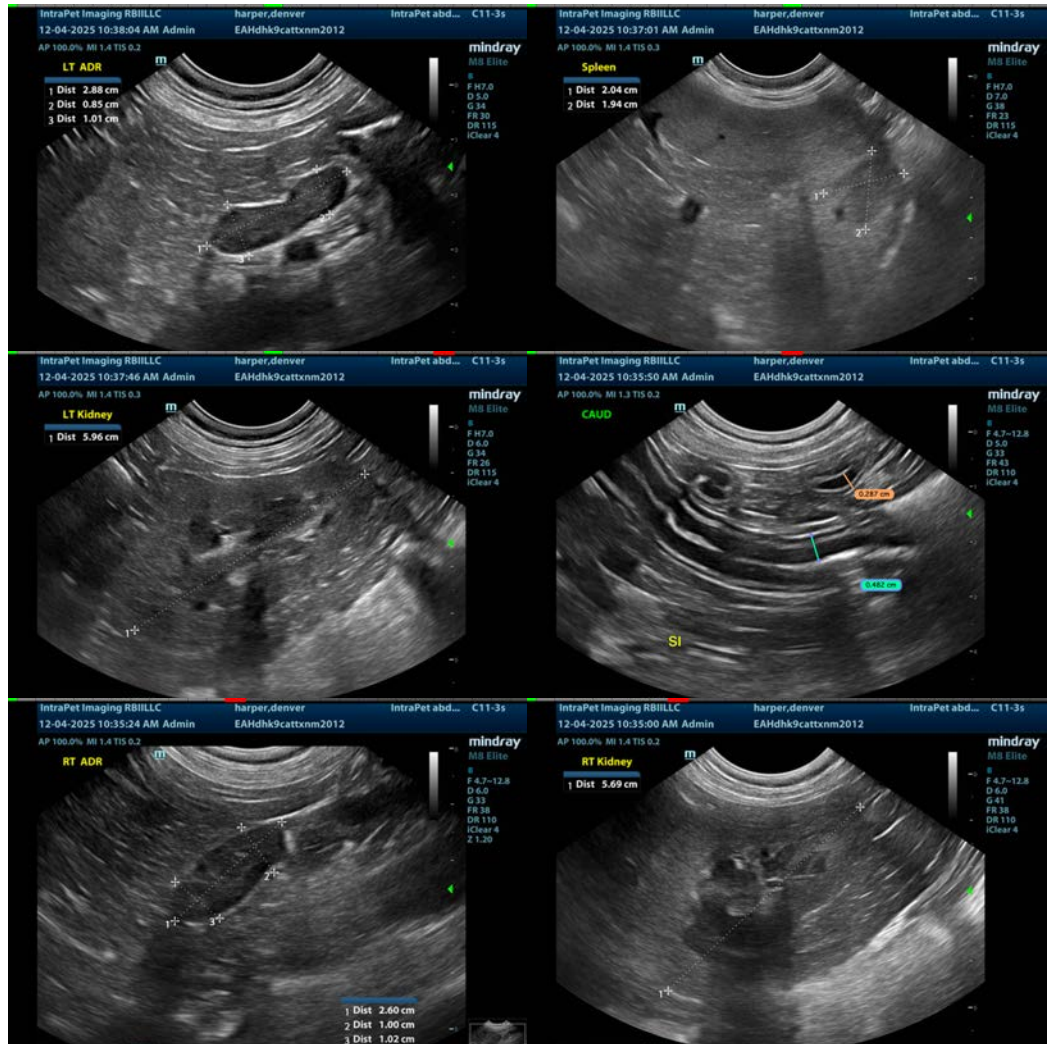
ULTRASONOGRAPHIC FINDINGS

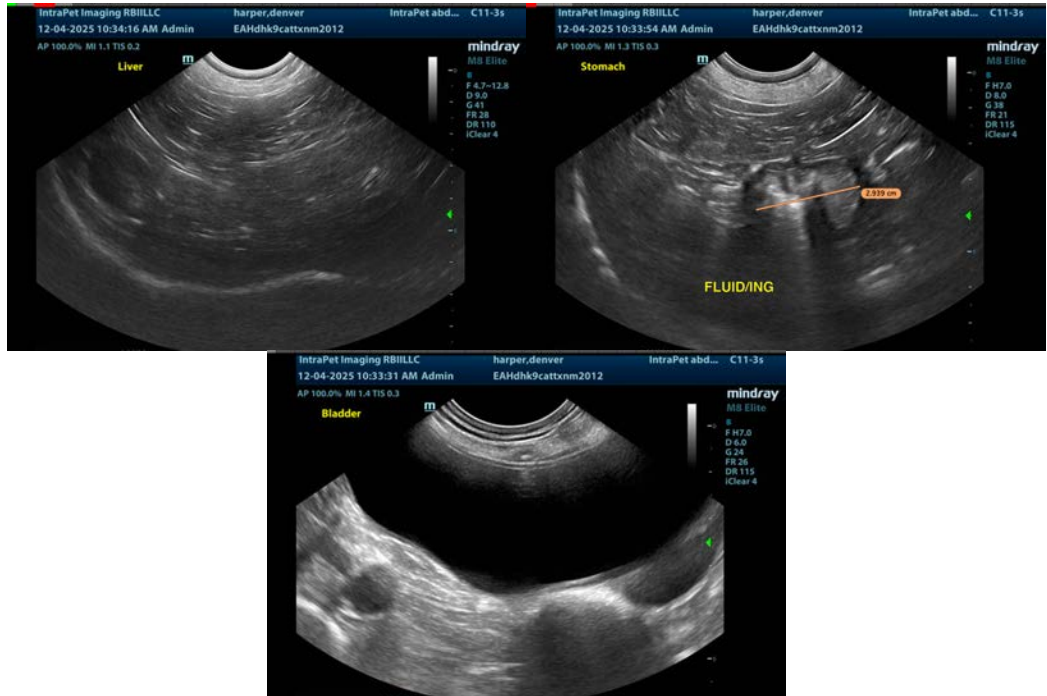
- Bilateral adrenomegaly – The bilateral adrenomegaly could be consistent with bilateral hyperplasia (e.g., secondary to pituitary-dependent hyperadrenocorticism), bilateral infiltrative neoplasia, inflammatory adrenal disease, other. Correlation with clinical findings is recommended.
- Focal hypoechoic nodule visualized in the spleen – There is a non-cavitated, hypoechoic splenic nodule visualized. Differentials include lymphoid hyperplasia, extramedullary hematopoiesis, infiltrative neoplasia, inflammation, other. Cytology or histopathology would be necessary to get a definitive diagnosis.

INTERPRETATION OF THE FINDINGS & FURTHER RECOMMENDATIONS

Both adrenals are hypoechoic, rounded and slightly enlarged. This could represent anatomic variation or early hyperplasia/pituitary dependent hyperadrenocorticism. If symptoms consistent with Cushing's disease are present, consider adrenal function testing.

There is a hypoechoic nodule visualized in the spleen. This could represent a benign or neoplastic lesion. Options moving forward would include a fine needle aspirate or continued monitoring with ultrasound.





The information and recommendations provided are based on the images presented by the referring veterinarian/sonographer. No evaluation can be communicated regarding pathology that was not visible in the image/video clips provided.

Thank you for this referral. If the clinical or image interpretation does not parallel your findings or if I can be of any further assistance please contact me.

Kathleen Sennello DVM,MS, Diplomate ACVIM (Small animal Internal Medicine)
info@sonopath.com