

**PATIENT**

Echo White (PAVE)

SPECIES

Canine

BREED

Labrador Retriever

SEX

Neutered Male

AGE

11 Years

WEIGHT

76 lbs

INTERPRETED BYKathleen Sennello DVM,
MS, Diplomate ACVIM
(Small Animal Internal
Medicine)**IMAGING
PERFORMED BY**

Dr. Mark Schlimgen

HOSPITAL NAMESherwood Family Pet
Clinic**REFERRING VET**

Dr. Mark Schlimgen

INVOICE

72898

DATE

12/31/25

PRESENTING CLINICAL SIGNS

Echo presents with intermittent breathing changes, consistent with mild laryngeal paralysis. Thoracic rads show mild changes consistent with age or mild inflammation. Irregularly margined spleen seen on visible portion of abdomen, ultrasound and cytology recommended by radiologist. Sedated for ultrasound and appears to have laryngeal paralysis on sedated laryngeal exam.

Abnormal PE/Chem/CBC/UA Results: No significant abnormalities with labs other than stable borderline anemia (~40%) historical for pt.

ULTRASONOGRAPHIC EXAMINATION OF THE ABDOMEN**Urinary System**

The urinary bladder is moderately distended with anechoic urine. The Bladder wall, trigone, ureteral papillae and visible urethra (to a depth of 2cm) appear normal with no evidence of wall thickening, mucosal irregularities, masses or cystic calculi.

The visualized areas of prostate and surrounding tissue appear normal. Unfortunately, the prostate is not fully visualized likely due to its intrapelvic location. Correlate with rectal exam findings.

The left kidney has a normal shape and size (5.9 cm). Overall echogenicity is normal with adequate corticomedullary distinction and a typical 1:3 cortex:medulla ratio. There is no evidence of focal perinephric inflammation or effusion. There is no evidence of pyelectasia, nephroliths, infarcts or hydroureter. Renal vasculature is normal.

The right kidney has a normal shape and size (6.24 cm). Overall echogenicity is normal with adequate corticomedullary distinction and a typical 1:3 cortex:medulla ratio. There is no evidence of focal perinephric inflammation or effusion. There is no evidence of pyelectasia, nephroliths, infarcts or hydroureter. Renal vasculature is normal.

Adrenal Glands

The region of left adrenal (Cranial to left renal artery) is unremarkable but the adrenal is not distinctly visualized. No evidence of a mass effect is visualized.

The region of the right adrenal (between right cranial kidney and vena cava) is unremarkable, but the adrenal is not distinctly visualized. No evidence of a mass effect is visualized.

Spleen

The spleen is normal/borderline small in size, irregular in shape (possibly folded in the cranial aspect), and mildly mottled, measuring 1.85 cm in width at the level of the hilus. The blood flow through the hilus and splenic parenchyma appears normal. No focal parenchymal abnormalities are visualized.

Liver

The liver is subjectively normal in size, and echogenicity with smooth peripheral margins. The parenchyma is homogenous echotexture. The visible portions of the vasculature and biliary tract appear normal. No focal nodules or cystic lesions are observed.



PATIENT

Echo White (PAVE)

SPECIES

Canine

BREED

Labrador Retriever

SEX

Neutered Male

AGE

11 Years

WEIGHT

76 lbs

INTERPRETED BY

Kathleen Sennello DVM,
MS, Diplomate ACVIM
(Small Animal Internal
Medicine)

IMAGING PERFORMED BY

Dr. Mark Schlimgen

HOSPITAL NAME

Sherwood Family Pet
Clinic

REFERRING VET

Dr. Mark Schlimgen

INVOICE

72898

DATE

12/31/25

The gall bladder lumen is moderately distended. The wall of the gall bladder is not thickened and has a smooth mucosal surface. Luminal contents are mild and likely incidental at this time. The cystic and common bile ducts are normal/not visible.

Gastrointestinal

The stomach contains minimal luminal contents. It measures at a normal thickness of <0.7cm with some variability due to the presence of rugal folds. The distinction of the gastric wall layers is adequate and there is no impression of reduced peristaltic activity. No masses or focal lesions were observed.

The visualized areas of duodenum, jejunum and ileum have a relatively uniform diameter with minimal fluid distension. Wall thickness is normal. Bowel loops follow a curvilinear path with distinct wall layering maintaining the typical 1:3 muscularis:mucosa layer ratio. The duodenum measured as normal (between 0.3-0.5cm in wall thickness) and the jejunum measured as normal (between 0.2-0.47cm.) Visualized peristalsis appears appropriate. There were no focal lesions consistent with obstruction or a mass effect observed.

Sections of colon are visualized with formed fecal material and gas shadowing distally. There is no observed focal or generalized colon wall thickening or loss of layering.

Pancreas

The pancreas is normal and isoechoic to surrounding mesentery. There is no evidence of nodules or cystic lesions. There is no evidence of regional mesenteric inflammation or fluid.

Free Abdomen

Evaluation of the peritoneal cavity did not reveal any evidence of effusion, or subjective lymphadenomegaly. The Medial iliac nodes appear normal and there was no evidence of a caudal aortic thrombus at the bifurcation. The omentum is of normal uniform echogenicity.

ULTRASONOGRAPHIC FINDINGS

- Borderline small, irregular, mildly mottled spleen – The diffuse splenic changes are non-specific and could be consistent with lymphoid hyperplasia, extramedullary hematopoiesis, infiltrative neoplasia, inflammation, other. Cytology or histopathology would be necessary to get a definitive diagnosis.

INTERPRETATION OF THE FINDINGS & FURTHER RECOMMENDATIONS

No focal lesions are visualized associated with the spleen. Subjectively, it appears somewhat small with irregular margins. On some views it almost appears folded in the cranial aspect, and the parenchyma subjectively appears very mildly mottled. A neoplastic lesion seems less likely, but a fine needle aspirate could be considered to further evaluate (I believe this was performed today). Consider continued monitoring of the spleen over time, looking for progressive changes.



PATIENT

Echo White (PAVE)

SPECIES

Canine

BREED

Labrador Retriever

SEX

Neutered Male

AGE

11 Years

WEIGHT

76 lbs

INTERPRETED BY

Kathleen Sennello DVM,
MS, Diplomate ACVIM
(Small Animal Internal
Medicine)

**IMAGING
PERFORMED BY**

Dr. Mark Schlimgen

HOSPITAL NAME

Sherwood Family Pet
Clinic

REFERRING VET

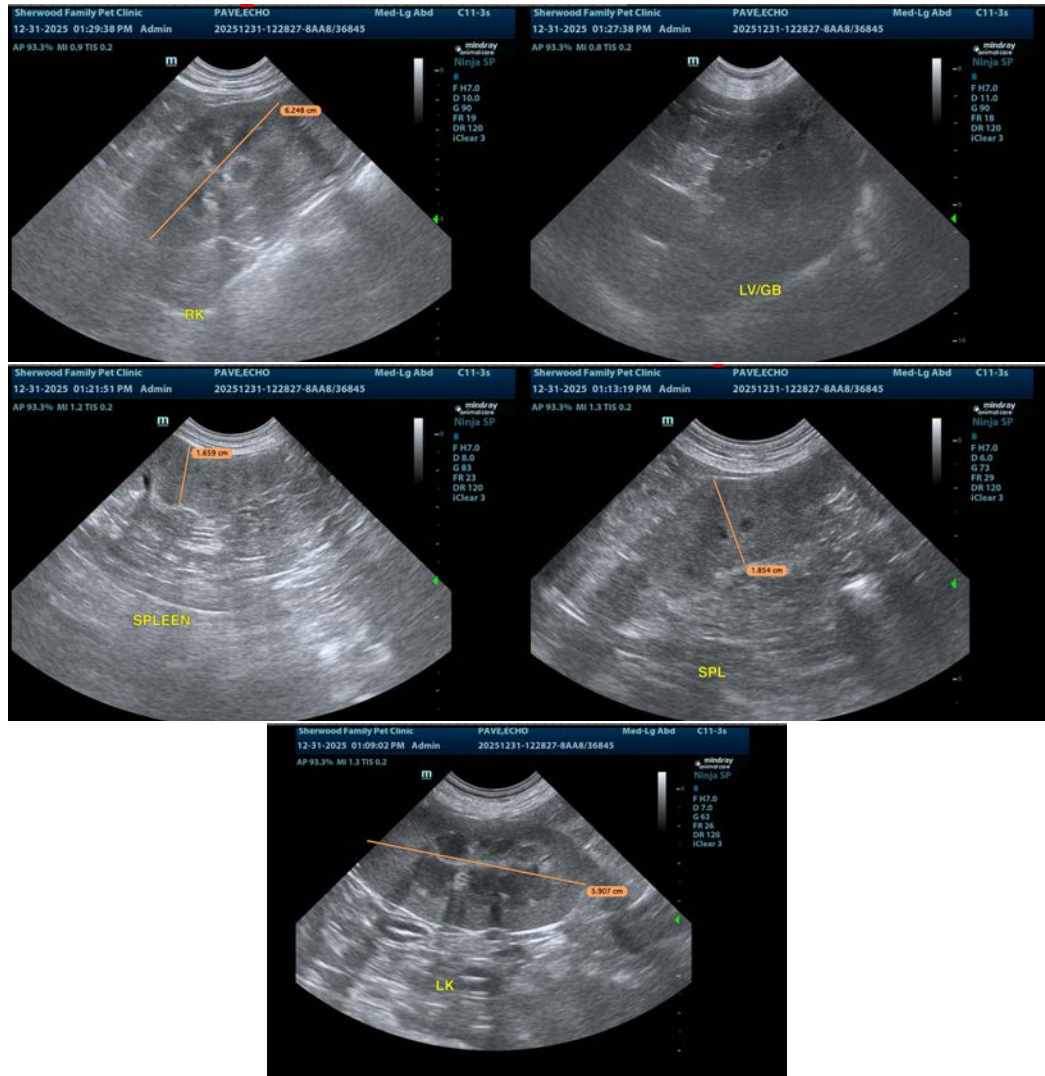
Dr. Mark Schlimgen

INVOICE

72898

DATE

12/31/25



The information and recommendations provided are based on the images presented by the referring veterinarian/sonographer. No evaluation can be communicated regarding pathology that was not visible in the image/video clips provided.

Thank you for this referral. If the clinical or image interpretation does not parallel your findings or if I can be of any further assistance please contact me.

Kathleen Sennello DVM,MS, Diplomate ACVIM (Small animal Internal Medicine)

info@sonopath.com