



PATIENT

Toby Holden

SPECIES

Canine

BREED

Rat Terrier

SEX

Neutered Male

AGE

9 Years

WEIGHT

24 lbs

INTERPRETED BY

Kathleen Sennello DVM,
MS, Diplomate ACVIM
(Small Animal Internal
Medicine)

IMAGING PERFORMED BY

Julia Bakker, DVM

HOSPITAL NAME

Orange Blossom
Veterinary Imaging

REFERRING VET

Dr. Flegel

INVOICE

72877

DATE

12/30/25

PRESENTING CLINICAL SIGNS

Pet presents for persistent loose stools. Labwork shows severe liver enzyme elevations. FNA of liver mass taken today to submit for cytology.

ULTRASONOGRAPHIC EXAMINATION OF THE ABDOMEN

Urinary System

The urinary bladder is moderately distended with anechoic urine. The Bladder wall, trigone, ureteral papillae and visible urethra (to a depth of 2cm) appear normal with no evidence of wall thickening, mucosal irregularities, masses or cystic calculi.

The prostate is normal in size (0.74 cm) and shape for this neutered male dog. The parenchyma is homogenous and the external margins are smooth. The prostatic urethra appears normal with no evidence of irregularity, invasion, mass effect or calculi.

The left kidney has a normal shape and size (4.71 cm). Overall echogenicity is normal with adequate corticomedullary distinction and a typical 1:3 cortex:medulla ratio. There is no evidence of focal perinephric inflammation or effusion. There is no evidence of pyelectasia, nephroliths, infarcts or hydroureter. Renal vasculature is normal.

The right kidney has a normal shape and size (4.88 cm). Overall echogenicity is normal with adequate corticomedullary distinction and a typical 1:3 cortex:medulla ratio. There is no evidence of focal perinephric inflammation or effusion. There is no evidence of pyelectasia, nephroliths, infarcts or hydroureter. Renal vasculature is normal.

Adrenal Glands

The left adrenal gland is normal in size measuring 0.57 cm at the cranial pole and 0.71 cm at the caudal pole. It is observed in its normal position cranial to the left renal artery. It is normal in appearance (uniformly hypoechoic) and shape with no evidence of a mass effect.

The right adrenal gland is normal in size measuring 0.74 cm at the cranial pole and 0.37 cm at the caudal pole. It is observed in its normal position between the cranial aspect of the right kidney and the caudal vena cava. It is normal in appearance (uniformly hypoechoic) and shape with no evidence of a mass effect.

Spleen

The spleen is subjectively normal in size (1.17 cm), echotexture is homogenous, and the splenic capsule is smooth with no irregularities. The blood flow through the hilus and splenic parenchyma appears normal. No focal parenchymal abnormalities are visualized.

Liver

The liver is large, heterogeneous and irregular. The visible portions of the vasculature and biliary tract appear normal. There is a large, mixed echogenicity, hypoechoic, partially cavitated mass effect visualized in the mid cranial right aspect of the liver measuring 6.56 cm x 5.22 cm.

The gall bladder lumen is moderately distended. The wall of the gall bladder is not thickened and has a smooth mucosal surface. Luminal contents are mild and likely incidental at this time. The cystic and common bile ducts are normal/not visible.



PATIENT

Toby Holden

SPECIES

Canine

BREED

Rat Terrier

SEX

Neutered Male

AGE

9 Years

WEIGHT

24 lbs

INTERPRETED BY

Kathleen Sennello DVM,
MS, Diplomate ACVIM
(Small Animal Internal
Medicine)

IMAGING PERFORMED BY

Julia Bakker, DVM

HOSPITAL NAME

Orange Blossom
Veterinary Imaging

REFERRING VET

Dr. Flegel

INVOICE

72877

DATE

12/30/25

Gastrointestinal

The stomach contains mild shadowing ingesta. It measures at a normal thickness of <0.7cm with some variability due to the presence of rugal folds. The distinction of the gastric wall layers is adequate and there is no impression of reduced peristaltic activity. No masses or focal lesions were observed.

The visualized areas of duodenum, jejunum and ileum have a relatively uniform diameter with minimal fluid distension. Wall thickness is normal. Bowel loops follow a curvilinear path with distinct wall layering maintaining the typical 1:3 muscularis:mucosa layer ratio. The duodenum measured as normal (between 0.3-0.5cm in wall thickness) and the jejunum measured as normal (between 0.2-0.47cm.) Visualized peristalsis appears appropriate. There were no focal lesions consistent with obstruction or a mass effect observed.

Sections of colon are visualized with formed fecal material and gas shadowing distally. There is no observed focal or generalized colon wall thickening or loss of layering.

Pancreas

The left limb of the pancreas is prominent and mottled compared to the surrounding isoechoic mesentery. There is no evidence of nodules or cystic lesions. There is no evidence of regional mesenteric inflammation or fluid.

Free Abdomen

There is scant free fluid noted. No significant lymphadenopathy noted. The omentum is hyperechoic in the cranial abdomen.

ULTRASONOGRAPHIC FINDINGS

- Pancreatic changes most consistent with chronic pancreatic remodeling +/- chronic inflammation.
- Large, hypoechoic, mixed echogenicity, partially cavitated liver mass lesion – Findings are concerning for a neoplastic lesion (sarcoma, carcinoma, other). A benign lesion such as an atypical abscess, etc. is possible.
- Scant free abdominal fluid.

INTERPRETATION OF THE FINDINGS & FURTHER RECOMMENDATIONS

There is a large, hypoechoic, mixed echogenicity, partially cavitated mass effect visualized in the cranial mid right region of the liver. This is concerning for a neoplastic lesion, although a benign or inflammatory lesion is possible. If a safe window for sampling is available, consider a fine needle aspirate for cytologic evaluation.

Ideally, consider a contrast CT scan to better evaluate the extent and nature of the lesion and to assess for possible surgical removal.

You could consider sampling of the free abdominal fluid, looking for any evidence of neoplastic cells. Additionally, 3-view thoracic radiographs are recommended if not already done.



PATIENT

Toby Holden

SPECIES

Canine

BREED

Rat Terrier

SEX

Neutered Male

AGE

9 Years

WEIGHT

24 lbs

INTERPRETED BY

Kathleen Sennello DVM,
MS, Diplomate ACVIM
(Small Animal Internal
Medicine)

**IMAGING
PERFORMED BY**

Julia Bakker, DVM

HOSPITAL NAME

Orange Blossom
Veterinary Imaging

REFERRING VET

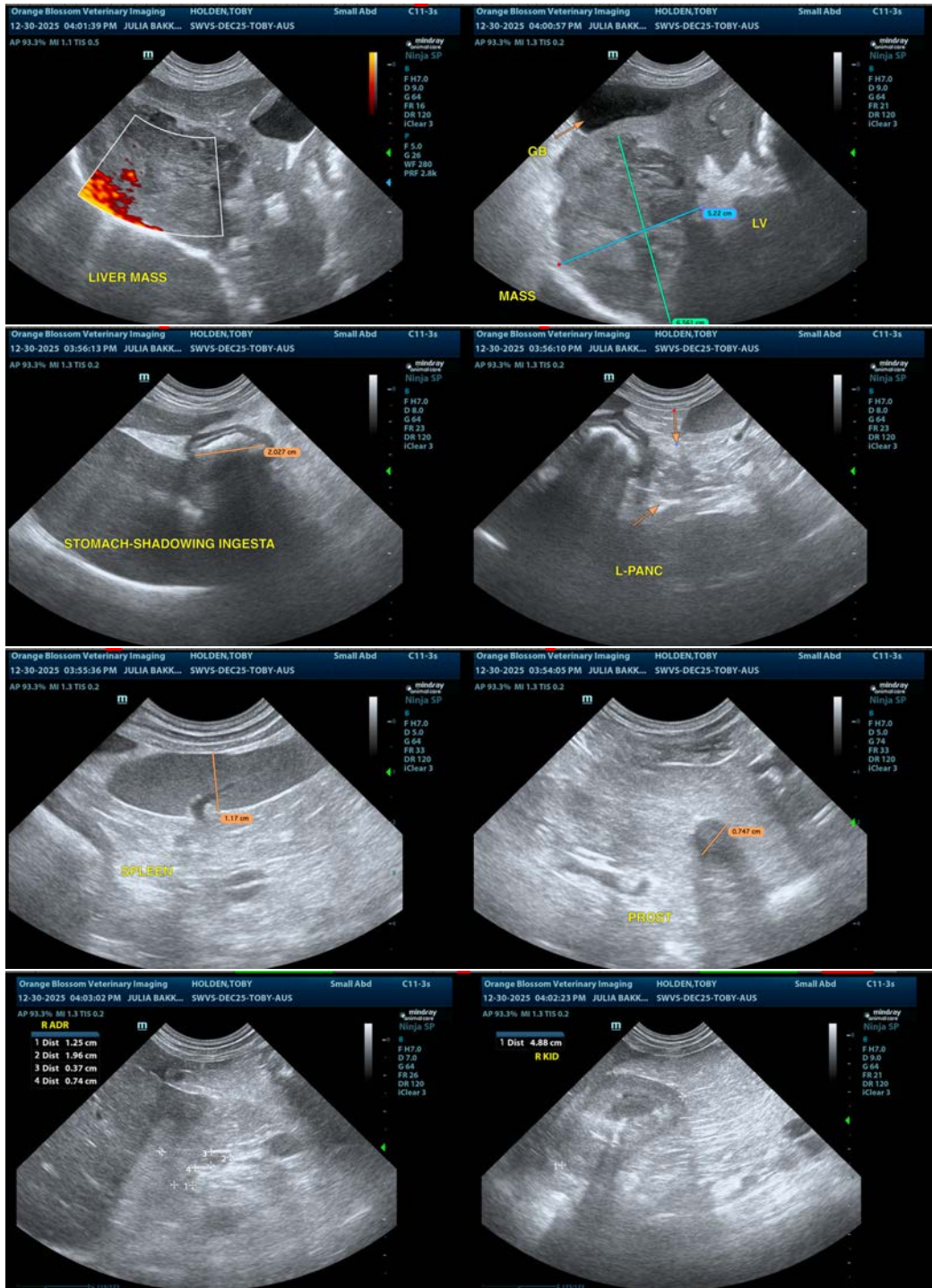
Dr. Flegel

INVOICE

72877

DATE

12/30/25





PATIENT

Toby Holden

SPECIES

Canine

BREED

Rat Terrier

SEX

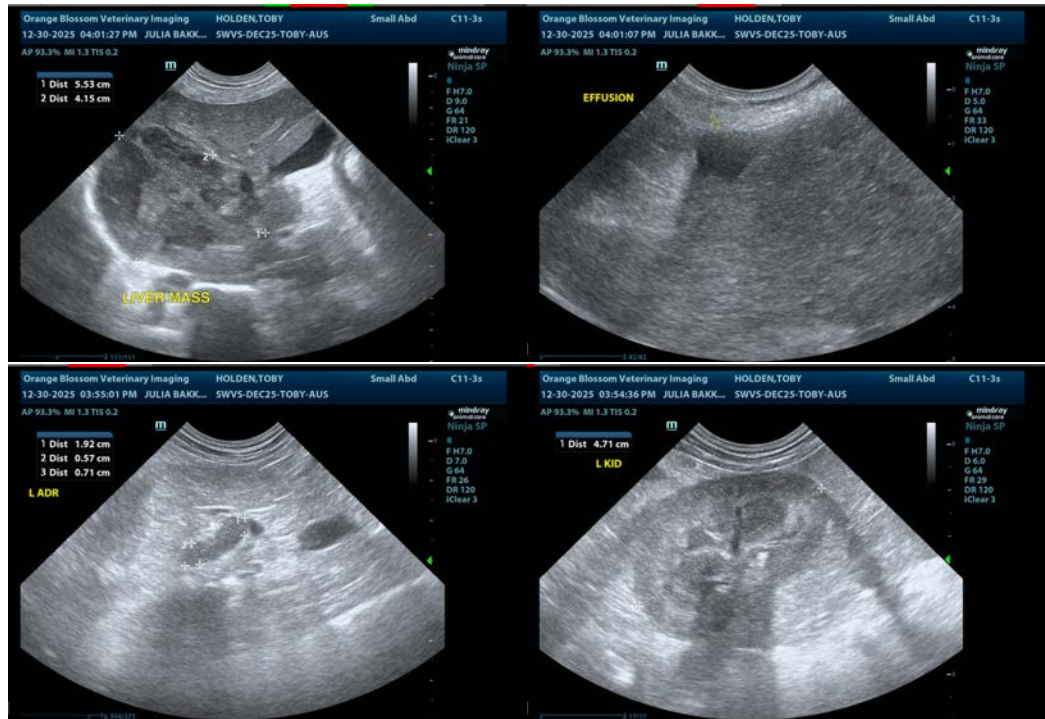
Neutered Male

AGE

9 Years

WEIGHT

24 lbs



INTERPRETED BY

Kathleen Sennello DVM,
MS, Diplomate ACVIM
(Small Animal Internal
Medicine)

IMAGING PERFORMED BY

Julia Bakker, DVM

HOSPITAL NAME

Orange Blossom
Veterinary Imaging

REFERRING VET

Dr. Flegel

INVOICE

72877

DATE

12/30/25

The information and recommendations provided are based on the images presented by the referring veterinarian/sonographer. No evaluation can be communicated regarding pathology that was not visible in the image/video clips provided.

Thank you for this referral. If the clinical or image interpretation does not parallel your findings or if I can be of any further assistance please contact me.

Kathleen Sennello DVM,MS, Diplomate ACVIM (Small animal Internal Medicine)

info@sonopath.com