

PATIENT

Teddy Valentine

SPECIES

Canine

BREED

Bichon Frise

SEX

Neutered Male

AGE

10 Years

WEIGHT

24.3 lbs

INTERPRETED BY

Kathleen Sennello DVM,
MS, Diplomate ACVIM
(Small Animal Internal
Medicine)

**IMAGING
PERFORMED BY**

Pamela Harrigan,
RDCS, Certified Vet
Sonographer

HOSPITAL NAME

Chase Veterinary
Clinic

REFERRING VET

Catherine Caffarella,
BVSc

INVOICE

72858

DATE

12/30/25

PRESENTING CLINICAL SIGNS

Chronically elevated ALT (303) and ALP (>2000); no clinical signs. On Denamarin 225 mg SID

ULTRASONOGRAPHIC EXAMINATION OF THE ABDOMEN

Urinary System

The urinary bladder is moderately distended with anechoic urine. The Bladder wall, trigone, ureteral papillae and visible urethra (to a depth of 2cm) appear normal with no evidence of wall thickening, mucosal irregularities, masses or cystic calculi.

The prostate is normal in size (0.68 cm) and shape for this neutered male dog. The parenchyma is homogenous and the external margins are smooth. The prostatic urethra appears normal with no evidence of irregularity, invasion, mass effect or calculi.

The left kidney has a normal shape and size (5.15 cm) with occasional small cortical cysts. Overall echogenicity is slightly hyperechoic with poor corticomedullary distinction and a typical 1:3 cortex:medulla ratio. There is no evidence of focal perinephric inflammation or effusion. There is no evidence of pyelectasia, nephroliths, infarcts or hydroureter. Renal vasculature is normal.

The right kidney has a normal shape and size (4.57 cm) with occasional small cortical cysts. Overall echogenicity is normal with adequate corticomedullary distinction and a typical 1:3 cortex:medulla ratio. There is no evidence of focal perinephric inflammation or effusion. There is no evidence of pyelectasia, nephroliths, infarcts or hydroureter. Renal vasculature is normal.

Adrenal Glands

The left adrenal gland is normal in size measuring 0.60 cm at the cranial pole and 0.63 cm at the caudal pole. It is observed in its normal position cranial to the left renal artery. It is normal in appearance (uniformly hypoechoic) and shape with no evidence of a mass effect.

The right adrenal gland is normal in size measuring 0.51 cm at the cranial pole and 0.67 cm at the caudal pole. It is observed in its normal position between the cranial aspect of the right kidney and the caudal vena cava. It is normal in appearance (uniformly hypoechoic) and shape with no evidence of a mass effect.

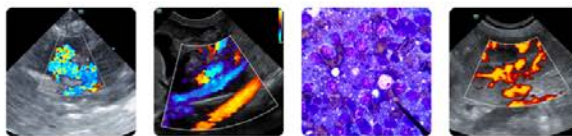
Spleen

The spleen is subjectively normal in size(1.33 cm), echotexture is homogenous, and the splenic capsule is smooth with no irregularities. The blood flow through the hilus and splenic parenchyma appears normal. No focal parenchymal abnormalities are visualized.

Liver

The liver is large in size, hyperechoic, and rounded. The parenchyma is heterogenous in echotexture with subtle, indistinct focal mottling. The visible portions of the vasculature and biliary tract appear normal. No focal nodules or cystic lesions are observed.

The gall bladder lumen is significantly distended. Some areas of the wall appear mildly thickened with adherent debris. There is a large amount of primarily non-organized echogenic debris. There is no evidence of bile duct dilation.



PATIENT

Teddy Valentine

SPECIES

Canine

BREED

Bichon Frise

SEX

Neutered Male

AGE

10 Years

WEIGHT

24.3 lbs

INTERPRETED BY

Kathleen Sennello DVM,
MS, Diplomate ACVIM
(Small Animal Internal
Medicine)

**IMAGING
PERFORMED BY**

Pamela Harrigan,
RDCS, Certified Vet
Sonographer

HOSPITAL NAME

Chase Veterinary
Clinic

REFERRING VET

Catherine Caffarella,
BVSc

INVOICE

72858

DATE

12/30/25

Gastrointestinal

The stomach contains minimal luminal contents. It measures at a normal thickness of <0.7cm with some variability due to the presence of rugal folds. The distinction of the gastric wall layers is adequate and there is no impression of reduced peristaltic activity. No masses or focal lesions were observed.

The visualized areas of duodenum, jejunum and ileum have a relatively uniform diameter with minimal fluid distension. Wall thickness is normal. Bowel loops follow a curvilinear path with distinct wall layering maintaining the typical 1:3 muscularis:mucosa layer ratio. Duodenum wall measures 0.54 cm. Jejunum wall measures 0.37 cm. Visualized peristalsis appears appropriate. There were no focal lesions consistent with obstruction or a mass effect observed.

Sections of colon are visualized with formed fecal material and gas shadowing distally. There is no observed focal or generalized colon wall thickening or loss of layering.

Pancreas

The pancreas is normal and isoechoic to surrounding mesentery. There is no evidence of nodules or cystic lesions. There is no evidence of regional mesenteric inflammation or fluid.

Free Abdomen

Evaluation of the peritoneal cavity did not reveal any evidence of effusion, or subjective lymphadenomegaly. The Medial iliac nodes appear normal and there was no evidence of a caudal aortic thrombus at the bifurcation. The omentum is of normal uniform echogenicity.

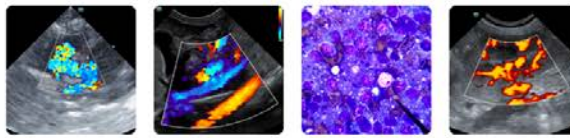
ULTRASONOGRAPHIC FINDINGS

- Age related changes visualized associated with both kidneys.
- Large, heterogeneous, hyperechoic, rounded liver – The diffuse hepatic changes are non-specific and could be consistent with vacuolar hepatopathy, nodular hyperplasia, inflammatory/immune-mediated disease, fibrosis, extramedullary hematopoiesis, toxic hepatopathy (e.g., copper), infiltrative neoplasia (less likely) or other hepatopathy.
- Large, distended gallbladder with a large amount of non-organized echogenic debris – A large amount of debris is evident in the gall bladder with no evidence of a mucocele or associated inflammation at this time. This could represent an early mucocele or cholestasis, with minimal evidence of associated inflammation at this time. Continued monitoring of labwork and ultrasound are warranted for progression of this lesion. Ursodiol therapy could be considered.

INTERPRETATION OF THE FINDINGS & FURTHER RECOMMENDATIONS

The liver appears large, heterogeneous, and hyperechoic with rounded margins. The appearance is most consistent with a vacuolar hepatopathy, although other hepatopathies are possible. Consider a liver function test +/- a fine needle aspirate of the liver as a baseline with continued monitoring. Infiltrative neoplasia or other differentials are less likely but cannot be ruled out.

There is a large amount of debris visualized within the gallbladder with no evidence of wall thickening or surrounding inflammation. Recommend starting chronic Ursodiol therapy and continued monitoring of the gallbladder for progression to a mucocele or for evidence of cholecystitis.



PATIENT

Teddy Valentine

SPECIES

Canine

BREED

Bichon Frise

SEX

Neutered Male

AGE

10 Years

WEIGHT

24.3 lbs

INTERPRETED BY

Kathleen Sennello DVM,
MS, Diplomate ACVIM
(Small Animal Internal
Medicine)

**IMAGING
PERFORMED BY**

Pamela Harrigan,
RDCS, Certified Vet
Sonographer

HOSPITAL NAME

Chase Veterinary
Clinic

REFERRING VET

Catherine Caffarella,
BVSc

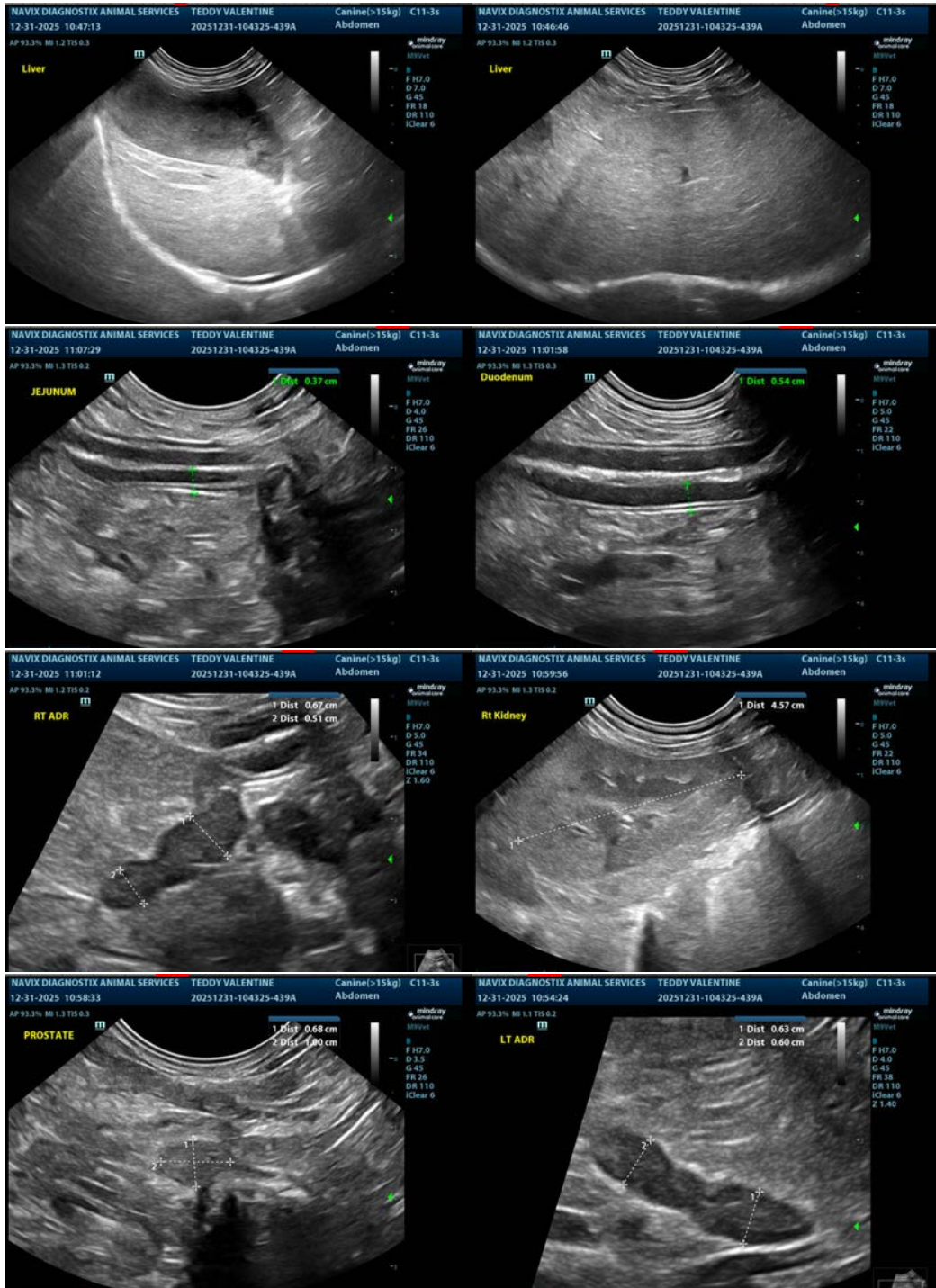
INVOICE

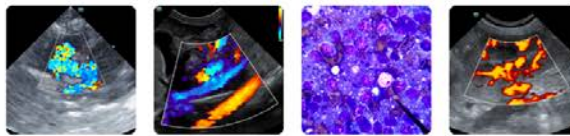
72858

DATE

12/30/25

Both adrenals appear normal in size. If signs of Cushing's are present, you could consider adrenal function testing. Additionally, there is reduced corticomedullary distinction in both kidneys, possibly consistent with early renal disease. Correlate with urinalysis +/- culture and urine protein to creatinine ratio.





PATIENT

Teddy Valentine

SPECIES

Canine

BREED

Bichon Frise

SEX

Neutered Male

AGE

10 Years

WEIGHT

24.3 lbs

INTERPRETED BY

Kathleen Sennello DVM,
MS, Diplomate ACVIM
(Small Animal Internal
Medicine)

**IMAGING
PERFORMED BY**

Pamela Harrigan,
RDMS, Certified Vet
Sonographer

HOSPITAL NAME

Chase Veterinary
Clinic

REFERRING VET

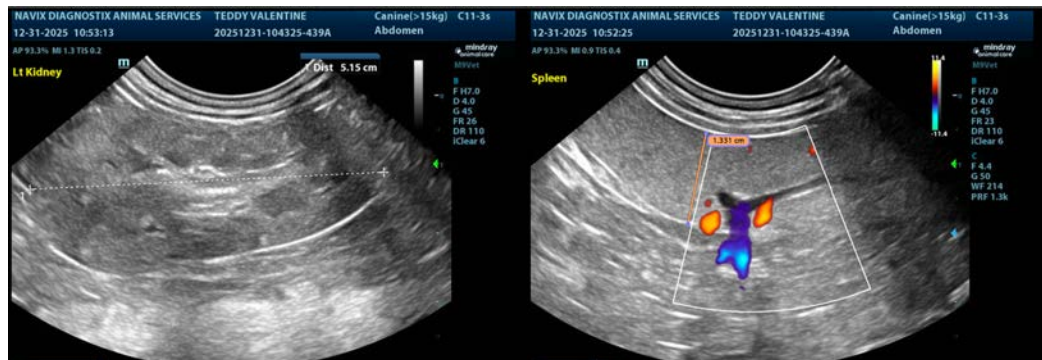
Catherine Caffarella,
BVSc

INVOICE

72858

DATE

12/30/25



The information and recommendations provided are based on the images presented by the referring veterinarian/sonographer. No evaluation can be communicated regarding pathology that was not visible in the image/video clips provided.

Thank you for this referral. If the clinical or image interpretation does not parallel your findings or if I can be of any further assistance please contact me.

Kathleen Sennello DVM,MS, Diplomate ACVIM (Small animal Internal Medicine)

info@sonopath.com