



PATIENT PRESENTING CLINICAL SIGNS

PATIENT Meeka Roksa
History: History of heart murmur and some ongoing urinary issues. Seen recently for being quiet, seeming like she was constipated, weakened and not walking properly. On exam had guarded abdomen, no cough. Xrays showed suspected large soft mass and no feces.

SPECIES

SPECIES Canine
Abnormal PE/Chem/CBC/UA Results: Please see attached rads and bloodwork.

BREED

BREED Yorkie

SEX

SEX Spayed Female

AGE

AGE 10 Years

WEIGHT

WEIGHT 9.8 Lbs.

INTERPRETED BY

Kathleen Sennello DVM,
MS, Diplomate ACVIM
(Small Animal Internal
Medicine)

IMAGING PERFORMED BY

Crystal Hill

HOSPITAL NAME

AH of Stoney Creek

REFERRING VET

Dr. Ozimok

INVOICE

13244

DATE

12/30/21

ULTRASONOGRAPHIC EXAMINATION OF THE ABDOMEN

Urinary System

The urinary bladder is mildly distended with anechoic urine. The Bladder wall appears slightly irregular and thickened, measuring at a maximum width of 0.52 cm. The area of the trigone, ureteral papilla and proximal urethra (to a depth of 2 cm) appear normal and free of any evidence of masses or calculi. Findings are most consistent with cystitis or lack of urine distention.

The left kidney has a normal shape and size (3.83 cm). Overall echogenicity is normal with adequate corticomedullary distinction and a typical 1:3 cortex:medulla ratio. There is no evidence of perinephric inflammation or effusion. A small cortical cyst was present. There is no evidence of pyelectasia, nephroliths, infarcts or hydroureter. Renal vasculature is normal.

The right kidney has a normal shape and size (4.32 cm). Overall echogenicity is normal with adequate corticomedullary distinction and a typical 1:3 cortex:medulla ratio. There is no evidence of perinephric inflammation or effusion. There is no evidence of pyelectasia, nephroliths, infarcts or hydroureter. Renal vasculature is normal.

Adrenal Glands

The left adrenal gland is normal in size measuring 0.46 cm at the caudal pole. It is observed in its normal position cranial to the left renal artery. It is normal in appearance (uniformly hypoechoic) and shape with no evidence of a mass effect.

The right adrenal gland is normal in size measuring 0.63 cm at the caudal pole. It is observed in its normal position between the cranial aspect of the right kidney and the caudal vena cava. It is normal in appearance (uniformly hypoechoic) and shape with no evidence of a mass effect.

Spleen

The spleen is subjectively normal in size, echotexture is homogenous, and the splenic capsule is smooth with no irregularities. The blood flow through the hilus and splenic parenchyma appears normal. No focal parenchymal abnormalities are visualized in the body of the spleen but an attachment to the mid abdominal mass is possible.

Liver

The liver is subjectively normal in size, and echogenicity with smooth peripheral margins. The parenchyma is heterogenous in echotexture with subtle, indistinct focal mottling. The visible portions of the vasculature and biliary tract appear normal. No focal nodules or cystic lesions are observed.

The gall bladder lumen is moderately distended. The wall of the gall bladder is not thickened and has a smooth mucosal surface. There is a moderate amount of non-organized echogenic debris. The cystic and common bile ducts are normal/not visible.

Gastrointestinal



PATIENT

Meeka Roksa

The stomach contains minimal luminal contents. It measures at a normal thickness of <0.7 cm with some variability due to the presence of rugal folds. The distinction of the gastric wall layers is adequate and there is no impression of reduced peristaltic activity. No masses or focal lesions were observed.

SPECIES

Canine

The visualized areas of duodenum, jejunum and ileum have a relatively uniform diameter with minimal fluid distension. Wall thickness is normal. Bowel loops follow a curvilinear path with distinct wall layering maintaining the typical 1:3 muscularis:mucosa layer ratio. The duodenum measured as normal (between 0.3-0.5 cm in wall thickness) and the jejunum measured as normal (between 0.2-0.47 cm.)

BREED

Yorkie

Visualized peristalsis appears appropriate. There were no focal lesions consistent with obstruction or a mass effect observed.

SEX

Spayed Female

The ileocecal junction was visualized and exhibited normal intact wall layering and is subjectively of normal thickness. Sections of colon are visualized with formed fecal material and gas shadowing distally. There is no observed focal or generalized colon wall thickening or loss of layering.

Pancreas

AGE

10 Years

The area of the right limb of the pancreas is largely obscured with the abdominal mass (see description under other). This could possibly be of pancreatic origin.

Free Abdomen

WEIGHT

9.8 Lbs.

There is a moderate to large amount of anechoic free fluid. No lymphadenopathy is noted. The mesentery is of increased echogenicity around the large abdominal mass.

Other

INTERPRETED BY

Kathleen Sennello DVM,
MS, Diplomate ACVIM
(Small Animal Internal
Medicine)

A brief view of the heart was submitted. No pericardial effusion was seen.

There is a large mixed echogenicity partially cavitated, cranial to mid abdominal mass (5.38 cm x 3.78 cm). This mass lies caudal to the liver and medial to the right kidney. It is large enough to potentially contact the liver/spleen and it lies in the area of the pancreas. A distinct connection to these structures cannot be visualized. Of primary concern would be a pancreatic or splenic mass.

ULTRASONOGRAPHIC FINDINGS

IMAGING PERFORMED BY

Crystal Hill

Primary Findings

- Large mixed echogenicity abdominal mass. Organ of origin is uncertain. Primary differential would be that it's arising from either the spleen or pancreas, liver is also possible.

HOSPITAL NAME

AH of Stoney Creek

- Large volume free abdominal fluid. This is likely secondary to the mass effect, Recommend fluid analysis and cytology.

REFERRING VET

Dr. Ozimok

Secondary Findings

- Slightly irregular urinary bladder mucosa. The bladder mucosal changes could be consistent with cystitis or artifactual due to lack of adequate luminal distension. Bladder neoplasia cannot be ruled out but is considered unlikely in this patient.

INVOICE

13244

- Moderate gallbladder sludge. The significance of the aggregated gallbladder debris is unclear. This could represent an early mucocele, cholestasis, or may be secondary to fasting.

DATE

12/30/21

INTERPRETATION OF THE FINDINGS & FURTHER RECOMMENDATIONS



PATIENT

Meeka Roksa

A large mixed echogenicity partially cavitated abdominal mass is visualized. A direct attachment to this mass effect is not observed. It lies in the area of the pancreas and is medial to the spleen. Based on the size and appearance, a splenic mass would be a primary concern, but pancreatic or even a very pedunculated hepatic mass is possible (or a solitary mass effect).

SPECIES

Canine

Options moving forward include a more definitive approach, which would include referral to a veterinary surgeon for exploration and removal. I recommend three-view thoracic radiographs.

BREED

Yorkie

A slightly more conservative approach would be a preoperative CT scan prior to removal to try and determine better it's origin and location.

SEX

Spayed Female

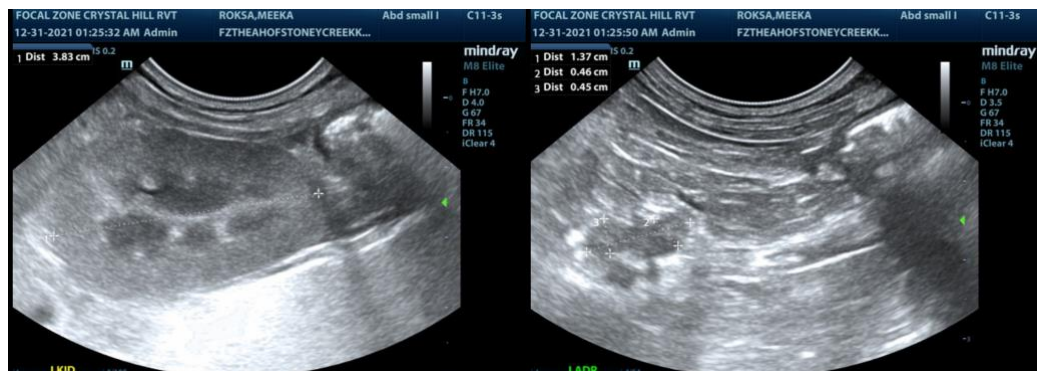
The most conservative approach would be a fine needle aspirate, but unfortunately, I think surgery would likely be necessary, unless this was lymphoma. Additionally, sampling of the free abdominal fluid may help aid in a diagnosis.

AGE

10 Years

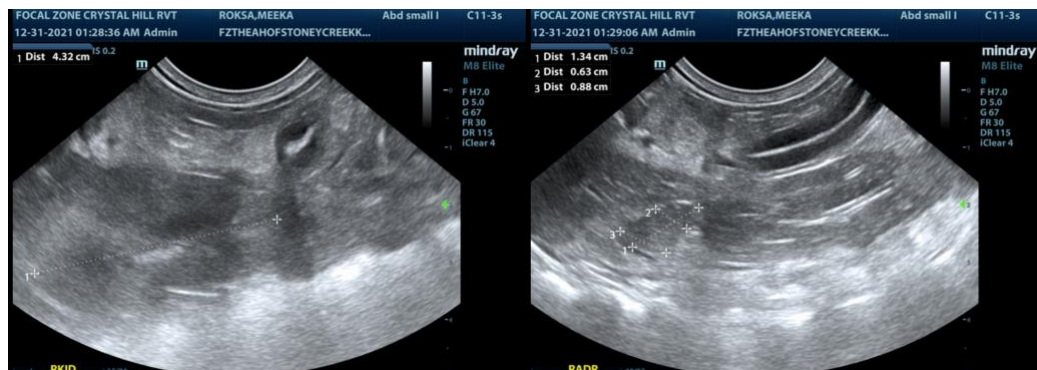
WEIGHT

9.8 Lbs.



INTERPRETED BY

Kathleen Sennello DVM,
MS, Diplomate ACVIM
(Small Animal Internal
Medicine)

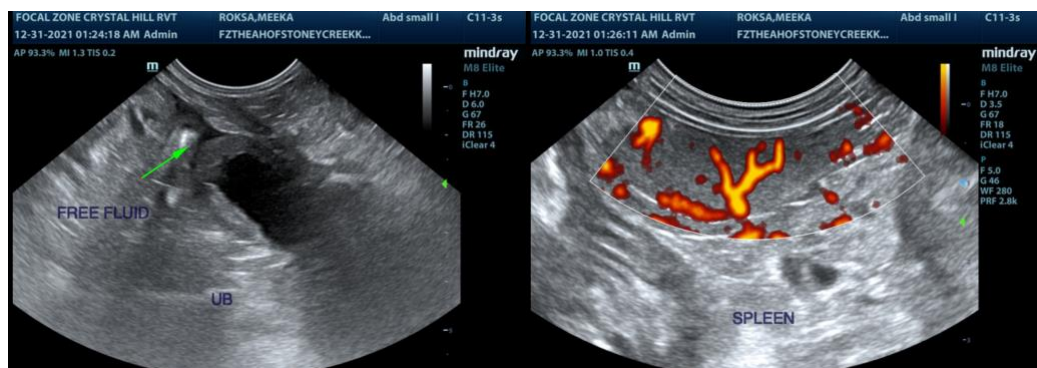


IMAGING PERFORMED BY

Crystal Hill

HOSPITAL NAME

AH of Stoney Creek



REFERRING VET

Dr. Ozimok

INVOICE

13244

DATE

12/30/21



PATIENT

Meeka Roksa

SPECIES

Canine

BREED

Yorkie

SEX

Spayed Female

AGE

10 Years

WEIGHT

9.8 Lbs.

INTERPRETED BY

Kathleen Sennello DVM,
MS, Diplomate ACVIM
(Small Animal Internal
Medicine)

**IMAGING
PERFORMED BY**

Crystal Hill

HOSPITAL NAME

AH of Stoney Creek

REFERRING VET

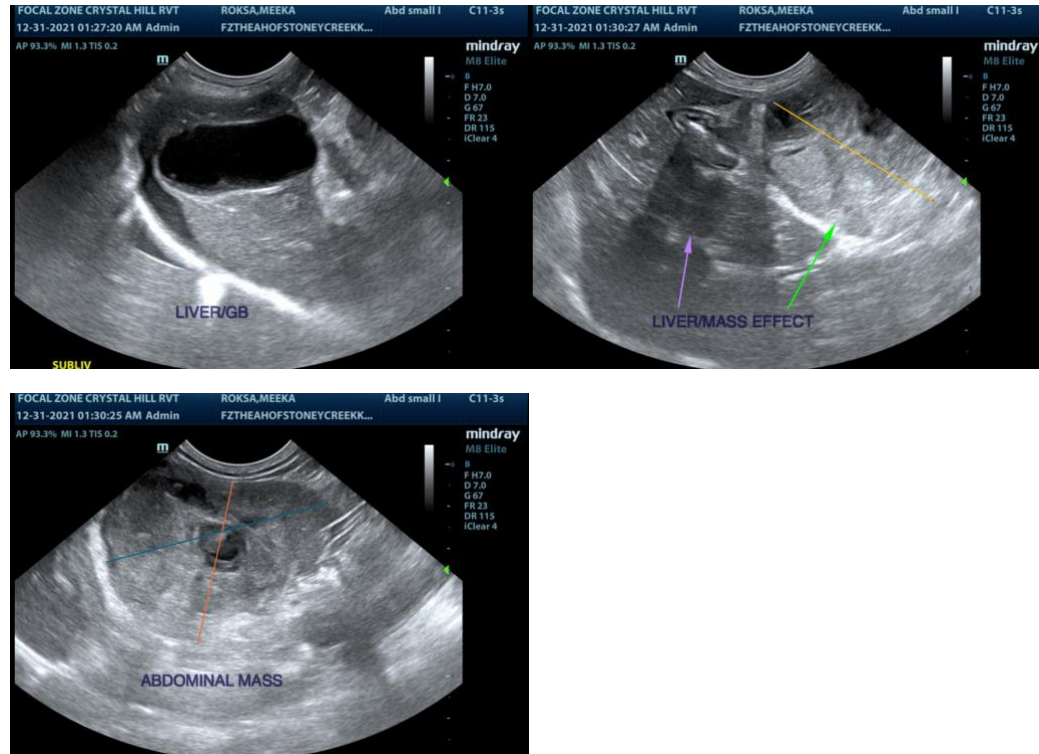
Dr. Ozimok

INVOICE

13244

DATE

12/30/21



The information and recommendations provided are based on the images presented by the referring veterinarian. No evaluation can be communicated regarding pathology that was not visible in the image/video clips provided.

Thank you for this referral. If the clinical or image interpretation does not parallel your findings or if I can be of any further assistance please contact me.

Kathleen Sennello DVM,MS, Diplomate ACVIM (Small animal Internal Medicine)
kathleen.sennello@sonopath.com