



PATIENT

Bella Gonzalez

SPECIES

Canine

BREED

Mini Dachshund

SEX

Spayed Female

AGE

11 Years

WEIGHT

10.7 lbs

INTERPRETED BY

Kathleen Sennello DVM,
MS, Diplomate ACVIM
(Small Animal Internal
Medicine)

IMAGING PERFORMED BY

Rebecca Hamilton

HOSPITAL NAME

Echo Hollow
Veterinary Hospital

REFERRING VET

Dr. Kenna

INVOICE

72289

DATE

12/3/25

PRESENTING CLINICAL SIGNS

Anemia, OA, malformed L front limb. Meds: Carprofen 25 mg chew tabs, Gabapentin liquid 50mg/ml
Abnormal PE/Chem/CBC/UA Results: 11/17/25: HCT 22.7 L, HGB 6.7 L, Mono 0.9 H, PLT 495 H- PLT clumps noted.

ULTRASONOGRAPHIC EXAMINATION OF THE ABDOMEN

Urinary System

The urinary bladder is moderately distended with anechoic urine. The Bladder wall, trigone, ureteral papillae and visible urethra (to a depth of 2cm) appear normal with no evidence of wall thickening, mucosal irregularities, masses or cystic calculi.

The left kidney has a normal shape and size (3.86 cm). Overall echogenicity is slightly hyperechoic with mildly reduced corticomedullary distinction and a typical 1:3 cortex:medulla ratio. There is no evidence of focal perinephric inflammation or effusion. There is no evidence of pyelectasia, nephroliths, infarcts or hydroureter. Renal vasculature is normal.

The right kidney has a normal shape and size (4.12 cm). Overall echogenicity is slightly hyperechoic with mildly reduced corticomedullary distinction and a typical 1:3 cortex:medulla ratio. There is no evidence of focal perinephric inflammation or effusion. There is no evidence of pyelectasia, nephroliths, infarcts or hydroureter. Renal vasculature is normal.

Adrenal Glands

The left adrenal gland is normal in size measuring 0.33 cm at the cranial pole and 0.52 cm at the caudal pole. It is observed in its normal position cranial to the left renal artery. It is normal in appearance (uniformly hypoechoic) and shape with no evidence of a mass effect.

The right adrenal gland is normal in size measuring 0.60 cm at the cranial pole and 0.33 cm at the caudal pole. It is observed in its normal position between the cranial aspect of the right kidney and the caudal vena cava. It is normal in appearance (uniformly hypoechoic) and shape with no evidence of a mass effect.

Spleen

The spleen is subjectively normal in size (1.47 cm), echotexture is homogenous, and the splenic capsule is smooth with no irregularities. The blood flow through the hilus and splenic parenchyma appears normal. No focal parenchymal abnormalities are visualized.

Liver

The liver is subjectively normal in size, and echogenicity with smooth peripheral margins. The parenchyma is homogenous echotexture. The visible portions of the vasculature and biliary tract appear normal. No focal nodules or cystic lesions are observed.

The gall bladder lumen is moderately distended. The wall of the gall bladder is not thickened and has a smooth mucosal surface. Luminal contents are mild and likely incidental at this time. The cystic and common bile ducts are normal/not visible.



PATIENT

Bella Gonzalez

SPECIES

Canine

BREED

Mini Dachshund

SEX

Spayed Female

AGE

11 Years

WEIGHT

10.7 lbs

INTERPRETED BY

Kathleen Sennello DVM,
MS, Diplomate ACVIM
(Small Animal Internal
Medicine)

IMAGING PERFORMED BY

Rebecca Hamilton

HOSPITAL NAME

Echo Hollow
Veterinary Hospital

REFERRING VET

Dr. Kenna

INVOICE

72289

DATE

12/3/25

Gastrointestinal

The stomach contains minimal luminal contents. It measures at a normal thickness of <0.7cm with some variability due to the presence of rugal folds. The distinction of the gastric wall layers is adequate and there is no impression of reduced peristaltic activity. No masses or focal lesions were observed.

The visualized areas of duodenum, jejunum and ileum have a relatively uniform diameter with minimal fluid distension. Wall thickness is normal. Bowel loops follow a curvilinear path with distinct wall layering maintaining the typical 1:3 muscularis:mucosa layer ratio. Duodenum wall measures 0.32 cm. Jejunum wall measures 0.26 cm. Visualized peristalsis appears appropriate. There were no focal lesions consistent with obstruction or a mass effect observed.

Sections of colon are visualized with formed fecal material and gas shadowing distally. There is no observed focal or generalized colon wall thickening or loss of layering.

Pancreas

The area of the pancreas is normal and isoechoic to surrounding mesentery. There is no evidence of nodules or cystic lesions. There is no evidence of regional mesenteric inflammation or fluid.

Free Abdomen

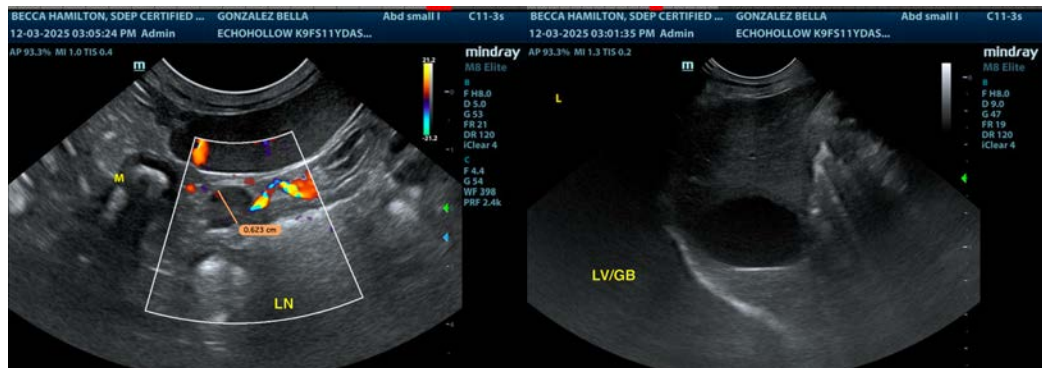
Evaluation of the peritoneal cavity did not reveal any evidence of effusion. There is no evidence of a diffuse lymphadenopathy. A prominent rounded lymph node is visualized medial to the spleen measuring 0.62 cm. The omentum is of normal echogenicity.

ULTRASONOGRAPHIC FINDINGS

- Prominent lymph node medial to the spleen – The significance of this is uncertain. This could represent a reactive lymph node, less likely an early metastatic lymph node.

INTERPRETATION OF THE FINDINGS & FURTHER RECOMMENDATIONS

Today's scan is relatively normal. There is a prominent lymph node medial to the spleen. I suspect this is in a challenging area to sample, but continued monitoring is warranted. Further evaluation could include a pathologist review of a blood smear and reticulocyte count to determine if this is regenerative anemia and to try to differentiate classes of anemia (blood loss, lack of production, increased destruction, etc.).





PATIENT

Bella Gonzalez

SPECIES

Canine

BREED

Mini Dachshund

SEX

Spayed Female

AGE

11 Years

WEIGHT

10.7 lbs

INTERPRETED BY

Kathleen Sennello DVM,
 MS, Diplomate ACVIM
 (Small Animal Internal
 Medicine)

**IMAGING
 PERFORMED BY**

Rebecca Hamilton

HOSPITAL NAME

Echo Hollow
 Veterinary Hospital

REFERRING VET

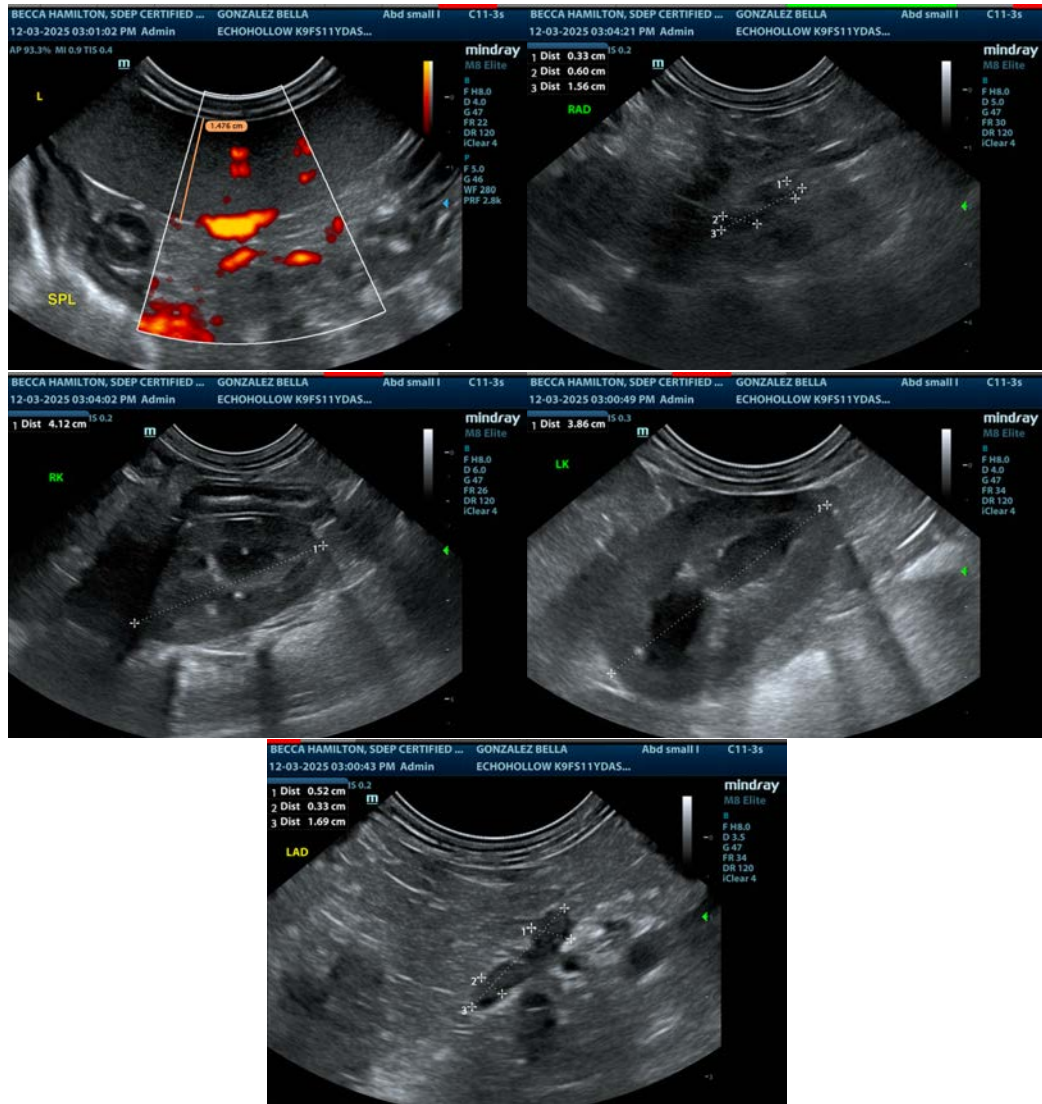
Dr. Kenna

INVOICE

72289

DATE

12/3/25



The information and recommendations provided are based on the images presented by the referring veterinarian/sonographer. No evaluation can be communicated regarding pathology that was not visible in the image/video clips provided.

Thank you for this referral. If the clinical or image interpretation does not parallel your findings or if I can be of any further assistance please contact me.

Kathleen Sennello DVM,MS, Diplomate ACVIM (Small animal Internal Medicine)

info@sonopath.com