



DATE PRESENTING CLINICAL SIGNS

12/3/25 **Patient History:** Acute onset of vomiting multiple bouts 12/2/25 followed by generalize shaking and abdominal pain. Hx newly diagnosed suspected AGASACA based on FNA. Hx ALP elevations, hypertriglyceridemia, Cushings. Cystotomy for urolith 2014. Now on low fat c/d diet.

PATIENT

Appa Schwertz

Current Medications: Chronic administration of vetoryl, ursodiol, denemarin, welactin, and a probiotic In hospital (started 12/2/25 PM) cerenia, panoquell, methadone, gabapentin, IVF.

SPECIES

Canine

Labwork Results: Labwork not attached, reported as: cPL 925, ALP 1924.

Date of Previous IntraPet Ultrasound: No previous.

Sedation: Not required to complete full diagnostic ultrasound.

Stat Report: DVM requested.

BREED

Schnauzer x

Imaging Performed by: Andi Parkinson, BS, RDMS.

ULTRASONOGRAPHIC EXAMINATION OF THE ABDOMEN

SEX

Neutered Male

Urinary System

The urinary bladder is moderately distended with anechoic urine. The Bladder wall, trigone, ureteral papillae and visible urethra (to a depth of 2cm) appear normal with no evidence of wall thickening, mucosal irregularities, masses or cystic calculi.

AGE

8/26/11

The prostate is normal in size (1.27 cm) and shape for this neutered male dog. There is a hyperechoic foci visualized in the mid region of the prostate, possibly consistent with a focal mineralization or small urethral stone.

WEIGHT

9.15 kg

The left kidney has a normal shape and size (4.72 cm). Overall echogenicity is normal with adequate corticomedullary distinction and a typical 1:3 cortex:medulla ratio. There is no evidence of focal perinephric inflammation or effusion. There is no evidence of pyelectasia, nephroliths, infarcts or hydroureter. Renal vasculature is normal.

INTERPRETED BY

Kathleen Sennello DVM,
MS, Diplomate ACVIM
(Small Animal Internal
Medicine)

The right kidney has a normal shape and size (5.67 cm) with pinpoint cortical mineralizations. Overall echogenicity is normal with adequate corticomedullary distinction and a typical 1:3 cortex:medulla ratio. There is no evidence of focal perinephric inflammation or effusion. There is no evidence of pyelectasia, nephroliths, infarcts or hydroureter. Renal vasculature is normal.

HOSPITAL NAME

Eastern Animal
Hospital

Adrenal Glands

The left adrenal gland is normal in size measuring 0.54 cm at the cranial pole and 0.48 cm at the caudal pole. It is observed in its normal position cranial to the left renal artery. It is normal in appearance (uniformly hypoechoic) and shape with no evidence of a mass effect.

REFERRING VET

Dr. Michelotti

The right adrenal gland is normal in size measuring 0.53 cm at the cranial pole and 0.48 cm at the caudal pole. It is observed in its normal position between the cranial aspect of the right kidney and the caudal vena cava. It is normal in appearance (uniformly hypoechoic) and shape with no evidence of a mass effect.

INVOICE

72263

Spleen

The spleen is subjectively normal in size (2.29 cm), echotexture is homogenous, and the splenic capsule is smooth with no irregularities. The blood flow through the hilus and splenic parenchyma appears normal. No focal parenchymal abnormalities are visualized.

Liver

The liver is large in size, and normal in echogenicity with smooth peripheral margins. The parenchyma is heterogenous in echotexture with subtle, indistinct focal mottling. The visible portions of the vasculature and biliary tract appear normal. No focal nodules or cystic lesions are observed.

The gall bladder lumen is moderately distended. The wall of the gall bladder is not thickened and has a smooth mucosal surface. There is a moderate amount of non-organized echogenic debris. The cystic and common bile ducts are normal/not visible.

Gastrointestinal

The stomach contains a large amount of fluid. It measures at a normal thickness of <0.7cm with some variability due to the presence of rugal folds. The distinction of the gastric wall layers is adequate and there is no impression of reduced peristaltic activity. The pylorus appears somewhat prominent measuring at 0.48 cm with intact wall layering.

The visualized areas of duodenum, jejunum and ileum have a relatively uniform diameter with minimal fluid distension. Wall thickness is normal. Bowel loops follow a curvilinear path with distinct wall layering maintaining the typical 1:3 muscularis:mucosa layer ratio. Duodenum wall measures 0.43 cm. Jejunum wall measures 0.26 cm. Visualized peristalsis appears appropriate. There were no focal lesions consistent with obstruction or a mass effect observed.

Sections of colon are visualized with formed fecal material and gas shadowing distally. There is no observed focal or generalized colon wall thickening or loss of layering.

Pancreas

The pancreas is large and hypoechoic to surrounding mesentery. There are numerous poorly defined hypoechoic lesions within the parenchyma consistent with small nodules. In the caudal aspect of the left limb of the pancreas there is a poorly defined hypoechoic/mixed echogenicity lesion concerning for a larger nodule or even an early cystic lesion/abscess measuring 1.78 cm x 1.83 cm. There is evidence of regional mesenteric inflammation. Consistent with moderate/severe pancreatitis.

Free Abdomen

There is a small to moderate amount of free abdominal fluid. No significant lymphadenopathy noted. The omentum is diffusely hyperechoic, particularly around both limbs of the pancreas.

ULTRASONOGRAPHIC FINDINGS

- Hyperechoic foci in the prostate – Findings could be consistent with a small parenchymal mineralization or a small stone.
- Severely enlarged, hypoechoic, irregular edematous pancreas with surrounding reactive mesentery and poorly defined hypoechoic lesions/nodules, and a larger mixed echogenicity nodule at the caudal aspect of the left limb – Findings are most consistent with moderate to severe pancreatitis. The mixed echogenicity nodule could represent a benign or neoplastic mass or an early abscess. Recommend continued monitoring.
- Large, heterogeneous liver – Findings are most consistent with a vacuolar hepatopathy. Other hepatopathies are possible.

- Moderate gallbladder debris – The significance of the aggregated gallbladder debris is unclear. This could represent an early mucocele, cholestasis, or may be secondary to fasting but seems unlikely to be causing a current issue. Recommend continued monitoring.
- Fluid distended stomach – Findings are suggestive of gastric ileus. The pylorus is somewhat thickened, likely secondary to inflammation. An obstruction is less likely.
- Small volume free abdominal fluid – Findings are most consistent with sterile peritonitis.

INTERPRETATION OF THE FINDINGS & FURTHER RECOMMENDATIONS

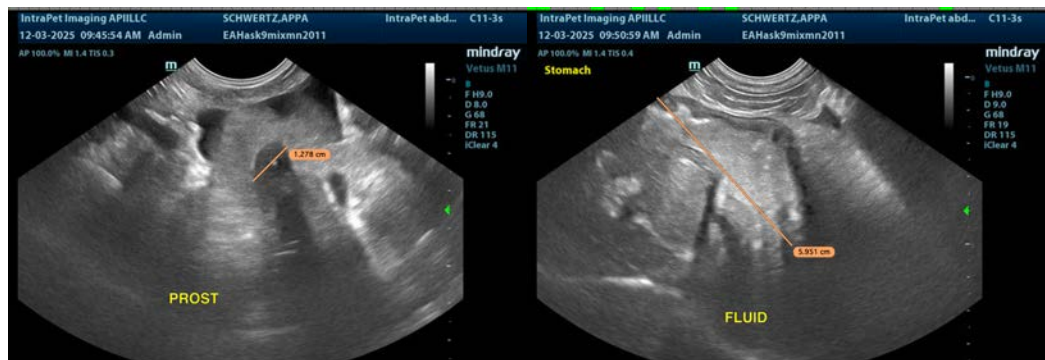
Both limbs of the pancreas are severely inflamed, appearing hypoechoic and irregular and edematous with surrounding reactive mesentery. The left limb of the pancreas appears to have poorly defined nodules and a more discrete lesion towards the caudal aspect. Recommend aggressive treatment for pancreatitis and consider following the appearance of the pancreas over time to better evaluate, as a fine needle aspirate of the caudal aspect of the left limb may be warranted.

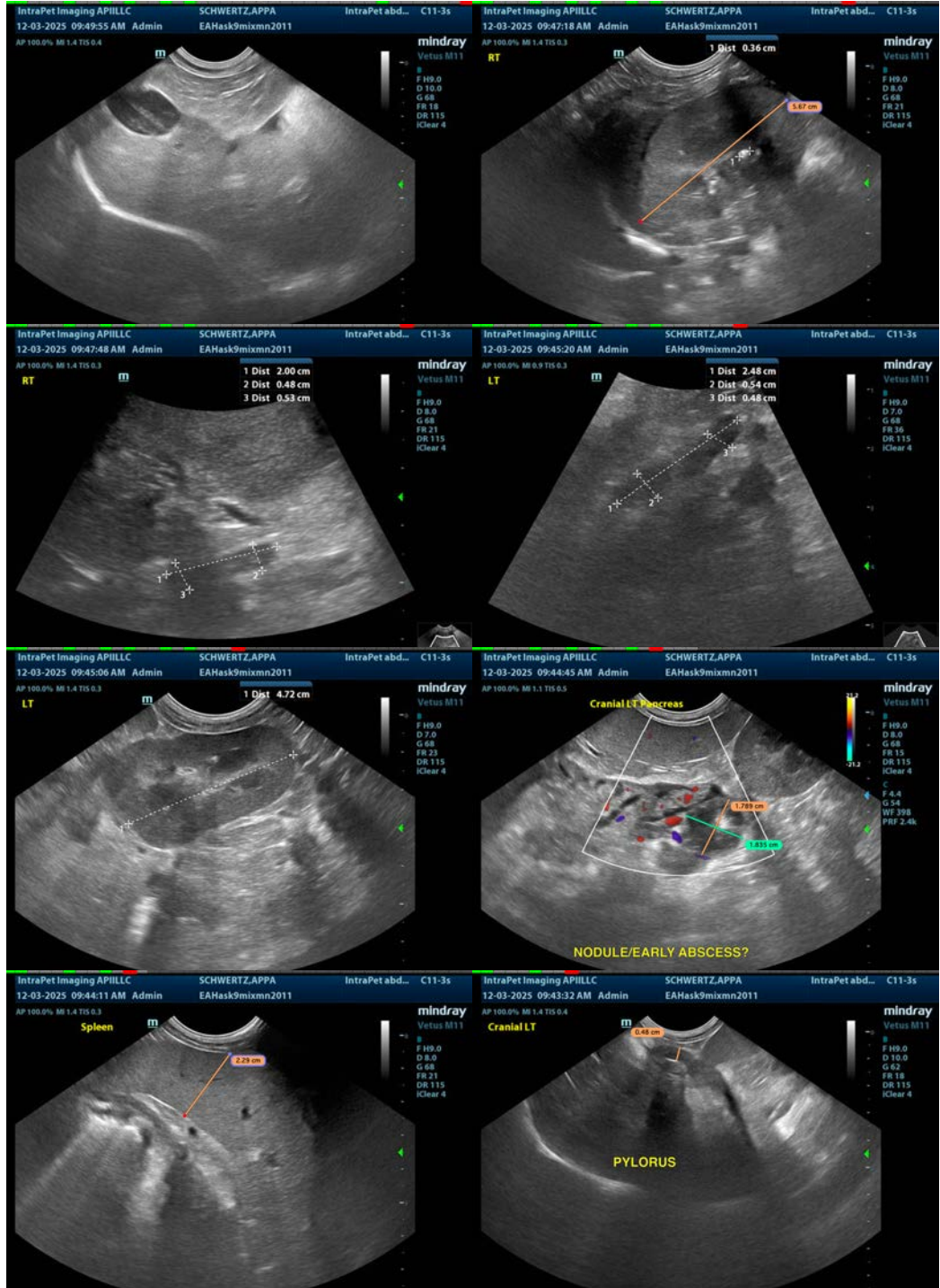
The stomach is significantly fluid distended, likely due to secondary ileus. Consider prokinetic therapy. If it is persistently distended, consider passing a nasogastric tube to decompress.

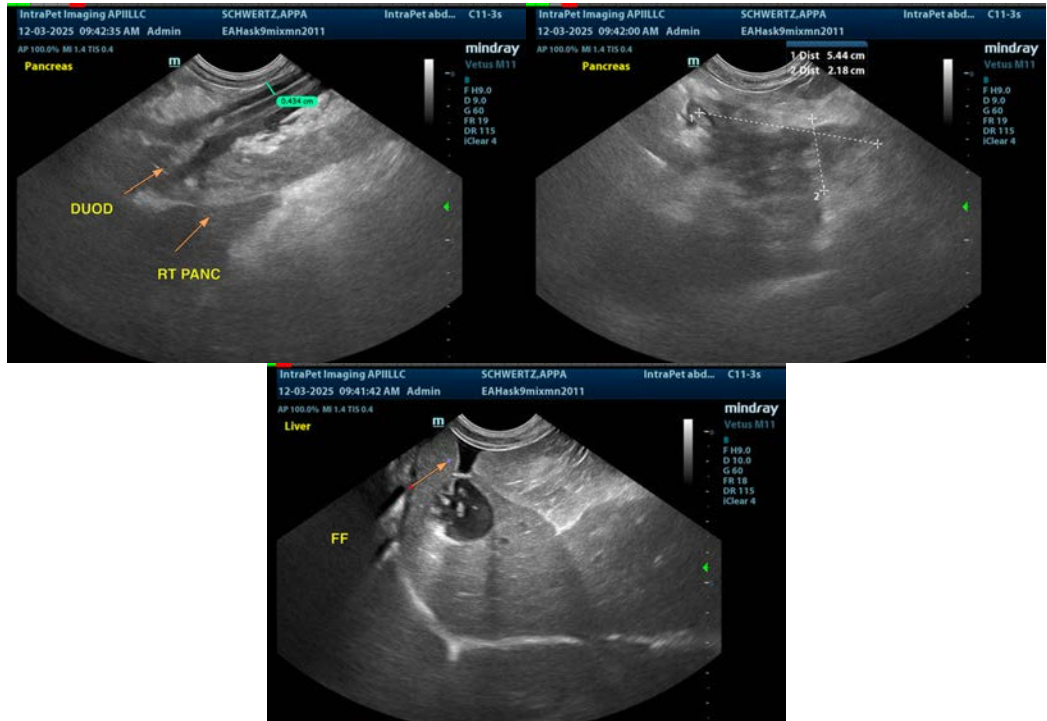
If the patient's triglyceride levels are still significantly elevated on an ultra low-fat prescription diet, then medical management may be warranted.

It is difficult to clearly visualize the prostate. There appears to be a small pinpoint mineralization possibly consistent with parenchymal mineralization or a small stone in the urethra. Correlate with urinalysis findings and consider reevaluation of the prostate when the pancreas is evaluated, particularly if the patient is more comfortable.

Evaluation of some areas of the cranial abdomen is challenging due to patient discomfort and inflammation obscuring the deeper regions. Consider recheck evaluation if there is concern for metastatic lesions from the anal gland carcinoma.







The information and recommendations provided are based on the images presented by the referring veterinarian/sonographer. No evaluation can be communicated regarding pathology that was not visible in the image/video clips provided.

Thank you for this referral. If the clinical or image interpretation does not parallel your findings or if I can be of any further assistance please contact me.

Kathleen Sennello DVM,MS, Diplomate ACVIM (Small animal Internal Medicine)
info@sonopath.com