

**DATE PRESENTING CLINICAL SIGNS**

12/3/21 History: chronic intermittent bloody diarrhea - will temporarily resolve with metronidazole but then recurs, maintains a good appetite, no vomiting; I/VI heart murmur noted.

PATIENT

Bella Garnet Current Medications: Provable, started 11/12/21.
Lab Results: GHP1 - CBC - wnl; Chem - mildly elevated BUN (28), crea wnl (1.4) - given changes on rad, advised o do suspect p has some early degenerative changes to kidneys, likely age related; chol mildly dec (88), otherwise wnl.

SPECIES

Canine

Radiographs: two view abd rads - granular likely food material in stomach. gas filled structure mid R abd, most likely consistent with cecum. small intestines appear largely uniform in diameter, however reviewed with o that intestinal wall appears subjectively thickened and delineation between the wall and the lumen is more pronounced than would typically expect. Mineralization associated with kidneys.

BREED

Chihuahua

Date of Previous IntraPet Ultrasound: No previous IntraPet scans.

Sedation: 0.08 mL butorphanol IV, different sedation required if further imaging required.

SEX

Spayed Female

Stat Report: Not requested.

ULTRASONOGRAPHIC EXAMINATION OF THE ABDOMEN**AGE**

8/24/09

Urinary System

The urinary bladder is moderately distended with anechoic urine. The Bladder wall, trigone, ureteral papillae and visible urethra (to a depth of 2cm) appear normal with no evidence of wall thickening, mucosal irregularities, masses or cystic calculi.

WEIGHT

5.5 Pounds

The left kidney has a normal shape and size (2.92 cm). Overall echogenicity is slightly hyperechoic with poor corticomedullary distinction and a typical 1:3 cortex:medulla ratio. There is no evidence of perinephric inflammation or effusion. There is no evidence of pyelectasia, nephroliths, infarcts or hydroureter. Renal vasculature is normal.

INTERPRETED BY

Kathleen Sennello DVM,
MS, Diplomate ACVIM
(Small Animal Internal
Medicine)

The right kidney has a normal shape and size (2.57 cm). Overall echogenicity is slightly hyperechoic with poor corticomedullary distinction and a typical 1:3 cortex:medulla ratio. There is no evidence of perinephric inflammation or effusion. There is no evidence of pyelectasia, nephroliths, infarcts or hydroureter. Renal vasculature is normal.

IMAGING PERFORMED BY

Rachel Brillhart RDMS

Adrenal Glands

The left adrenal gland is normal in size measuring 0.30 cm at the caudal pole. It is observed in its normal position cranial to the left renal artery. It is normal in appearance (uniformly hypoechoic) and shape with no evidence of a mass effect.

HOSPITAL NAME

Churchville Vet Clinic

The right adrenal gland is normal in size measuring 0.47 cm at the caudal pole. It is observed in its normal position between the cranial aspect of the right kidney and the caudal vena cava. It is normal in appearance (uniformly hypoechoic) and shape with no evidence of a mass effect.

REFERRING VET

Dr. Uhland

Spleen

The spleen is subjectively normal in size, echotexture is homogenous, and the splenic capsule is smooth with no irregularities. The blood flow through the hilus and splenic parenchyma appears normal. No focal parenchymal abnormalities are visualized.

INVOICE

33232

Liver

The liver is subjectively normal in size, and echogenicity with smooth peripheral margins. The parenchyma is homogenous echotexture. The visible portions of the vasculature and biliary tract appear normal. No focal nodules or cystic lesions are observed.

The gallbladder lumen is moderately distended. The wall of the gall bladder is not thickened and has a smooth mucosal surface. Luminal contents are primarily anechoic. The cystic and common bile ducts are normal/not visible.

Gastrointestinal

The stomach contains minimal luminal contents. It measures at a normal thickness of <0.7cm with some variability due to the presence of rugal folds. The distinction of the gastric wall layers is adequate and there is no impression of reduced peristaltic activity. No masses or focal lesions were observed.

The visualized areas of duodenum, jejunum and ileum have a uniform diameter with minimal fluid distension. Wall appears subjectively, mildly increased. Bowel loops follow a typical curvilinear path with distinct wall layering and mild mucosal speckling. Jejunum wall measured 0.35 cm. Visualized peristalsis appears appropriate. There were no focal lesions consistent with obstruction or a mass effect observed.

The ileocecal junction was visualized and exhibited normal intact wall layering and is subjectively of normal thickness. Sections of colon are visualized with formed fecal material and gas shadowing distally. There is no observed focal or generalized colon wall thickening or loss of layering.

Pancreas

The pancreas is normal and isoechoic to surrounding mesentery. There is no evidence of nodules or cystic lesions. There is no evidence of regional mesenteric inflammation or fluid.

Free Abdomen

Evaluation of the peritoneal cavity did not reveal any evidence of effusion, or subjective lymphadenomegaly. The Medial iliac nodes appear normal and there was no evidence of a caudal aortic thrombus at the bifurcation. The omentum is of normal uniform echogenicity.

Other

Ringdown artifact is visualized at the level of the diaphragm, which can be seen with parenchymal disease. Recommend 3-view thoracic radiographs.

ULTRASONOGRAPHIC FINDINGS

- Decreased corticomedullary distinction both kidneys – Mild loss of corticomedullary distinction in both kidneys could be consistent with chronic degenerative disease or interstitial nephrosis.
- Mild small intestinal wall thickening with mucosal speckling – The mild small intestinal wall changes may be a normal variant in this patient or could be consistent with an inflammatory process (e.g., inflammatory bowel disease). Bright mucosal speckling has been proposed to represent dilated lacteals or focal accumulation of mucus, cellular debris etc.. in the mucosal crypts of the small intestine.

INTERPRETATION OF THE FINDINGS & FURTHER RECOMMENDATIONS

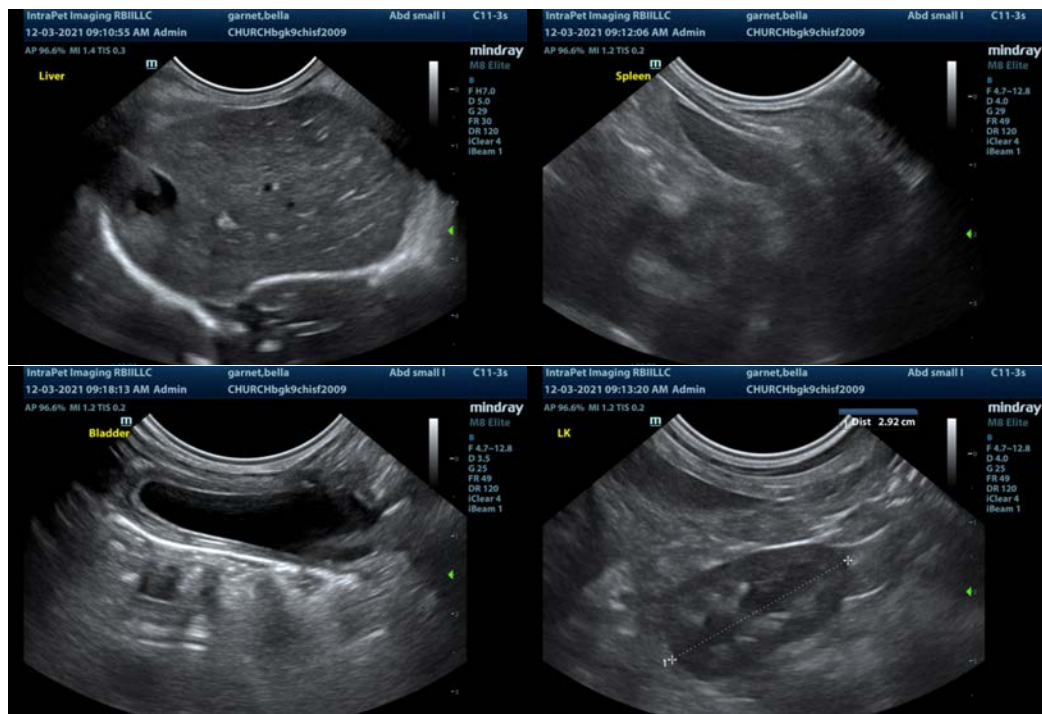
The changes observed on today's scan were relatively mild. The renal changes are likely progressive and age related. Consider a blood pressure evaluation, urinalysis and culture. If the urine is isosthenuric, you could consider starting a renal diet.

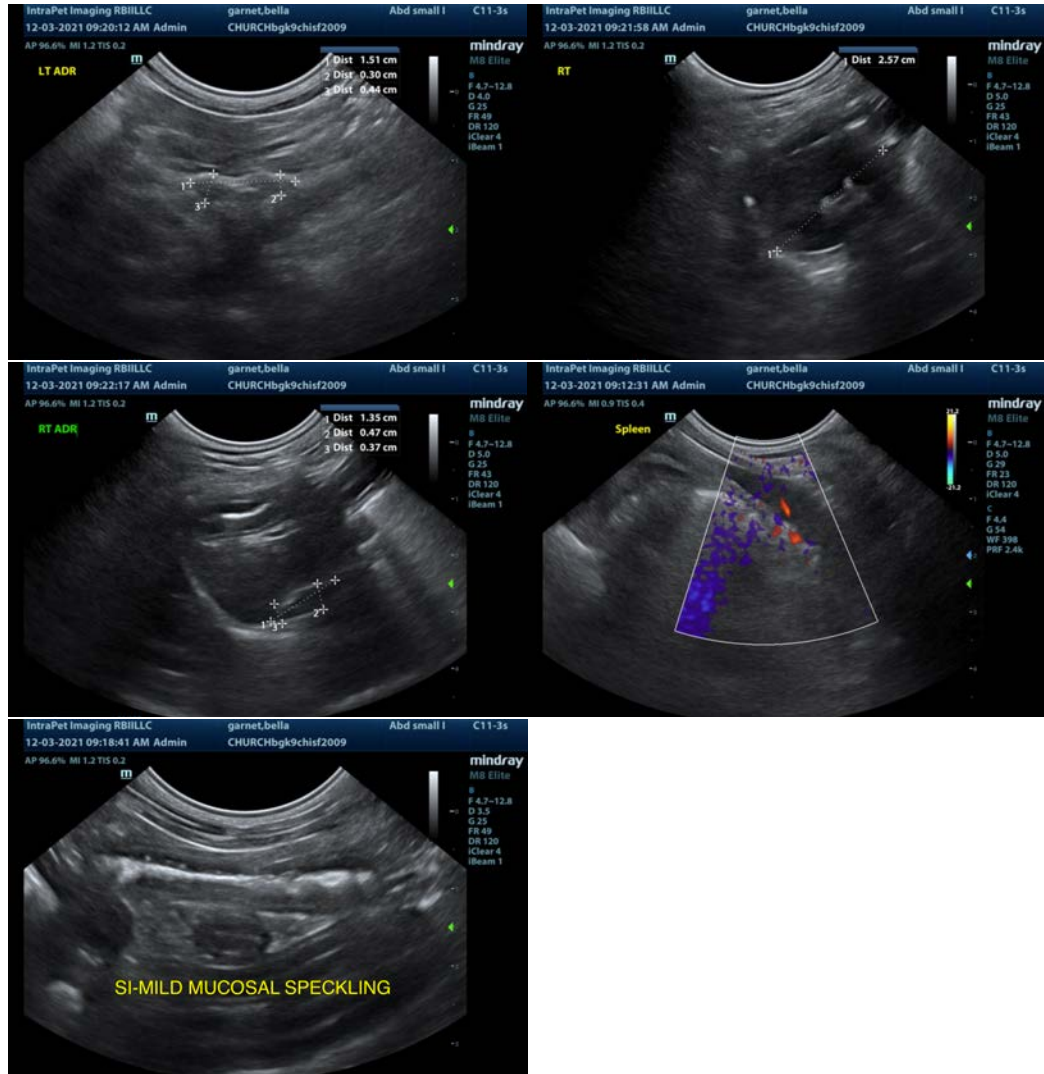
Additionally, there is very mild subjective small intestinal wall thickening. Unfortunately, the severity of ultrasonographic changes does not always correlate with the severity of GI symptoms exhibited, and many causes for GI signs cannot be definitively diagnosed by ultrasound alone.

- Consider metabolic causes based on bloodwork, ACTH stim results, Liver function testing, Gi panel (TLI/PLI, folate, cobolamine.)
- Consider primary GI causes: Gi parasitism, dietary indiscretion, mild pancreatitis, bacterial dysbiosis, food allergy, IBD and less likely intestinal neoplasia.

With chronic intermittent symptoms, I am more concerned about the possibility of food allergy, IBD, stress colitis, etc.

- Recommend a diet trial with a novel protein/hydrolyzed protein prescription diet. This is in contrast to a renal diet as previously mentioned. Options would be consultation with a nutritionist to get a diet that fulfills both criteria and is both low protein and has a hydrolyzed or novel protein source, or to prioritize one of the other.
- Recommend starting probiotic therapy (I believe this has already been done).
- Try to correlate episodes with any external factors such as diet change, stress, etc.
- If symptoms seem to be progressing, then consider obtaining GI biopsies.





The information and recommendations provided are based on the images presented by the referring veterinarian. No evaluation can be communicated regarding pathology that was not visible in the image/video clips provided.

Thank you for this referral. If the clinical or image interpretation does not parallel your findings or if I can be of any further assistance please contact me.

Kathleen Sennello DVM,MS, Diplomate ACVIM (Small animal Internal Medicine)
 kathleen.sennello@sonopath.com