

IMAGING PERFORMED BY

IntraPet.com



SonoPath

Clinical Sonography & Telectology

EDUCATIONAL TELECONSULTATION SERVICES™

1-800-838-4268 info@sonopath.com SonoPath.com

DATE PRESENTING CLINICAL SIGNS

12/29/21 History: weight loss; decreased appetite; discomfort mid abdominal palpation. Owner requested u/s especially due to other cat's history and pathology.

PATIENT

Pete Wilson

Lab Results: Attached separately.
Date of Previous IntraPet Ultrasound: No previous IntraPet scans.
Sedation: Gabapentin.
Stat Report: Not requested.

SPECIES

Feline

ULTRASONOGRAPHIC EXAMINATION OF THE ABDOMEN

BREED

DMH

Urinary System

The urinary bladder is moderately distended with anechoic urine. The Bladder wall, trigone, ureteral papillae and visible urethra (to a depth of 2cm) appear normal with no evidence of wall thickening, mucosal irregularities, masses or cystic calculi.

SEX

Neutered Male

The left kidney has a normal shape and size (4.01 cm). Overall echogenicity is normal with adequate corticomedullary distinction and a typical 1:3 cortex:medulla ratio. There is no evidence of perinephric inflammation or effusion. There is no evidence of pyelectasia, nephroliths, infarcts or hydroureter. Renal vasculature is normal.

AGE

4/9/15

The right kidney has a normal shape and size (3.96 cm). Overall echogenicity is normal with adequate corticomedullary distinction and a typical 1:3 cortex:medulla ratio. There is no evidence of perinephric inflammation or effusion. There is no evidence of pyelectasia, nephroliths, infarcts or hydroureter. Renal vasculature is normal.

WEIGHT

15.34 Pounds

Adrenal Glands

The left adrenal gland is normal in size measuring 0.40 cm at the caudal pole. It is observed in its normal position cranial to the left renal artery. It is normal in appearance (uniformly hypoechoic) and shape with no evidence of a mass effect.

INTERPRETED BY

Kathleen Sennello DVM,
MS, Diplomate ACVIM
(Small Animal Internal
Medicine)

The right adrenal gland is normal in size measuring 0.37 cm at the caudal pole. It is observed in its normal position between the cranial aspect of the right kidney and the caudal vena cava. It is normal in appearance (uniformly hypoechoic) and shape with no evidence of a mass effect.

IMAGING PERFORMED BY

Rachel Brillhart RDMS

Spleen

The spleen is subjectively normal in size, echotexture is homogenous, and the splenic capsule is smooth with no irregularities. The blood flow through the hilus and splenic parenchyma appears normal. No focal parenchymal abnormalities are visualized.

HOSPITAL NAME

Frederick Road VH

Liver

The liver is subjectively normal in size, and echogenicity with smooth peripheral margins. The parenchyma is homogenous echotexture. The visible portions of the vasculature and biliary tract appear normal. No focal nodules or cystic lesions are observed.

REFERRING VET

Dr. Beyer

The gallbladder lumen is moderately distended. The wall of the gall bladder is not thickened and has a smooth mucosal surface. Luminal contents are primarily anechoic. The cystic and common bile ducts are normal/not visible.

INVOICE

33825

Gastrointestinal

The stomach contains minimal luminal contents. It measures at a normal thickness of <0.36cm with some variability due to the presence of rugal folds. The distinction of the gastric wall layers is adequate and there is no impression of reduced peristaltic activity. No masses or focal lesions were observed.

The visualized areas of duodenum, jejunum and ileum have a relatively uniform diameter with minimal fluid distension. Wall thickness is normal. Bowel loops follow a curvilinear path with distinct wall layering maintaining the typical 1:3 muscularis:mucosa layer ratio. Jejunum wall measured 0.27 cm. Visualized peristalsis appears appropriate. There were no focal lesions consistent with obstruction or a mass effect observed.

The ileocecal junction was visualized and exhibited normal intact wall layering and is subjectively of normal thickness. Sections of colon are visualized with formed fecal material and gas shadowing distally. There is no observed focal or generalized colon wall thickening or loss of layering.

Pancreas

The pancreas is prominent and hypoechoic as compared to the surrounding isoechoic mesentery. There is no evidence of nodules or cystic lesions. There is no evidence of regional mesenteric inflammation or fluid.

Free Abdomen

Evaluation of the peritoneal cavity did not reveal any evidence of effusion. There are occasional prominent mesenteric lymph nodes visualized measuring 0.36, 0.37, and 0.40 cm. The omentum is generally of normal echogenicity.

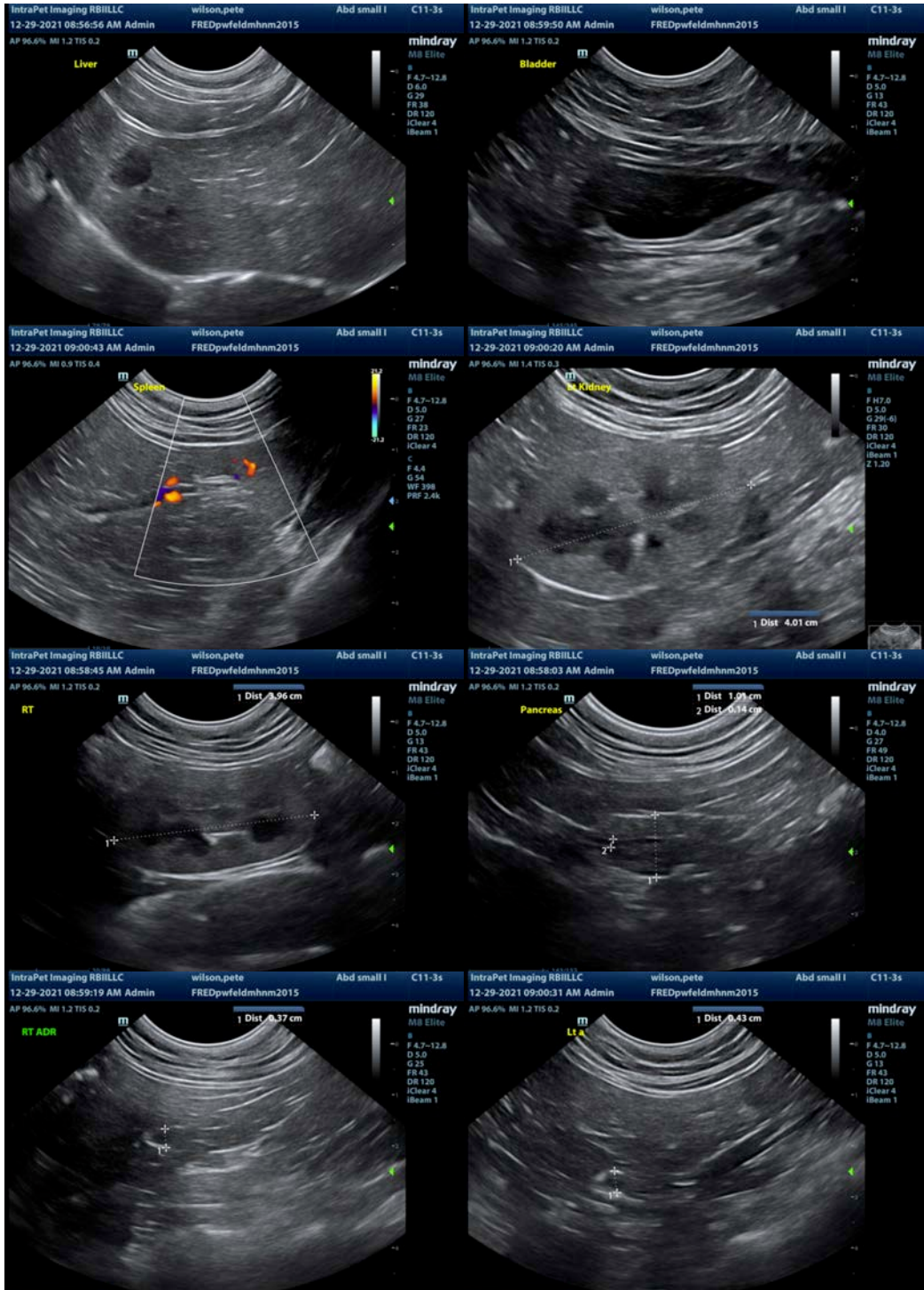
ULTRASONOGRAPHIC FINDINGS

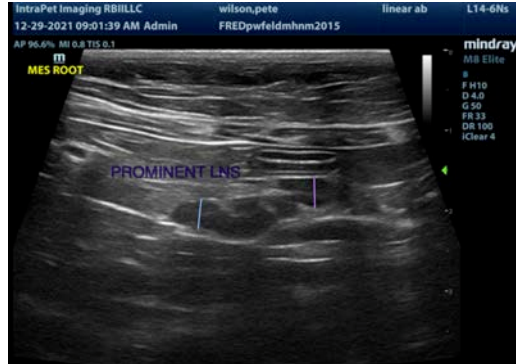
- Prominent, hypoechoic pancreas – The pancreatic changes are most consistent with age-related parenchymal remodeling, potentially secondary to a prior inflammatory episode, early fibrosis or chronic pancreatitis.
- Prominent mesenteric lymph nodes – The prominent abdominal lymph nodes are most consistent with reactive lymphadenitis or lymphoid hyperplasia. Neoplastic infiltration is considered less likely.

INTERPRETATION OF THE FINDINGS & FURTHER RECOMMENDATIONS

The changes observed on today's scan were subjective and mild, but ultrasonographic findings do not always correlate with the clinical signs, particularly with GI disease.

- Consider a GI panel to Texas A&M for a qualitative PLI, TLI, cobalamin and folate to further evaluate the pancreas and small intestine.
- If not already done, recommend full lab work including thyroid evaluation.
- Consider a novel protein or hydrolyzed protein diet if underlying GI disease is suspected.
- Recommend symptomatic treatment for pancreatitis/enteritis.
- Recommend 3-view thoracic/whole body radiographs to look for evidence of concurrent thoracic disease.
- If symptoms persist, consider reevaluation and obtaining GI biopsies.





The information and recommendations provided are based on the images presented by the referring veterinarian. No evaluation can be communicated regarding pathology that was not visible in the image/video clips provided.

Thank you for this referral. If the clinical or image interpretation does not parallel your findings or if I can be of any further assistance please contact me.

Kathleen Sennello DVM,MS, Diplomate ACVIM (Small animal Internal Medicine)
kathleen.sennello@sonopath.com