

**PATIENT**

Skye Ewles

PRESENTING CLINICAL SIGNS

No clinical signs. Presents for elevated liver enzymes

SPECIES

Canine

ULTRASONOGRAPHIC EXAMINATION OF THE ABDOMEN**Urinary System**

The urinary bladder is moderately distended with anechoic urine. The Bladder wall, trigone, ureteral papillae and visible urethra (to a depth of 2cm) appear normal with no evidence of wall thickening, mucosal irregularities, masses or cystic calculi.

BREED

Australian Cattle Dog

The left kidney has a normal shape and size (4.85 cm). Overall echogenicity is normal with adequate corticomedullary distinction and a typical 1:3 cortex:medulla ratio. There is no evidence of focal perinephric inflammation or effusion. There is no evidence of pyelectasia, nephroliths, infarcts or hydroureter. Renal vasculature is normal.

SEX

Spayed Female

The right kidney has a normal shape and size (5.25 cm). Overall echogenicity is normal with adequate corticomedullary distinction and a typical 1:3 cortex:medulla ratio. There is no evidence of focal perinephric inflammation or effusion. There is no evidence of pyelectasia, nephroliths, infarcts or hydroureter. Renal vasculature is normal.

AGE

5 Years

Adrenal Glands**WEIGHT**

31.5 Pounds

The left adrenal gland is normal in size measuring 0.65 cm at the caudal pole. It is observed in its normal position cranial to the left renal artery. It is normal in appearance (uniformly hypoechoic) and shape with no evidence of a mass effect.

INTERPRETED BYKathleen Sennello DVM,
MS, Diplomate ACVIM
(Small Animal Internal
Medicine)

The right adrenal gland is normal in size measuring 0.62 cm at the caudal pole. It is observed in its normal position between the cranial aspect of the right kidney and the caudal vena cava. It is normal in appearance (uniformly hypoechoic) and shape with no evidence of a mass effect.

IMAGING PERFORMED BY

Amy Mayhew, LVT

Spleen

The spleen is subjectively normal in size, echotexture is homogenous, and the splenic capsule is smooth with no irregularities. The blood flow through the hilus and splenic parenchyma appears normal. No focal parenchymal abnormalities are visualized.

HOSPITAL NAME

SVS Imaging MI

Liver

The liver is subjectively normal in size, and echogenicity with smooth peripheral margins. The parenchyma is homogenous echotexture. The visible portions of the vasculature and biliary tract appear normal. No focal nodules or cystic lesions are observed.

REFERRING VET

Briarwood VH

The gallbladder lumen is moderately distended. The wall of the gall bladder is not thickened and has a smooth mucosal surface. Luminal contents are mild and primarily anechoic. The cystic and common bile ducts are normal/not visible.

Gastrointestinal**INVOICE**

43789

The stomach contains moderate fluid/ingesta. It measures at a normal thickness of 0.30 cm with some variability due to the presence of rugal folds. The distinction of the gastric wall layers is adequate and there is no impression of reduced peristaltic activity. No masses or focal lesions were observed.

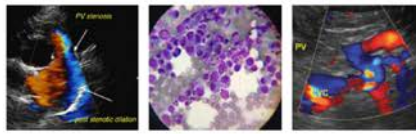
DATE

12/28/22

The visualized areas of duodenum, jejunum and ileum have a relatively uniform diameter with minimal fluid distension. Wall thickness is normal. Bowel loops follow a curvilinear path with distinct wall layering maintaining the typical 1:3 muscularis:mucosa layer ratio. Duodenum wall measures 0.50 cm.

IMAGING PERFORMED BY

SVS Mobile Imaging MI 734-637-7711
svsimagingmi@gmail.com

**PATIENT**

Skye Ewles

Jejunum wall measures 0.37 cm. Visualized peristalsis appears appropriate. There were no focal lesions consistent with obstruction or a mass effect observed.

SPECIES

Canine

The ileocecal junction was visualized and exhibited normal intact wall layering and is subjectively of normal thickness. Sections of colon are visualized with formed fecal material and gas shadowing distally. There is no observed focal or generalized colon wall thickening or loss of layering. Colonic wall measures 0.12 cm.

Pancreas**BREED**

Australian Cattle Dog

The pancreas is normal and isoechoic to surrounding mesentery. There is no evidence of nodules or cystic lesions. There is no evidence of regional mesenteric inflammation or fluid.

Free Abdomen**SEX**

Spayed Female

Evaluation of the peritoneal cavity did not reveal any evidence of effusion, or subjective lymphadenomegaly. The Medial iliac nodes appear normal and there was no evidence of a caudal aortic thrombus at the bifurcation. The omentum is of normal uniform echogenicity.

AGE

5 Years

ULTRASONOGRAPHIC FINDINGS

- No significant ultrasonographic lesions visualized

INTERPRETATION OF THE FINDINGS & FURTHER RECOMMENDATIONS**WEIGHT**

31.5 Pounds

No focal lesions are visualized associated with the liver to explain the elevation in liver enzymes reported. Unfortunately, there are many causes for elevations in liver enzymes that cannot be diagnosed by ultrasound alone. Consider the following:

INTERPRETED BY

Kathleen Sennello DVM,
MS, Diplomate ACVIM
(Small Animal Internal
Medicine)

- Consider close evaluation of history for possible toxic changes examine medications, diet, dietary indiscretion etc...
- Consider PCR on urine/serum for leptospirosis (if not on antibiotics)/serology if recent antibiotic history
- If not already done, consider pre and post prandial bile acids to evaluate liver function
- If the ALP is significantly elevated relative to the ALT and symptoms consistent with Cushing's are present, consider adrenal function testing (ACTH stim)
- Consider Fine needle aspirate if round cell neoplasia is on your differentia list (25 g needle, normal coags)
- If no response to supportive care (Denamarin, fluids, antibiotics, +/- ursodiol etc.) Consider liver biopsy with samples obtained for histopathology, culture, and copper levels.

IMAGING PERFORMED BY

Amy Mayhew, LVT

HOSPITAL NAME

SVS Imaging MI

REFERRING VET

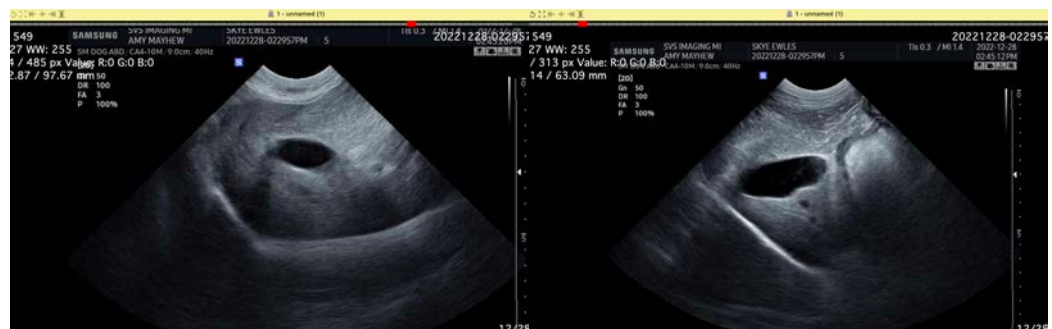Briarwood VH

INVOICE

43789

DATE

12/28/22



IMAGING PERFORMED BY

SVS Mobile Imaging MI 734-637-7711
svsimagingmi@gmail.com



PATIENT

Skye Ewles

SPECIES

Canine

BREED

Australian Cattle Dog

SEX

Spayed Female

AGE

5 Years

WEIGHT

31.5 Pounds

INTERPRETED BY

Kathleen Sennello DVM,
MS, Diplomate ACVIM
(Small Animal Internal
Medicine)

**IMAGING
PERFORMED BY**

Amy Mayhew, LVT

HOSPITAL NAME

SVS Imaging MI

REFERRING VET

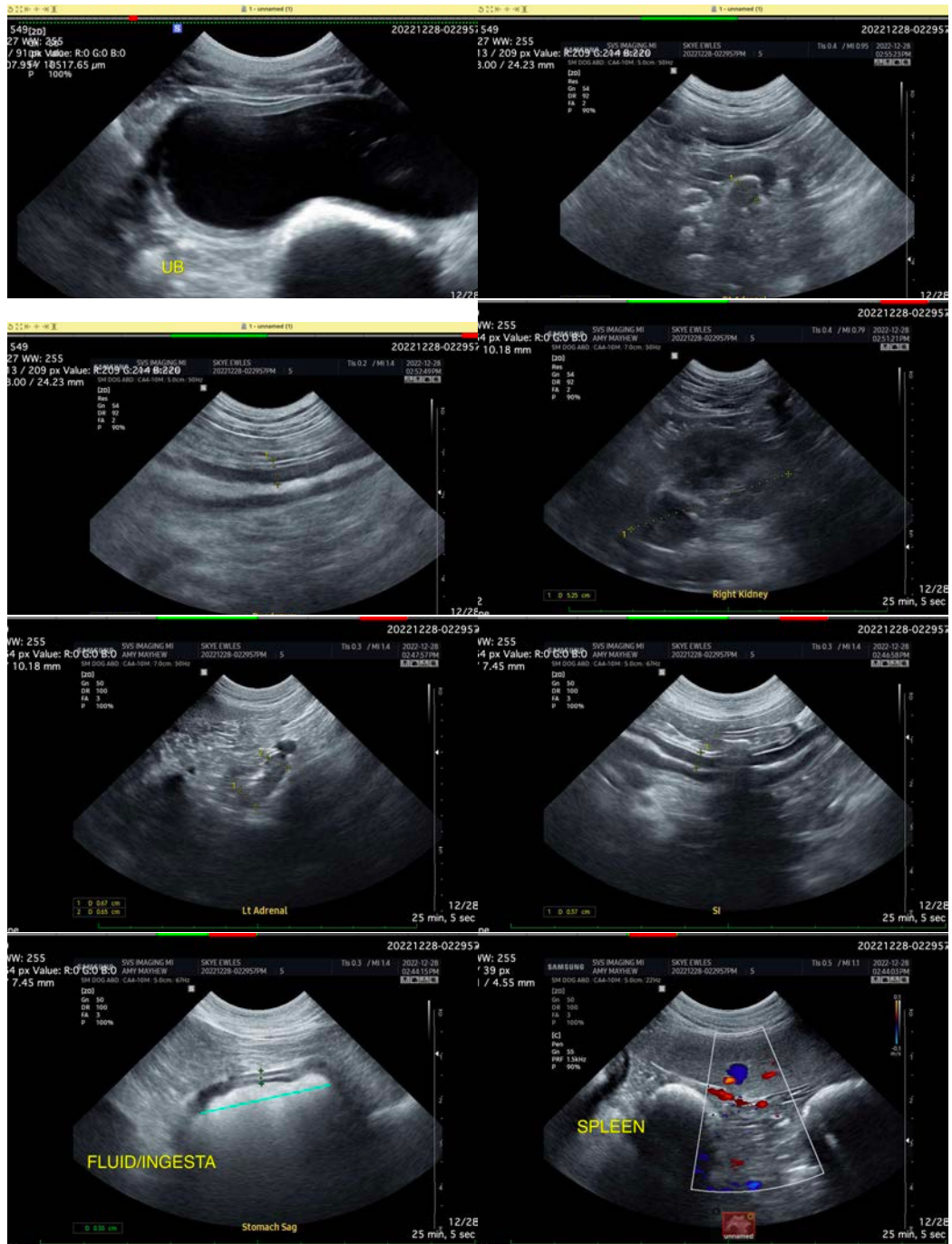
Briarwood VH

INVOICE

43789

DATE

12/28/22



IMAGING PERFORMED BY

SVS Mobile Imaging MI 734 - 637 - 7711
svsimagingmi@gmail.com



EDUCATIONAL TELECONSULTATION SERVICES™
1-800-838-4268 info@sonopath.com SonoPath.com

PATIENT

Skye Ewles

SPECIES

Canine

BREED

Australian Cattle Dog

SEX

Spayed Female

AGE

5 Years

WEIGHT

31.5 Pounds

INTERPRETED BY

Kathleen Sennello DVM,
MS, Diplomate ACVIM
(Small Animal Internal
Medicine)

**IMAGING
PERFORMED BY**

Amy Mayhew, LVT

HOSPITAL NAME

SVS Imaging MI

REFERRING VET

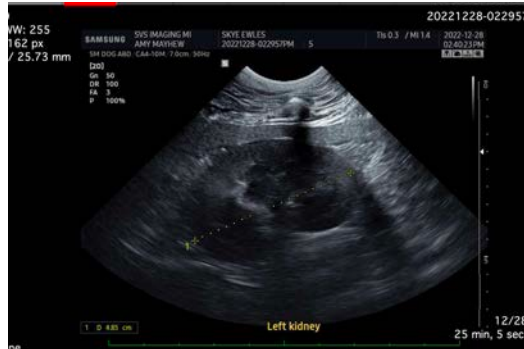Briarwood VH

INVOICE

43789

DATE

12/28/22



The information and recommendations provided are based on the images presented by the referring veterinarian/sonographer. No evaluation can be communicated regarding pathology that was not visible in the image/video clips provided.

Thank you for this referral. If the clinical or image interpretation does not parallel your findings or if I can be of any further assistance please contact me.

Kathleen Sennello DVM,MS, Diplomate ACVIM (Small animal Internal Medicine)

kathleen.sennello@sonopath.com