

**DATE PRESENTING CLINICAL SIGNS**

12/28/22 Chronically decreased appetite and weight loss despite cerenia, diarrhea, possible exposure to rat bait per owner but in theory would have been a month ago?

PATIENT

Herbie Weibe
Current Medications: Cerenia 24 mg 2 PO SID, Entyce PO SID
Metronidazole 250 mg PO BID
Lab Results: See attached.

SPECIES

Canine

Date of Previous IntraPet Ultrasound: No previous.
Sedation: Not required to complete full diagnostic ultrasound.
Stat Report: Not requested.

BREED

Corgi

ULTRASONOGRAPHIC EXAMINATION OF THE ABDOMEN**Urinary System**

The urinary bladder is moderately distended with anechoic urine. The Bladder wall, trigone, ureteral papillae and visible urethra (to a depth of 2cm) appear normal with no evidence of wall thickening, mucosal irregularities, masses or cystic calculi.

SEX

Neutered Male

The prostate is normal in size (0.99 cm) and shape for this neutered male dog. The parenchyma is homogenous and the external margins are smooth. The prostatic urethra appears normal with no evidence of irregularity, invasion, mass effect or calculi.

AGE

4/15/14

The left kidney has a normal shape and size (5.45 cm) with mild pyelectasia at 0.20 cm. Overall echogenicity is normal with adequate corticomedullary distinction and a typical 1:3 cortex:medulla ratio. There is no evidence of focal perinephric inflammation or effusion. There is no evidence of nephroliths, infarcts or hydronephrosis. Renal vasculature is normal.

WEIGHT

30 Pounds

INTERPRETED BY

Kathleen Sennello DVM,
MS, Diplomate ACVIM
(Small Animal Internal
Medicine)

The right kidney has a normal shape and size (6.08 cm) with mild pyelectasia at 0.18 cm. Overall echogenicity is normal with adequate corticomedullary distinction and a typical 1:3 cortex:medulla ratio. There is no evidence of focal perinephric inflammation or effusion. There is no evidence of nephroliths, infarcts or hydronephrosis. Renal vasculature is normal.

HOSPITAL NAME

Airpark AH

Adrenal Glands

There appear to be two structures visualized in the region of the left adrenal with the typical appearance and morphology of a left adrenal gland. The first structure is hypoechoic with a similar appearance to the right adrenal gland. This measures 0.84 cm at the cranial pole, 0.93 cm at the caudal pole, and 2.27 cm in length. It is observed in its normal position cranial to the left renal artery. There is no evidence of vascular invasion.

REFERRING VET

Dr. Owens

There is another structure that is visualized slightly more lateral to the first structure that has a shape and morphology very similar to an adrenal gland. This structure measures 0.88 cm at the cranial pole, 0.91 cm at the caudal pole, and 2.77 cm in length. It is somewhat heterogeneous and has a less hypoechoic echotexture- this is likely an atypical lymph node in the region but a CT scan would likely be necessary to rule out a very odd presentation (second adrenal??) etc..

INVOICE

43783

The right adrenal gland is normal in size measuring 0.75 cm at the caudal pole. It is observed in its normal position between the cranial aspect of the right kidney and the caudal vena cava. It is normal in appearance (uniformly hypoechoic) and shape with no evidence of a mass effect.

Spleen

The spleen is large and irregular. The spleen echotexture is heterogenous and mildly mottled, the splenic capsule is smooth with no irregularities. The blood flow through the hilus and splenic parenchyma appears normal. There are three irregular areas/bulges/isoechoic mass effects associated with the spleen. One in the

cranial aspect of the spleen measures 1.91 cm x 1.64 cm. A mid body lesion is 2.0 cm in diameter. A third towards the tail of the spleen measures 1.59 cm x 1.55 cm.

Liver

The liver is large in size, and normal in echogenicity with smooth peripheral margins. The parenchyma is heterogenous in echotexture with subtle, indistinct focal mottling. The visible portions of the vasculature and biliary tract appear normal. The hepatic parenchyma is diffusely nodular with too numerous to count ill-defined hypoechoic nodules ranging in size from approximately 0.25-1.0 cm.

The gall bladder lumen is moderately distended. The wall of the gall bladder is not thickened and has a smooth mucosal surface. There is a moderate amount of non-organized echogenic debris. The cystic and common bile ducts are normal/not visible.

Gastrointestinal

The stomach contains minimal luminal contents. It measures at a normal thickness of <0.7cm with some variability due to the presence of rugal folds. The distinction of the gastric wall layers is adequate and there is no impression of reduced peristaltic activity. No masses or focal lesions were observed.

The visualized areas of duodenum, jejunum and ileum have a relatively uniform diameter with minimal fluid distension. Wall thickness is normal. Bowel loops follow a curvilinear path with distinct wall layering maintaining the typical 1:3 muscularis:mucosa layer ratio. The duodenum measured as normal (between 0.3-0.5cm in wall thickness) and the jejunum measured as normal (between 0.2-0.47cm.) Visualized peristalsis appears appropriate. There were no focal lesions consistent with obstruction or a mass effect observed.

The ileocecal junction was visualized and exhibited normal intact wall layering and is subjectively of normal thickness. Sections of colon are visualized with formed fecal material and gas shadowing distally. There is no observed focal or generalized colon wall thickening or loss of layering.

Pancreas

The pancreas is normal and isoechoic to surrounding mesentery. There is no evidence of nodules or cystic lesions. There is no evidence of regional mesenteric inflammation or fluid.

Free Abdomen

Evaluation of the peritoneal cavity did not reveal any evidence of effusion, or subjective lymphadenomegaly. The Medial iliac nodes appear normal and there was no evidence of a caudal aortic thrombus at the bifurcation-there is possibly an atypical renal lymph node visualized (see left adrenal). The omentum is of normal uniform echogenicity.

Other

A brief view of the heart was submitted. No significant pericardial effusion was seen.

ULTRASONOGRAPHIC FINDINGS

- Large, irregular spleen with numerous isoechoic “bulges”/mass effects – These lesions could represent parenchymal irregularities or bulges, or they could represent isoechoic mass effects. Recommend a fine needle aspirate of several areas of the spleen.
- Large, heterogeneous, nodular liver – The diffuse hepatic changes are non-specific and could be consistent with vacuolar hepatopathy, nodular hyperplasia, inflammatory/immune-mediated disease, fibrosis, extramedullary hematopoiesis, toxic hepatopathy (e.g., copper), infiltrative neoplasia (less likely) or other hepatopathy. The nodules observed trend toward a more benign process but underlying neoplasia cannot be ruled out.

- Moderate gallbladder debris – The significance of the aggregated gallbladder debris is unclear. This could represent an early mucocele, cholestasis, or may be secondary to fasting but seems unlikely to be causing a current issue. Recommend continued monitoring.
- Structure visualized adjacent to the left adrenal gland. This structure is somewhat heterogeneous and currently of unknown significance- poss atypical ln?

INTERPRETATION OF THE FINDINGS & FURTHER RECOMMENDATIONS

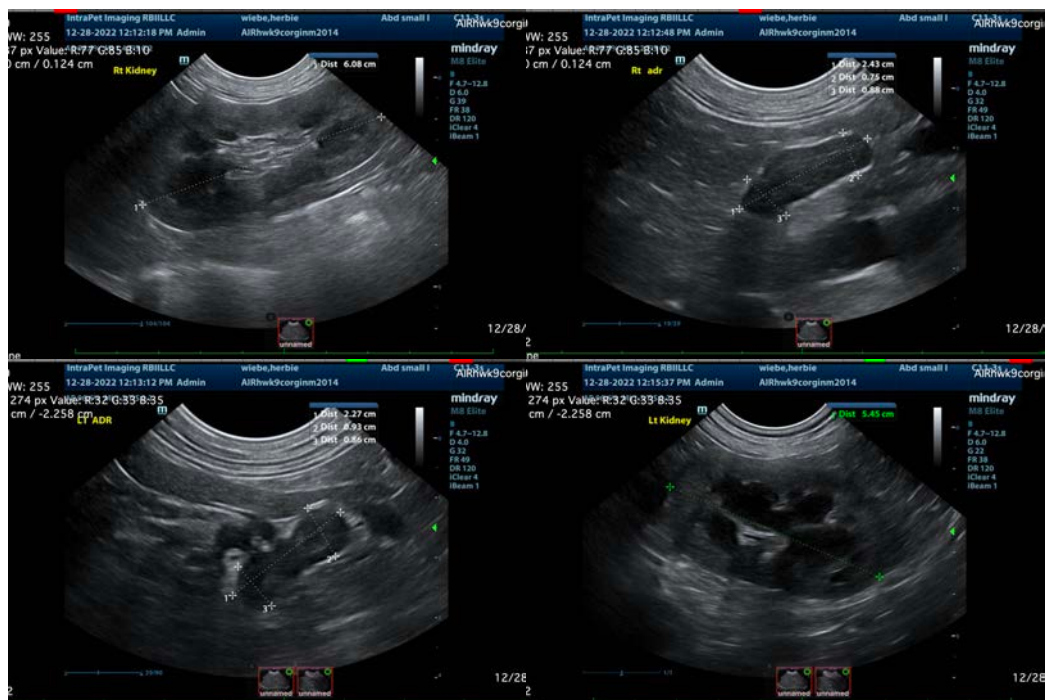
An obvious lesion responsible for the current clinical signs is not clearly visualized. The liver is large and heterogeneous with ill-defined hypochoic nodules. These nodules trend towards a more benign appearance. Consider a liver function test and a fine needle aspirate of the liver.

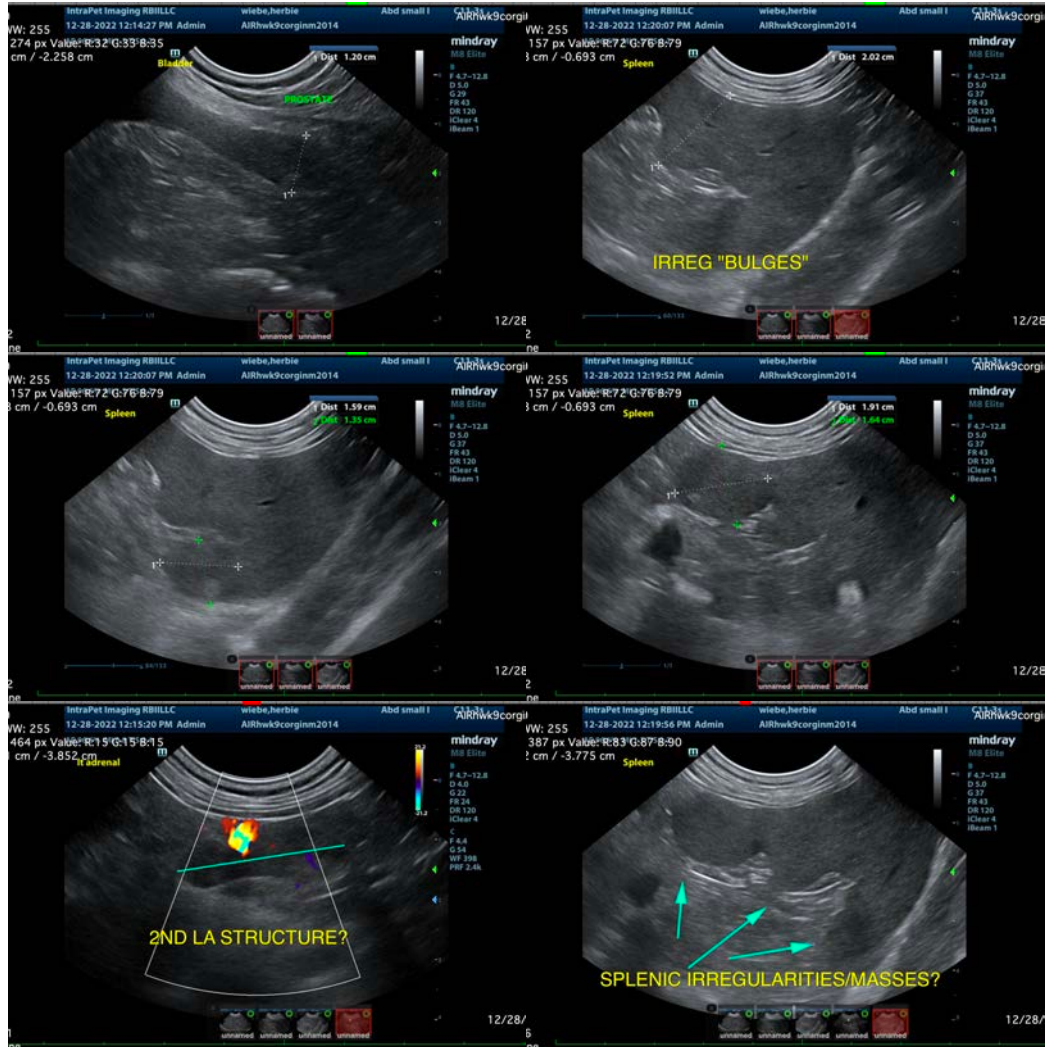
The spleen is large with several atypical “bulges” or mass effects. Recommend a fine needle aspirate of multiple areas of spleen.

Both typical adrenals appear relatively normal and hypochoic. There is a 3rd structure associated with the left kidney that has the appearance of an atypical left adrenal gland but is most likely an irregular lymph node. Consider a contrast CT scan of this region to better clarify if desired.

Consider the possibility of primary gastrointestinal disease a cause for the symptoms described, as this can sometimes have minimal ultrasonographic findings. Consider a GI panel to Texas A&M for a qualitative PLI, TLI, cobalamin and folate to further evaluate.

Recommend three view thoracic radiographs to evaluate for possible concurrent thoracic disease/involvement.





The information and recommendations provided are based on the images presented by the referring veterinarian/sonographer. No evaluation can be communicated regarding pathology that was not visible in the image/video clips provided.

Thank you for this referral. If the clinical or image interpretation does not parallel your findings or if I can be of any further assistance please contact me.

Kathleen Sennello DVM,MS, Diplomate ACVIM (Small animal Internal Medicine)
 kathleen.sennello@sonopath.com