

**DATE PRESENTING CLINICAL SIGNS**

12/27/22

Patient presents for annual evaluation - doing well at home - concern on labwork screening for progressing increased liver values.

PATIENT

Frannie Lowe

Current Medications: Denamarin SID, Ursodiol 250 mg BID

Lab Results: CBC: MCH: 20.7 (21.9 - 26.1), Reticulocyte hemoglobin: 22.2 (24.5 - 31.8). Chemistry: SMDA: 15 (0 - 14), Potassium: 5.5 (4 - 5.4), Na/K Ratio: 27 (28 - 37), Chloride: 107 (108 - 119), TP: 7.8 (5.5 - 7.5), Albumin: 4.3 (2.7 - 3.9), ALT: 291 (18 - 121), ALP: 463 (5 - 160), GGT: 275 (0 - 13), Tbili: 0.4 (0 - 0.3), Bilirubin-conjugated: 0.2 (0 - 0.1)

SPECIES

Canine

T4: WNL

Date of Previous IntraPet Ultrasound: 11/19/21. See attached.

BREED

Chow Chow

Sedation: IV Torb.

Stat Report: Not requested.

Imaging Performed By: Rachel Brillhart, RDMS.

SEX

Spayed Female

ULTRASONOGRAPHIC EXAMINATION OF THE ABDOMEN**AGE**

1/6/10

Urinary System

The urinary bladder is moderately distended with anechoic urine. The Bladder wall, trigone, ureteral papillae and visible urethra (to a depth of 2cm) appear normal with no evidence of wall thickening, mucosal irregularities, masses or cystic calculi.

WEIGHT

54 Pounds

The left kidney has a normal shape and size (6.85 cm). Overall echogenicity is slightly hyperechoic with poor corticomedullary distinction and a typical 1:3 cortex:medulla ratio. There is no evidence of focal perinephric inflammation or effusion. There are numerous small non-obstructive nephroliths visualized. There is no evidence of pyelectasia, infarcts or hydroureter. Renal vasculature is normal.

INTERPRETED BY

Kathleen Sennello DVM,
MS, Diplomate ACVIM
(Small Animal Internal
Medicine)

The right kidney has a normal shape and size (6.27 cm). Overall echogenicity is slightly hyperechoic with poor corticomedullary distinction and a typical 1:3 cortex:medulla ratio. There is no evidence of focal perinephric inflammation or effusion. There are numerous small non-obstructive nephroliths visualized. There is no evidence of pyelectasia, infarcts or hydroureter. Renal vasculature is normal.

HOSPITAL NAME

Perry Hall AH

Adrenal Glands

The left adrenal gland is normal in size measuring 0.71 cm at the caudal pole. It is observed in its normal position cranial to the left renal artery. It is normal in appearance (uniformly hypoechoic) and shape with no evidence of a mass effect.

REFERRING VET

Dr. Miller

The right adrenal gland is normal in size measuring 0.80 cm at the caudal pole. It is observed in its normal position between the cranial aspect of the right kidney and the caudal vena cava. It is normal in appearance (uniformly hypoechoic) and shape with no evidence of a mass effect.

INVOICE

43736

Spleen

The spleen is subjectively normal in size, echotexture is homogenous, and the splenic capsule is smooth with no irregularities. The blood flow through the hilus and splenic parenchyma appears normal. In the caudal third of the spleen, there is a slightly hypoechoic, rounded mass effect/nodule measuring 1.97 cm x 1.58 cm. This bulges the splenic capsule somewhat.

Liver

The liver is large and irregular. The parenchyma is heterogenous in echotexture with subtle, indistinct focal mottling. The visible portions of the vasculature and biliary tract appear normal. There are numerous ill-defined, hypoechoic and hyperechoic nodules throughout the heterogeneous parenchyma. Additionally, there are more defined lesions. There is a hypoechoic nodule near the gallbladder measuring 2.48 cm. There

is an irregular hypoechoic, heterogeneous mass lesion visualized in the right caudal liver, extending beyond the right kidney, measuring 8.03 cm x 6.62 cm. Additionally, on the left side of the liver there is a mixed echogenic mass effect measuring 7.99 cm x 5.89 cm.

The gall bladder lumen is moderately distended. The wall of the gall bladder is not thickened and has a smooth mucosal surface. There is a moderate amount of dependent hyperechoic, slightly shadowing/sandy debris. The cystic and common bile ducts are normal/not visible.

Gastrointestinal

The stomach contains minimal luminal contents. It measures at a normal thickness of <0.7cm with some variability due to the presence of rugal folds. The distinction of the gastric wall layers is adequate and there is no impression of reduced peristaltic activity. No masses or focal lesions were observed.

The visualized areas of duodenum, jejunum and ileum have a relatively uniform diameter with minimal fluid distension. Wall thickness is normal. Bowel loops follow a curvilinear path with distinct wall layering maintaining the typical 1:3 muscularis:mucosa layer ratio. The duodenum measured as normal (between 0.3-0.5cm in wall thickness) and the jejunum measured as normal (between 0.2-0.47cm.) Visualized peristalsis appears appropriate. There were no focal lesions consistent with obstruction or a mass effect observed.

The ileocecal junction was visualized and exhibited normal intact wall layering and is subjectively of normal thickness. Sections of colon are visualized with formed fecal material and gas shadowing distally. There is no observed focal or generalized colon wall thickening or loss of layering.

Pancreas

The pancreas is normal and isoechoic to surrounding mesentery. There is no evidence of nodules or cystic lesions. There is no evidence of regional mesenteric inflammation or fluid.

Free Abdomen

Evaluation of the peritoneal cavity did not reveal any evidence of effusion, or subjective lymphadenomegaly. The Medial iliac nodes appear normal and there was no evidence of a caudal aortic thrombus at the bifurcation. The omentum is of normal uniform echogenicity.

Other

A brief view of the heart was submitted. No significant pericardial effusion was seen.

PRIMARY FINDINGS

- Mildly hypoechoic splenic nodule/mass – There is a non-cavitated, hypoechoic splenic nodule visualized. Differentials include lymphoid hyperplasia, extramedullary hematopoiesis, infiltrative neoplasia, inflammation, other. Cytology or histopathology would be necessary to get a definitive diagnosis.
- Heterogeneous liver with some well-defined, irregular nodules, a large hypoechoic mass effect, and a mixed echogenic mass effect – These lesions could be consistent with benign or neoplastic lesions and could be related or unrelated.
- Moderate amount of hyperechoic/sandy dependent debris in the gallbladder – The significance of the aggregated gallbladder debris is unclear. This could represent an early mucocele, cholestasis, or may be secondary to fasting but seems unlikely to be causing a current issue. Recommend continued monitoring.

SECONDARY FINDINGS

- Decreased corticomedullary distinction in both kidneys with small non-obstructive nephroliths/mineralizations – The bilateral renal findings are consistent with age-related change.

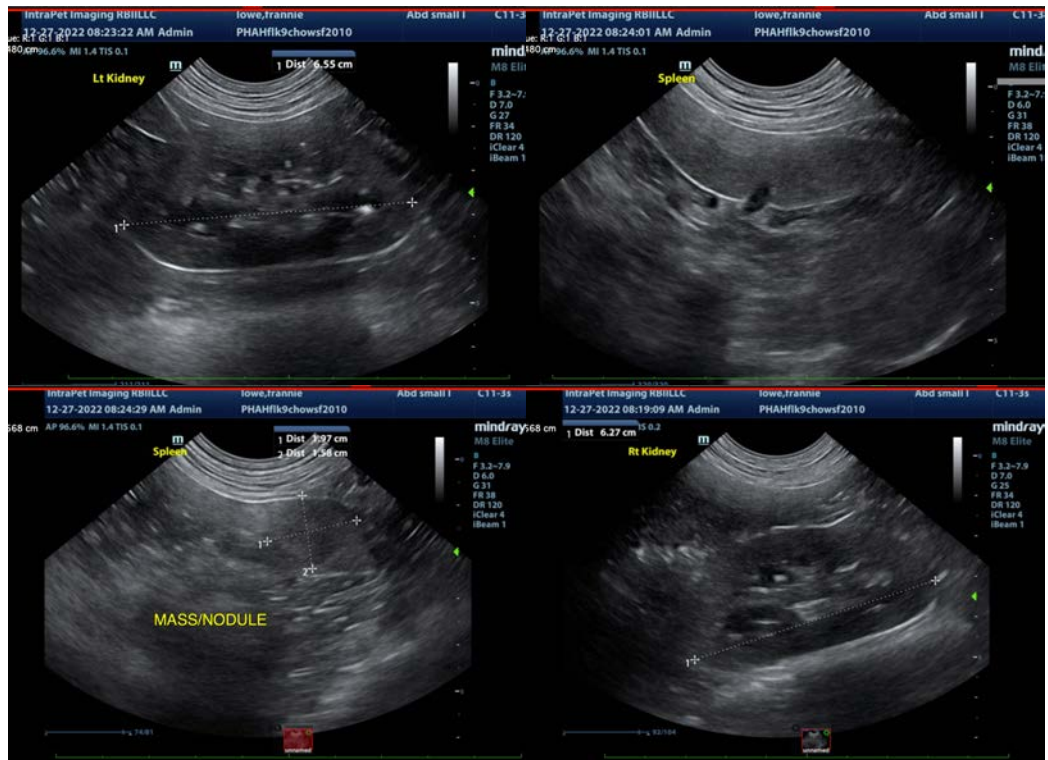
INTERPRETATION OF THE FINDINGS & FURTHER RECOMMENDATIONS

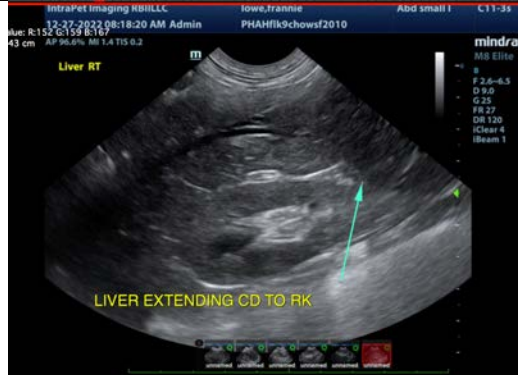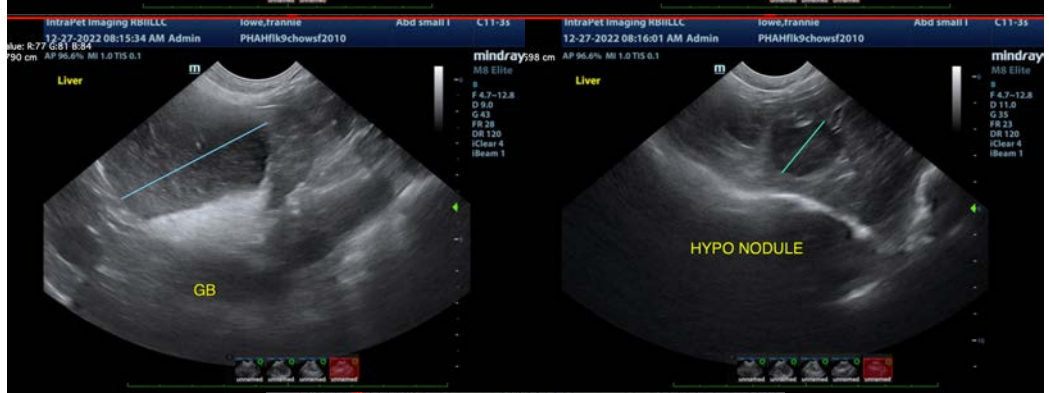
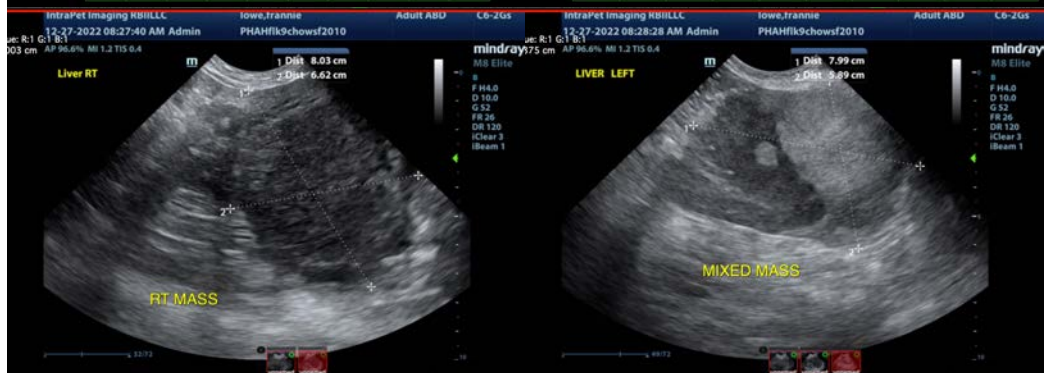
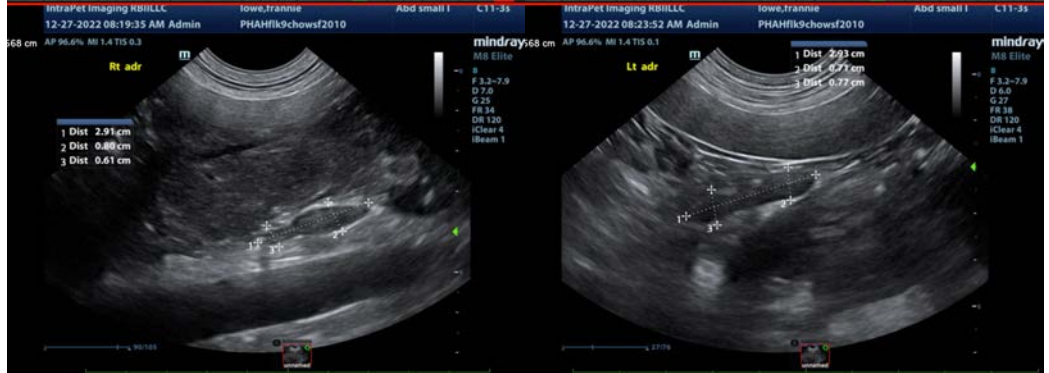
The lesions observed in the liver are prominent. Nonetheless, these could be large regenerative nodules, represent a cancerous process, or possibly a combination of both. Ideally, consider a fine needle aspirate of both the right and left side of the liver, and if surgical removal would be considered, then I would strongly recommend a contrast CT scan to get a better idea of the extent of these lesions and plan the best course of action.

Additionally, there is a slightly hypoechoic nodule in the spleen. This does bulge the parenchyma somewhat but is not cavitated. Consider a fine needle aspirate of this lesion as well.

Considering the mild elevation in bilirubin reported, you may want to consider a liver function test to try and determine if the liver enzymes represent irritation of the liver or there is actual dysfunction present.

Recommend three view thoracic radiographs to evaluate for possible concurrent thoracic disease/involvement.





The information and recommendations provided are based on the images presented by the referring veterinarian/sonographer. No evaluation can be communicated regarding pathology that was not visible in the image/video clips provided.

Thank you for this referral. If the clinical or image interpretation does not parallel your findings or if I can be of any further assistance please contact me.

Kathleen Sennello DVM,MS, Diplomate ACVIM (Small animal Internal Medicine)
kathleen.sennello@sonopath.com