



PATIENT

Marvel Harlan

SPECIES

Canine

BREED

Pomeranian

SEX

Spayed Female

AGE

10 Years

WEIGHT

6.2 lbs

INTERPRETED BY

Kathleen Sennello DVM,
MS, Diplomate ACVIM
(Small Animal Internal
Medicine)

IMAGING PERFORMED BY

Dr. Brittany Wolfe

HOSPITAL NAME

HomeVets

REFERRING VET

Dr. Brittany Wolfe

INVOICE

72753

DATE

12/24/25

PRESENTING CLINICAL SIGNS

New ALP elevation, no clinical signs, P gets regular annual dentals, no clinical signs, P had a splenectomy ~1year ago, splenic mass was benign.

Abnormal PE/Chem/CBC/UA Results: CBC/chem/t4/4dx 10/30/25: CBC: lymphocytosis 6.1 Chem: ALP 186 (previously 101, and before that 74), no change in ALT trends T4 tends to run low, 0.8, but TSH in the past has been normal.

ULTRASONOGRAPHIC EXAMINATION OF THE ABDOMEN

Urinary System

The urinary bladder is moderately distended with anechoic urine. The Bladder wall, trigone, ureteral papillae and visible urethra (to a depth of 2cm) appear normal with no evidence of wall thickening, mucosal irregularities, masses or cystic calculi.

The left kidney has a normal shape and size (3.0 cm). Overall echogenicity is normal with adequate corticomedullary distinction and a typical 1:3 cortex:medulla ratio. There is no evidence of focal perinephric inflammation or effusion. There is no evidence of pyelectasia, nephroliths, infarcts or hydroureter. Renal vasculature is normal.

The right kidney has a normal shape and size (2.97 cm). Overall echogenicity is normal with adequate corticomedullary distinction and a typical 1:3 cortex:medulla ratio. There is no evidence of focal perinephric inflammation or effusion. There is no evidence of pyelectasia, nephroliths, infarcts or hydroureter. Renal vasculature is normal.

Adrenal Glands

The left adrenal gland is normal in size measuring 0.29 cm at the cranial pole and 0.31 cm at the caudal pole. It is observed in its normal position cranial to the left renal artery. It is normal in appearance (uniformly hypoechoic) and shape with no evidence of a mass effect.

The right adrenal gland is normal in size measuring 0.38 cm at the cranial pole and 0.41 cm at the caudal pole. It is observed in its normal position between the cranial aspect of the right kidney and the caudal vena cava. It is normal in appearance (uniformly hypoechoic) and shape with no evidence of a mass effect.

Spleen

The spleen is surgically absent.

Liver

The liver is subjectively normal in size, and echogenicity with smooth peripheral margins. The parenchyma is mildly heterogenous in echotexture with subtle, indistinct focal mottling. The visible portions of the vasculature and biliary tract appear normal. No focal nodules or cystic lesions are observed.

The gall bladder lumen is moderately distended. The wall of the gall bladder is not thickened and has a smooth mucosal surface. Luminal contents are mild and likely incidental at this time. The cystic and common bile ducts are normal/not visible.



PATIENT

Marvel Harlan

SPECIES

Canine

BREED

Pomeranian

SEX

Spayed Female

AGE

10 Years

WEIGHT

6.2 lbs

INTERPRETED BY

Kathleen Sennello DVM,
MS, Diplomate ACVIM
(Small Animal Internal
Medicine)

IMAGING PERFORMED BY

Dr. Brittany Wolfe

HOSPITAL NAME

HomeVets

REFERRING VET

Dr. Brittany Wolfe

INVOICE

72753

DATE

12/24/25

Gastrointestinal

The stomach contains minimal luminal contents. It measures at a normal thickness of <0.7cm with some variability due to the presence of rugal folds. The distinction of the gastric wall layers is adequate and there is no impression of reduced peristaltic activity. No masses or focal lesions were observed.

The visualized areas of duodenum, jejunum and ileum have a relatively uniform diameter with minimal fluid distension. Wall thickness is normal. Bowel loops follow a curvilinear path with distinct wall layering maintaining the typical 1:3 muscularis:mucosa layer ratio. Jejunum wall measures 0.26 cm. Visualized peristalsis appears appropriate. There were no focal lesions consistent with obstruction or a mass effect observed.

Sections of colon are visualized with formed fecal material and gas shadowing distally. There is no observed focal or generalized colon wall thickening or loss of layering.

Pancreas

The area of the pancreas is normal and isoechoic to surrounding mesentery. There is no evidence of nodules or cystic lesions. There is no evidence of regional mesenteric inflammation or fluid.

Free Abdomen

Evaluation of the peritoneal cavity did not reveal any evidence of effusion, or subjective lymphadenomegaly. The Medial iliac nodes appear normal and there was no evidence of a caudal aortic thrombus at the bifurcation. The omentum is of normal uniform echogenicity.

ULTRASONOGRAPHIC FINDINGS

- Surgically absent spleen.
- Mildly heterogeneous liver – The diffuse hepatic changes are non-specific and could be consistent with vacuolar hepatopathy, nodular hyperplasia, inflammatory/immune-mediated disease, fibrosis, extramedullary hematopoiesis, toxic hepatopathy (e.g., copper), infiltrative neoplasia (less likely) or other hepatopathy.

INTERPRETATION OF THE FINDINGS & FURTHER RECOMMENDATIONS

The changes observed on today's scan are very mild. Subjectively, the liver is mildly heterogeneous. This is a non-specific finding. Given the history provided, a mild vacuolar hepatopathy would be the most likely differential. Further evaluation could include pre- and post-prandial bile acids to assess liver function. If there is concern for more significant liver disease you could consider a fine needle aspirate, or if liver values are progressively elevated and liver function is abnormal, a biopsy of the liver with samples for histopathology, culture and copper levels could be considered. For now, if there are no symptoms, I would consider establishing a normal baseline liver function test and starting chronic Denamarin therapy with continued monitoring.



PATIENT

Marvel Harlan

SPECIES

Canine

BREED

Pomeranian

SEX

Spayed Female

AGE

10 Years

WEIGHT

6.2 lbs

INTERPRETED BY

Kathleen Sennello DVM,
MS, Diplomate ACVIM
(Small Animal Internal
Medicine)

**IMAGING
PERFORMED BY**

Dr. Brittany Wolfe

HOSPITAL NAME

HomeVets

REFERRING VET

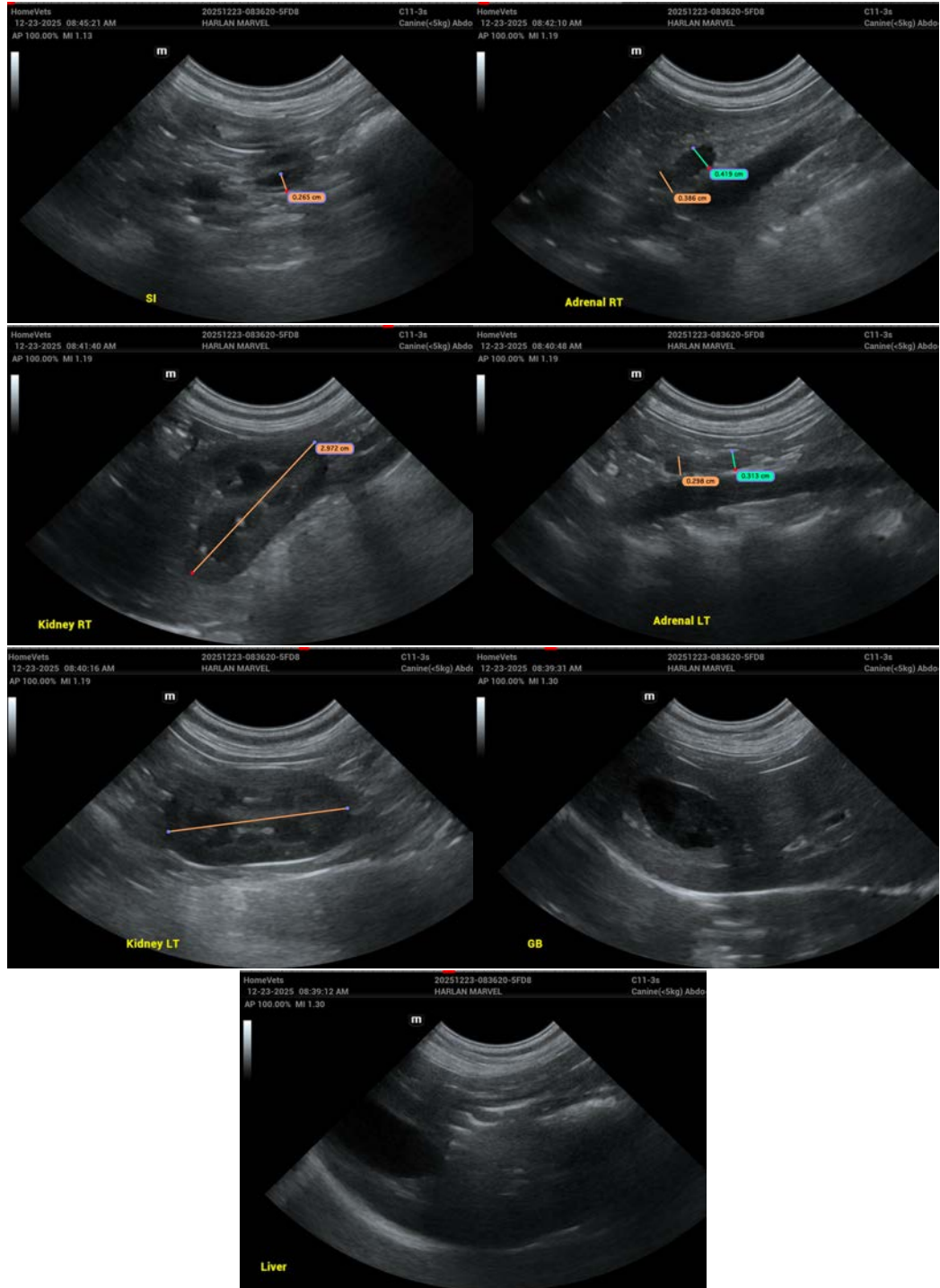
Dr. Brittany Wolfe

INVOICE

72753

DATE

12/24/25





PATIENT

Marvel Harlan

SPECIES

Canine

BREED

Pomeranian

SEX

Spayed Female

AGE

10 Years

WEIGHT

6.2 lbs

INTERPRETED BY

Kathleen Sennello DVM,
MS, Diplomate ACVIM
(Small Animal Internal
Medicine)

IMAGING PERFORMED BY

Dr. Brittany Wolfe

HOSPITAL NAME

HomeVets

REFERRING VET

Dr. Brittany Wolfe

INVOICE

72753

DATE

12/24/25

The information and recommendations provided are based on the images presented by the referring veterinarian/sonographer. No evaluation can be communicated regarding pathology that was not visible in the image/video clips provided.

Thank you for this referral. If the clinical or image interpretation does not parallel your findings or if I can be of any further assistance please contact me.

Kathleen Sennello DVM,MS, Diplomate ACVIM (Small animal Internal Medicine)

info@sonopath.com