



**PATIENT PRESENTING CLINICAL SIGNS**

**PATIENT**  
Ronan Cogar

**SPECIES**  
Canine

Ronan presented for his routine annual exam. He has a history of chronic allergies (managed by dermatologist with immunotherapy and Ultamino diet) but is currently well controlled. At his annual, an ~ 2lbs weight loss was noted - no vomiting, diarrhea or decrease in appetite. Bloodwork showed mildly low albumin with no evidence of proteinuria. Recommended GI panel + abdominal ultrasound to assess for possible reason for hypoalbuminemia

**BREED**  
Soft Coated Wheaten Terrier

**ULTRASONOGRAPHIC EXAMINATION OF THE ABDOMEN**  
*Urinary System*

The urinary bladder is moderately distended with anechoic urine. The Bladder wall, trigone, ureteral papillae and visible urethra (to a depth of 2cm) appear normal with no evidence of wall thickening, mucosal irregularities, masses or cystic calculi.

**SEX**

Neutered male

The visualized areas of prostate and surrounding tissue appear normal. Unfortunately, the prostate is not fully visualized likely due to its intrapelvic location. Correlate with rectal exam findings.

**AGE**

9 year

The left kidney has a normal shape and size (5.3 cm). Overall echogenicity is normal with adequate corticomedullary distinction and a typical 1:3 cortex:medulla ratio. There is no evidence of perinephric inflammation or effusion. There is no evidence of pyelectasia, nephroliths, infarcts or hydroureter. Renal vasculature is normal.

**WEIGHT**

36.8 lbs

The right kidney has a normal shape and size (5.6 cm). Overall echogenicity is normal with adequate corticomedullary distinction and a typical 1:3 cortex:medulla ratio. There is no evidence of perinephric inflammation or effusion. There is no evidence of pyelectasia, nephroliths, infarcts or hydroureter. Renal vasculature is normal.

**INTERPRETED BY**

Kathleen Sennello  
DVM, MS, Diplomate  
ACVIM (Small Animal  
Internal Medicine)

**Adrenal Glands**

The region of left adrenal (Cranial to left renal artery) is unremarkable but the adrenal is not distinctly visualized. No evidence of a mass effect.

**IMAGING PERFORMED BY**

Kelly Vazquez , CVT

The region of the right adrenal (between right cranial kidney and vena cava) is unremarkable, but the adrenal is not distinctly visualized. No evidence of a mass effect.

**HOSPITAL NAME**

Kings VH

**Spleen**

The spleen is subjectively normal in size, echotexture is homogenous, and the splenic capsule is smooth with no irregularities. The blood flow through the hilus and splenic parenchyma appears normal. No focal parenchymal abnormalities are visualized.

**REFERRING VET**

Dr. Puthoff

**Liver**

The liver is subjectively normal/borderline small in size, and echogenicity with smooth peripheral margins. The parenchyma is homogenous echotexture. The visible portions of the vasculature and biliary tract appear normal. There is a subtle 1.5 cm hyperechoic nodule visualized in the parenchyma. The gallbladder lumen is moderately distended. The wall of the gallbladder is not thickened and has a smooth mucosal surface. Luminal contents are primarily anechoic. The cystic and common bile ducts are normal/not visible.

**INVOICE**

94891

**DATE**

12/23/21



**PATIENT**

Ronan Cogar

**Gastrointestinal**

**SPECIES**

Canine

The stomach contains minimal luminal contents. It measures at a normal thickness of <0.7cm with some variability due to the presence of rugal folds. The distinction of the gastric wall layers is adequate and there is no impression of reduced peristaltic activity. No masses or focal lesions were observed.

**BREED**

Soft Coated Wheaton Terrier

The visualized areas of duodenum, jejunum and ileum have a relatively uniform diameter with minimal fluid distension. Wall thickness is normal. Bowel loops follow a curvilinear path with distinct wall layering maintaining the typical 1:3 muscularis:mucosa layer ratio. The duodenum measured as normal and the jejunum measured as normal (0.35 cm). Visualized peristalsis appears appropriate. There were no focal lesions consistent with obstruction or a mass effect observed.

**SEX**

Neutered male

The ileocecal junction was visualized and exhibited normal intact wall layering and is subjectively of normal thickness. Sections of colon are visualized with formed fecal material and gas shadowing distally. There is no observed focal or generalized colon wall thickening or loss of layering.

**AGE**

9 year

**Pancreas**

The pancreas is normal and isoechoic to surrounding mesentery. There is no evidence of nodules or cystic lesions. There is no evidence of regional mesenteric inflammation or fluid.

**WEIGHT**

36.8 lbs

**Free Abdomen**

Evaluation of the peritoneal cavity did not reveal any evidence of effusion, or subjective lymphadenomegaly. The Medial iliac nodes appear normal and there was no evidence of a caudal aortic thrombus at the bifurcation. The omentum is of normal uniform echogenicity.

**INTERPRETED BY**

Kathleen Sennello  
DVM, MS, Diplomate  
ACVIM (Small Animal  
Internal Medicine)

**ULTRASONOGRAPHIC FINDINGS**

**IMAGING PERFORMED BY**

Kelly Vazquez, CVT

**PRIMARY FINDINGS:**

- Borderline small liver with small hyperechoic nodule. Correlate findings with radiographs as they will more accurately assess liver size in a deeper chested dog. The hepatic nodule could be benign or represent neoplastic change. A benign lesion is highly favored.

**HOSPITAL NAME**

Kings VH

**INTERPRETATION OF THE FINDINGS & FURTHER RECOMMENDATIONS**

Other than a small subtle nodule visualized in the liver today's scan appears relatively normal. Nonetheless significant liver, GI or renal disease can be present:

- If not already done I recommend urine protein to creatinine ratio, urinalysis and urine culture.
- Recommend blood pressure evaluation.
- Recommend pre and post prandial bile acids to assess liver function.
- Recommend GI panel to Texas A&M for qualitative PLI, TLI, cobalamin and folate to further evaluate the small intestine.

**REFERRING VET**

Dr. Puthoff

**INVOICE**

94891

Hopefully with this information you will have a better idea if there is a significant protein losing nephropathy, enteropathy, or liver dysfunction (or a combination of these) and can further pursue diagnostics with a more directed approach.

**DATE**

12/23/21



**PATIENT**

Ronan Cogar

**SPECIES**

Canine

**BREED**

Soft Coated Wheaton Terrier

**SEX**

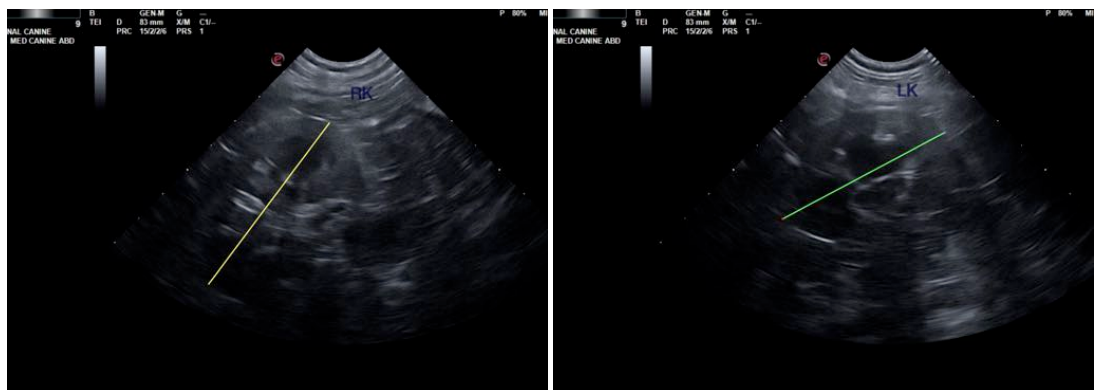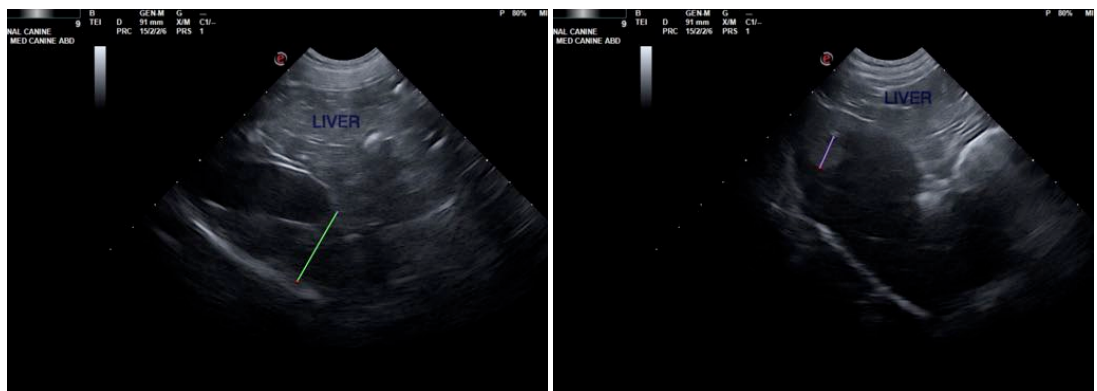
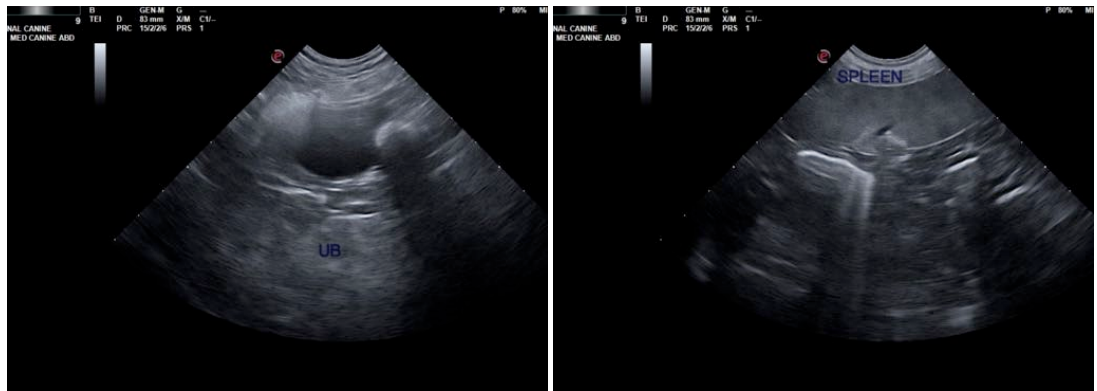
Neutered male

**AGE**

9 year

**WEIGHT**

36.8 lbs



**INTERPRETED BY**

Kathleen Sennello  
DVM, MS, Diplomate  
ACVIM (Small Animal  
Internal Medicine)

**IMAGING PERFORMED BY**

Kelly Vazquez, CVT

**HOSPITAL NAME**

Kings VH

**REFERRING VET**

Dr. Puthoff

**INVOICE**

94891

**DATE**

12/23/21

The information and recommendations provided are based on the images presented by the referring veterinarian. No evaluation can be communicated regarding pathology that was not visible in the image/video clips provided.

Thank you for this referral. If the clinical or image interpretation does not parallel your findings or if I can be of any further assistance please contact me.

Kathleen Sennello DVM,MS, Diplomate ACVIM (Small animal Internal Medicine)  
kathleen.sennello@sonopath.com