



PATIENT

Tiglet Armstrong

SPECIES

Feline

BREED

DMH

SEX

Neutered Male

AGE

13 Years

WEIGHT

5.6 kg

INTERPRETED BY

Kathleen Sennello
DVM, MS, Diplomate
ACVIM (Small Animal
Internal Medicine)

**IMAGING
PERFORMED BY**

Crystal Hill

HOSPITAL NAME

Cat Hospital of
Burlington

REFERRING VET

Dr. O'Connor

INVOICE

33672

DATE

12/22/21

PRESENTING CLINICAL SIGNS

Elevated AST and weight loss. Eating recovery food only at this time. Liver disease suspected. On metacam, Gabapentin and Atenolol.

Abnormal PE/Chem/CBC/UA Results: CBC normal, AST 452(6-70, rest of chemistry within normal limits.

ULTRASONOGRAPHIC EXAMINATION OF THE ABDOMEN

Urinary System

The urinary bladder is moderately distended with anechoic urine. The Bladder wall, trigone, ureteral papillae and visible urethra (to a depth of 2cm) appear normal with no evidence of wall thickening, mucosal irregularities, masses or cystic calculi.

The left kidney has a normal shape and size (3.97 cm) with pyelectasia at 0.24 cm. Overall echogenicity is slightly hyperechoic with mildly reduced corticomedullary distinction and a typical 1:3 cortex:medulla ratio. There is no evidence of perinephric inflammation or effusion. There is no evidence of nephroliths, infarcts or hydroureter. Renal vasculature is normal.

The right kidney has a normal shape and size (4.1 cm). Overall echogenicity is slightly hyperechoic with mildly reduced corticomedullary distinction and a typical 1:3 cortex:medulla ratio. There is no evidence of perinephric inflammation or effusion. There is no evidence of pyelectasia, nephroliths, infarcts or hydroureter. Renal vasculature is normal.

Adrenal Glands

The left adrenal gland is normal in size measuring 0.44 cm at the caudal pole. It is observed in its normal position cranial to the left renal artery. It is normal in appearance (uniformly hypoechoic) and shape with no evidence of a mass effect.

The right adrenal gland is normal in size measuring 0.43 cm at the caudal pole. It is observed in its normal position between the cranial aspect of the right kidney and the caudal vena cava. It is normal in appearance (uniformly hypoechoic) and shape with no evidence of a mass effect.

Spleen

The spleen is subjectively normal in size, echotexture is homogenous, and the splenic capsule is smooth with no irregularities. The blood flow through the hilus and splenic parenchyma appears normal. No focal parenchymal abnormalities are visualized.

Liver

The liver is subjectively normal in size and hyperechoic with smooth peripheral margins. The parenchyma is heterogenous in echotexture with subtle, indistinct focal mottling. The visible portions of the vasculature and biliary tract appear normal. No focal nodules or cystic lesions are observed.

The gallbladder lumen is minimally distended. The wall of the gallbladder is mildly thickened at 0.35 cm and has a smooth mucosal surface. Luminal contents are primarily anechoic. The cystic and common bile ducts are normal/not visible. Lack of gallbladder distention may falsely increase wall thickness.

Gastrointestinal

The stomach is moderately dilated with fluid and irregular shadowing material most consistent with normal ingesta and gas. It measures at a normal thickness of <0.36cm with some variability due to the


PATIENT

Tigtlet Armstrong

presence of rugal folds. The distinction of the gastric wall layering is adequate and there is no impression of reduced peristaltic activity. No masses or focal lesions were observed.

SPECIES

Feline

The visualized areas of duodenum, jejunum and ileum have a uniform diameter with minimal fluid distension. Wall thickness is normal to slightly increased. Bowel loops follow a typical curvilinear path with distinct wall layering, but some areas display a prominent muscularis layer which does not display the typical 1:3 muscularis:mucosa layer ratio. Jejunum wall measures 0.21 cm. Visualized peristalsis appears appropriate. There were no focal lesions consistent with obstruction or a mass effect observed.

BREED

DMH

The ileocecal junction was visualized and exhibited normal intact wall layering and is subjectively of normal thickness. Sections of colon are visualized with formed fecal material and gas shadowing distally. There is no observed focal or generalized colon wall thickening or loss of layering.

Pancreas
SEX

Neutered Male

The pancreas is normal and isoechoic to surrounding mesentery. There is no evidence of nodules or cystic lesions. There is no evidence of regional mesenteric inflammation or fluid.

Free Abdomen
AGE

13 Years

Evaluation of the peritoneal cavity did not reveal any significant free fluid. There are occasional clusters of prominent mesenteric lymph nodes, primarily in the root of the mesentery, measuring 0.68, 0.45 cm. The omentum is of increased echogenicity around this cluster of lymph nodes.

WEIGHT

5.6 kg

PRIMARY FINDINGS

- Prominent muscularis layer to the small intestine – The small intestinal wall changes are most consistent with an inflammatory process (i.e., inflammatory bowel disease) with a low possibility of emerging lymphoma.
- Mild mesenteric lymphadenopathy – The prominent abdominal lymph nodes are most consistent with reactive lymphadenitis or lymphoid hyperplasia. Neoplastic infiltration is considered less likely.
- Hyperechoic, heterogeneous liver – Hepatic changes are non-specific and could be consistent with hepatic lipidosis, inflammatory/infectious disease, infiltrative neoplasia, or other hepatopathy.
- Decreased corticomedullary distinction in both kidneys with mild left-sided pyelectasia – The bilateral renal findings are consistent with age-related change. Pyelectasia of the left kidney could be consistent with pyelonephritis, chronic renal disease, secondary to PU/PD or fluid therapy (if applicable), other.

INTERPRETED BY

 Kathleen Sennello
 DVM, MS, Diplomate
 ACVIM (Small Animal
 Internal Medicine)

IMAGING PERFORMED BY

Crystal Hill

HOSPITAL NAME

 Cat Hospital of
 Burlington

REFERRING VET

Dr. O'Connor

SECONDARY FINDINGS

- Moderate distention of the gastric lumen and small intestine with ingesta – most consistent with a non-fasted patient. If the patient is adequately fasted, then consider such differentials as delayed gastric emptying time, and less likely gastric foreign material/partial obstruction (none visualized).

INVOICE

33672

DATE

12/22/21

INTERPRETATION OF THE FINDINGS & FURTHER RECOMMENDATIONS

The changes observed on today's scan are relatively mild. No large focal mass lesions were observed. There is the general impression of prominent small intestinal walls with fluid dilated bowel and mildly prominent mesenteric lymph nodes. Additionally, the liver is slightly heterogeneous, and the gallbladder wall is thickened, but it is minimally distended, so the significance of this is unclear. Consider:



PATIENT

Tiglet Armstrong

SPECIES

Feline

BREED

DMH

SEX

Neutered Male

AGE

13 Years

WEIGHT

5.6 kg

INTERPRETED BY

Kathleen Sennello
DVM, MS, Diplomate
ACVIM (Small Animal
Internal Medicine)

IMAGING PERFORMED BY

Crystal Hill

HOSPITAL NAME

Cat Hospital of
Burlington

REFERRING VET

Dr. O'Connor

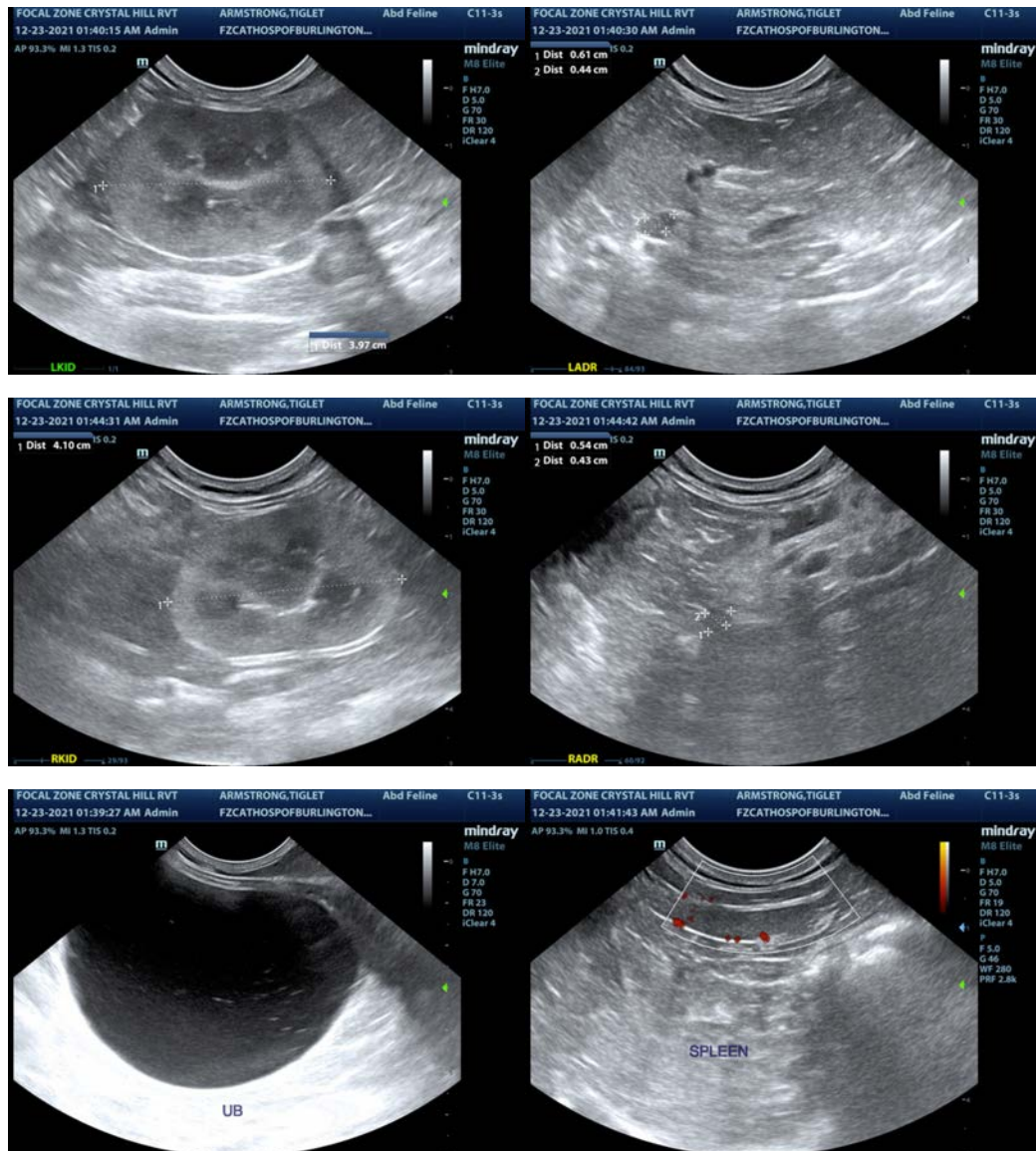
INVOICE

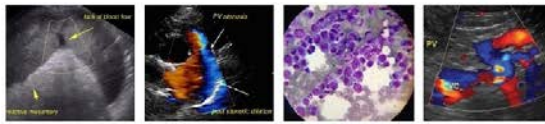
33672

DATE

12/22/21

- Recommend a GI panel to Texas A&M for a qualitative fPLI, TLI, cobalamin and folate to further evaluate for underlying small intestinal disease.
- Consider a novel protein/hydrolyzed protein diet.
- If weight loss persists and the GI panel is abnormal, consider obtaining GI biopsies.
- Recommend 3-view thoracic radiographs to evaluate for concurrent intrathoracic disease.
- Recommend a liver function test to evaluate for significant liver disease.
- If liver function is abnormal or liver values continue to rise, consider a fine needle aspirate of the liver.
- Recommend urinalysis and culture to evaluate the pyelectasia noted and consider blood pressure evaluation.





PATIENT

Tiglet Armstrong

SPECIES

Feline

BREED

DMH

SEX

Neutered Male

AGE

13 Years

WEIGHT

5.6 kg

INTERPRETED BY

Kathleen Sennello
DVM, MS, Diplomate
ACVIM (Small Animal
Internal Medicine)

**IMAGING
PERFORMED BY**

Crystal Hill

HOSPITAL NAME

Cat Hospital of
Burlington

REFERRING VET

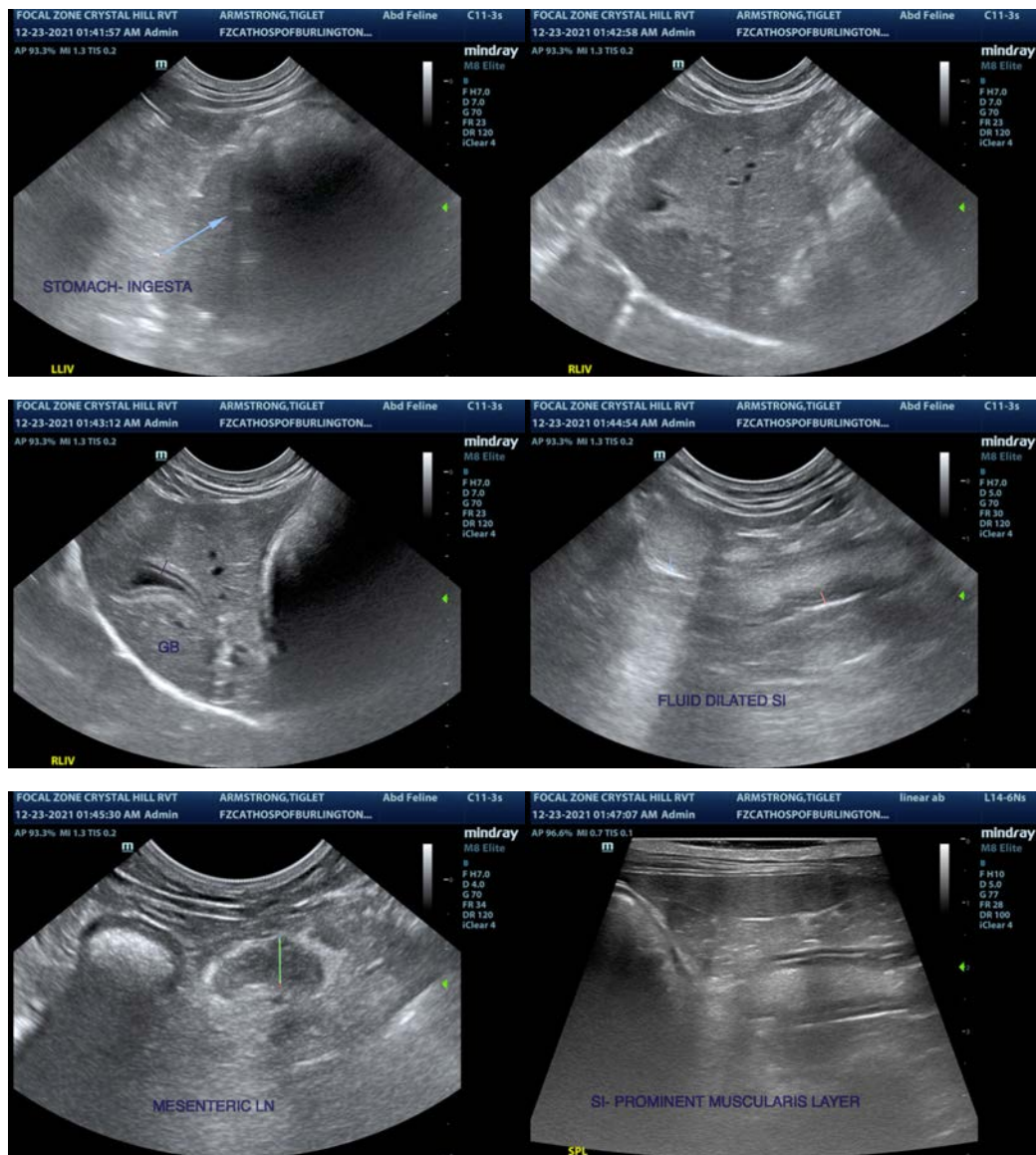
Dr. O'Connor

INVOICE

33672

DATE

12/22/21



The information and recommendations provided are based on the images presented by the referring veterinarian. No evaluation can be communicated regarding pathology that was not visible in the image/video clips provided.

Thank you for this referral. If the clinical or image interpretation does not parallel your findings or if I can be of any further assistance please contact me.

Kathleen Sennello DVM,MS, Diplomate ACVIM (Small animal Internal Medicine)

kathleen.sennello@sonopath.com