

IMAGING PERFORMED BY

IntraPet.com



SonoPath

Clinical Sonography & Telecytology

EDUCATIONAL TELECONSULTATION SERVICES™

1-800-838-4268 info@sonopath.com SonoPath.com

DATE PRESENTING CLINICAL SIGNS

12/21/22

P presents for 2 episodes of lethargy and decreased eating, 5 days ago and then yesterday, o says p seemed painful and had to be coaxed to eat, the days in between p seemed back to "normal" drinking well, no v+, p has some formed bm and some loose, o says after last visit p d+ improved and then had another episode and o bought a probiotic off amazon and that helped.

PATIENT

Cooper Jones

SPECIES

Canine

BREED

Golden Retriever

SEX

Neutered Male

AGE

1/25/13

WEIGHT

85.6 Pounds

INTERPRETED BY

Kathleen Sennello DVM,
MS, Diplomate ACVIM
(Small Animal Internal
Medicine)

IMAGING PERFORMED BY

Stephanie Warga
RDMS, RVT

HOSPITAL NAME

Eldersburg VH

REFERRING VET

Dr. Alper

INVOICE

43610

Current Medications: None.

Lab Results: mild anemia w/ reticulocytes present. low plt (due to blood clot but evaluated as normal amount on blood film). slightly elevated WBCs (secondary to inflammation vs other).

Radiographs: rounded area on liver, splenic nodules present as well as mild effusion noted.

Date of Previous IntraPet Ultrasound: No previous.

Sedation: Not required to complete full diagnostic ultrasound.

Stat Report: Declined at this time.

ULTRASONOGRAPHIC EXAMINATION OF THE ABDOMEN

Urinary System

The urinary bladder is moderately distended with anechoic urine. The Bladder wall, trigone, ureteral papillae and visible urethra (to a depth of 2cm) appear normal with no evidence of wall thickening, mucosal irregularities, masses or cystic calculi.

The prostate is normal in size (0.76 cm) and shape for this neutered male dog. The parenchyma is homogenous, and the external margins are smooth. The prostatic urethra appears normal with no evidence of irregularity, invasion, mass effect or calculi.

The left kidney has a normal shape and size (6.21 cm). Overall echogenicity is normal with adequate corticomedullary distinction and a typical 1:3 cortex:medulla ratio. There is no evidence of focal perinephric inflammation or effusion. There is no evidence of pyelectasia, nephroliths, infarcts or hydroureter. Renal vasculature is normal.

The right kidney has a normal shape and size (6.71 cm). Overall echogenicity is normal with adequate corticomedullary distinction and a typical 1:3 cortex:medulla ratio. There is no evidence of focal perinephric inflammation or effusion. There is no evidence of pyelectasia, nephroliths, infarcts or hydroureter. Renal vasculature is normal.

Adrenal Glands

The left adrenal gland is normal in size measuring 0.63 cm at the caudal pole. It is observed in its normal position cranial to the left renal artery. It is normal in appearance (uniformly hypoechoic) and shape with no evidence of a mass effect.

The right adrenal gland is normal in size measuring 0.80 cm at the caudal pole. It is observed in its normal position between the cranial aspect of the right kidney and the caudal vena cava. It is normal in appearance (uniformly hypoechoic) and shape with no evidence of a mass effect.

Spleen

The spleen is large and irregular. The blood flow through the hilus and splenic parenchyma appears normal. There is a large, hyperechoic, cavitated mass effect arising from the cranial third of the spleen, measuring 5.42 cm x 6.48 cm. Additionally, there is a hypoechoic smaller mass measuring 2.5 cm x 2.57 cm.

Liver

The liver is subjectively normal in size, and echogenicity with smooth peripheral margins. The parenchyma is mildly heterogenous in echotexture with subtle, indistinct focal mottling. The visible portions of the vasculature and biliary tract appear normal. There is a subtle isoechoic, rounded region deep on the left side of the liver. This could represent a rounded area of liver lobe or an isoechoic mass effect. This region measures approximately 6.61 cm x 4.61 cm.

The gall bladder lumen is moderately distended. The wall of the gall bladder is not thickened and has a smooth mucosal surface. There is a moderate amount of non-organized echogenic debris. The cystic and common bile ducts are normal/not visible.

Gastrointestinal

The stomach contains minimal luminal contents. It measures at a normal thickness of <0.7cm with some variability due to the presence of rugal folds. The distinction of the gastric wall layers is adequate and there is no impression of reduced peristaltic activity. No masses or focal lesions were observed.

The visualized areas of duodenum, jejunum and ileum have a uniform diameter with minimal fluid distension. Wall thickness is moderately increased. Bowel loops follow a typical curvilinear path. Some areas have reduced detail of wall layering. Duodenum wall measures 0.40 cm. Jejunum wall measures 0.32 cm. Mucosal speckling is visualized associated with the duodenum. Visualized peristalsis appears appropriate. There were no focal lesions consistent with obstruction or a mass effect observed.

The ileocecal junction was visualized and exhibited normal intact wall layering and is subjectively of normal thickness. Sections of colon are visualized with formed fecal material and gas shadowing distally. There is no observed focal or generalized colon wall thickening or loss of layering.

Pancreas

The pancreas is normal and isoechoic to surrounding mesentery. There is no evidence of nodules or cystic lesions. There is no evidence of regional mesenteric inflammation or fluid.

Free Abdomen

There is a small amount of free abdominal fluid. No lymphadenopathy is noted. The omentum is hyperechoic around the splenic mass lesion.

Other

A brief view of the heart was submitted. No significant pericardial effusion was seen.

ULTRASONOGRAPHIC FINDINGS

- Large, hyperechoic, cavitated splenic mass with a smaller hypoechoic mass effect – A large, heterogenous mass with cavitations is present within the splenic parenchyma. The mass distorts the splenic capsule. Differentials for the mass include neoplasia (e.g., hemangiosarcoma, hemangioma), hematoma, abscess, other. A neoplastic process is favored.
- Irregular rounded and isoechoic area of the left liver – This could represent a rounded liver lobe or an isoechoic mass effect.
- Moderate gallbladder debris – The significance of the aggregated gallbladder debris is unclear. This could represent an early mucocele, cholestasis, or may be secondary to fasting but seems unlikely to be causing a current issue. Recommend continued monitoring.
- Mildly thickened small intestine with mucosal speckling – Bright mucosal speckling has been postulated to represent dilated lacteals or focal accumulations of mucus, cellular debris, etc.. in the

mucosal crypts.

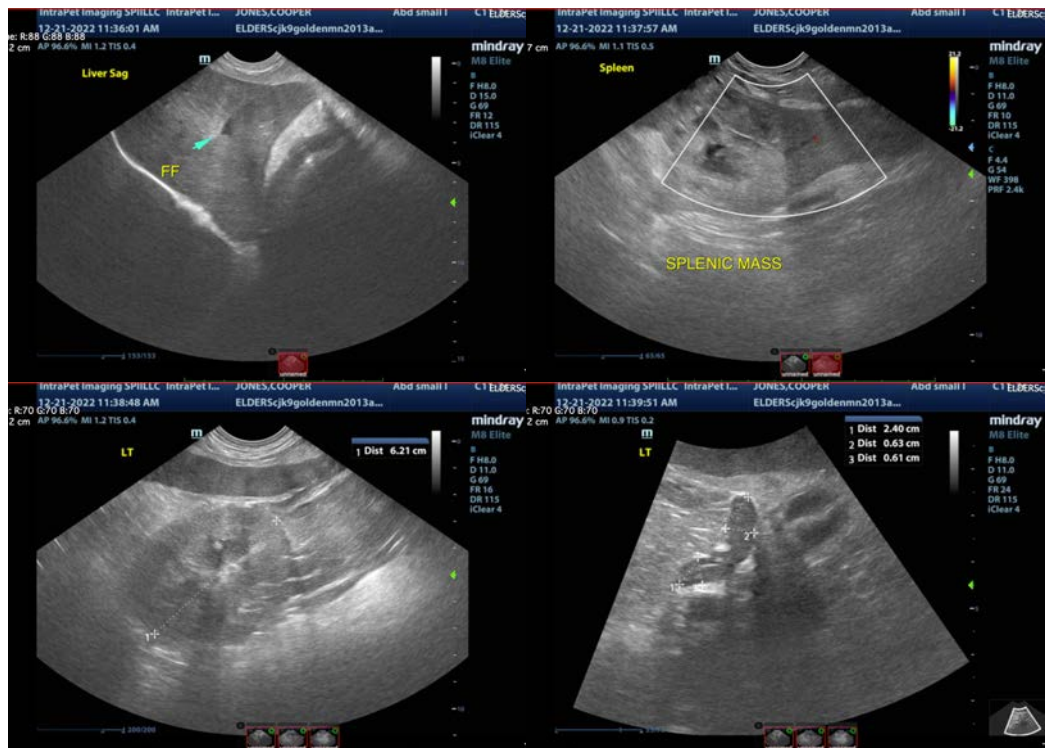
- Small volume free abdominal fluid – I'm concerned this could be hemorrhage. Recommend sampling.

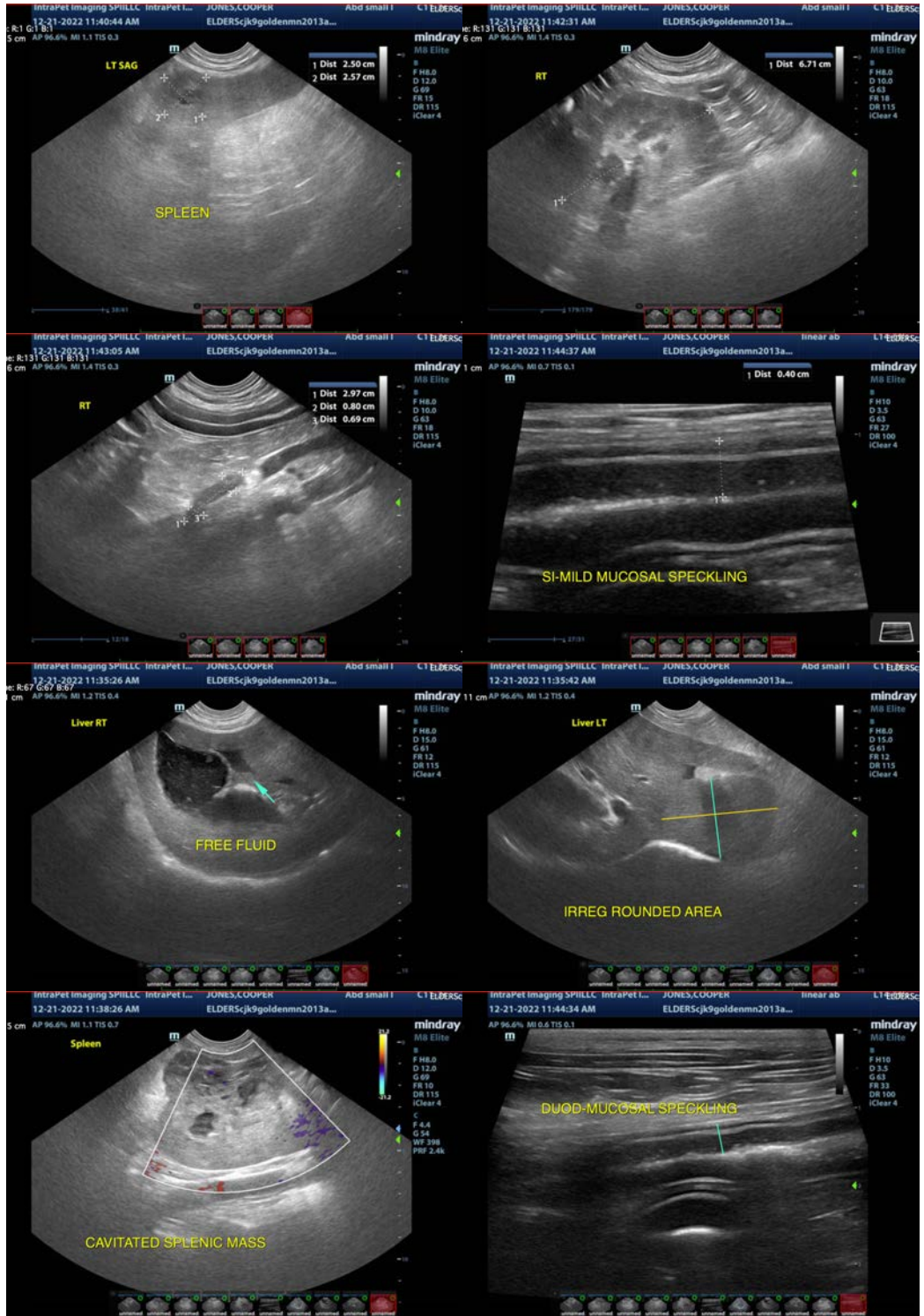
INTERPRETATION OF THE FINDINGS & FURTHER RECOMMENDATIONS

There is a large, hyperechoic, cavitated splenic mass with surrounding inflammation and free abdominal fluid. There is concern for the possibility of intermittent hemorrhage. Recommend a splenectomy for both diagnostic and therapeutic purposes, if 3-view thoracic radiographs appear normal.

There is a rounded region of the left liver that looks somewhat irregular. Consider gross evaluation of this area at the time of surgery and possible biopsy. This could be an atypical, rounded liver lobe, or if it is a mass effect, it would be most consistent with a primary hepatic mass lesion and could represent a slow growing benign lesion.

If there is a longstanding history of gastrointestinal signs with this patient, GI biopsies could be considered to further evaluate the mucosal speckling observed. Otherwise, I would consider this an incidental finding.





The information and recommendations provided are based on the images presented by the referring veterinarian/sonographer. No evaluation can be communicated regarding pathology that was not visible in the image/video clips provided.

Thank you for this referral. If the clinical or image interpretation does not parallel your findings or if I can be of any further assistance please contact me.

Kathleen Sennello DVM,MS, Diplomate ACVIM (Small animal Internal Medicine)
kathleen.sennello@sonopath.com