



**PATIENT**

Sadie Curtis

**SPECIES**

Canine

**BREED**

German Shepherd

**SEX**

Intact Female

**AGE**

~4 Years

**WEIGHT**

65.8 Pounds

**INTERPRETED BY**

Kathleen Sennello DVM,  
MS, Diplomate ACVIM  
(Small Animal Internal  
Medicine)

**IMAGING  
PERFORMED BY**

Kelly Vazquez

**HOSPITAL NAME**

Millburn Vet Hospital

**REFERRING VET**

Dr. Turowsky

**INVOICE**

43557

**DATE**

12/20/22

**PRESENTING CLINICAL SIGNS**

Patient who was adopted about 4-5 months ago presents for several day history of whining/restlessness and inappetence, radiographs were concerning for splenomegaly. No current meds, bloods pending.

**ULTRASONOGRAPHIC EXAMINATION OF THE ABDOMEN**

**Urinary System**

The urinary bladder is moderately distended with anechoic urine. The Bladder wall, trigone, ureteral papillae and visible urethra (to a depth of 2cm) appear normal with no evidence of wall thickening, mucosal irregularities, masses or cystic calculi.

The left kidney has a normal shape and size (6.42 cm). Overall echogenicity is normal with adequate corticomedullary distinction and a typical 1:3 cortex:medulla ratio. There is no evidence of focal perinephric inflammation or effusion. There is no evidence of pyelectasia, nephroliths, infarcts or hydroureter. Renal vasculature is normal.

The right kidney has a normal shape and size (5.03 cm). Overall echogenicity is normal with adequate corticomedullary distinction and a typical 1:3 cortex:medulla ratio. There is no evidence of focal perinephric inflammation or effusion. There is no evidence of pyelectasia, nephroliths, infarcts or hydroureter. Renal vasculature is normal.

**Adrenal Glands**

The left adrenal gland is normal in size measuring 0.41 cm at the caudal pole. It is observed in its normal position cranial to the left renal artery. It is normal in appearance (uniformly hypoechoic) and shape with no evidence of a mass effect.

The right adrenal gland is normal in size measuring 0.53 cm at the caudal pole. It is observed in its normal position between the cranial aspect of the right kidney and the caudal vena cava. It is normal in appearance (uniformly hypoechoic) and shape with no evidence of a mass effect.

**Spleen**

The spleen is normal/borderline large, echotexture is homogenous, and the splenic capsule is smooth with no irregularities. The blood flow through the hilus and splenic parenchyma appears normal. No focal parenchymal abnormalities are visualized.

**Liver**

The liver is subjectively normal in size, and echogenicity with smooth peripheral margins. The parenchyma is homogenous echotexture. The visible portions of the vasculature and biliary tract appear normal. No focal nodules or cystic lesions are observed.

The gallbladder lumen is moderately distended. The wall of the gall bladder is not thickened and has a smooth mucosal surface. Luminal contents are mild and primarily anechoic. The cystic and common bile ducts are normal/not visible.

**Gastrointestinal**

The stomach contains minimal luminal contents. It measures at a normal thickness of <0.7cm with some variability due to the presence of rugal folds. The distinction of the gastric wall layers is adequate and there is no impression of reduced peristaltic activity. No masses or focal lesions were observed.



**PATIENT**

Sadie Curtis

The visualized areas of duodenum, jejunum and ileum have a relatively uniform diameter with minimal fluid distension. Wall thickness is normal. Bowel loops follow a curvilinear path with distinct wall layering maintaining the typical 1:3 muscularis:mucosa layer ratio. The duodenum measured as normal (between 0.3-0.5cm in wall thickness) and the jejunum measured as normal (between 0.2-0.47cm.)

**SPECIES**

Canine

Visualized peristalsis appears appropriate. There were no focal lesions consistent with obstruction or a mass effect observed.

**BREED**

German Shepherd

The ileocecal junction was visualized and exhibited normal intact wall layering and is subjectively of normal thickness. Sections of colon are visualized with formed fecal material and gas shadowing distally. There is no observed focal or generalized colon wall thickening or loss of layering.

**Pancreas**

**SEX**

Intact Female

The pancreas is normal and isoechoic to surrounding mesentery. There is no evidence of nodules or cystic lesions. There is no evidence of regional mesenteric inflammation or fluid.

**Free Abdomen**

**AGE**

~4 Years

Evaluation of the peritoneal cavity did not reveal any evidence of effusion, or subjective lymphadenomegaly. The Medial iliac nodes appear normal and there was no evidence of a caudal aortic thrombus at the bifurcation. The omentum is of normal uniform echogenicity.

**Other**

**WEIGHT**

65.8 Pounds

The body of the uterus and the left ovary are visualized and appear within normal limits.

**ULTRASONOGRAPHIC FINDINGS**

- Subjectively large spleen – The spleen appears relatively normal and is likely within normal limits for this individual.

**INTERPRETED BY**

Kathleen Sennello DVM,  
MS, Diplomate ACVIM  
(Small Animal Internal  
Medicine)

**INTERPRETATION OF THE FINDINGS & FURTHER RECOMMENDATIONS**

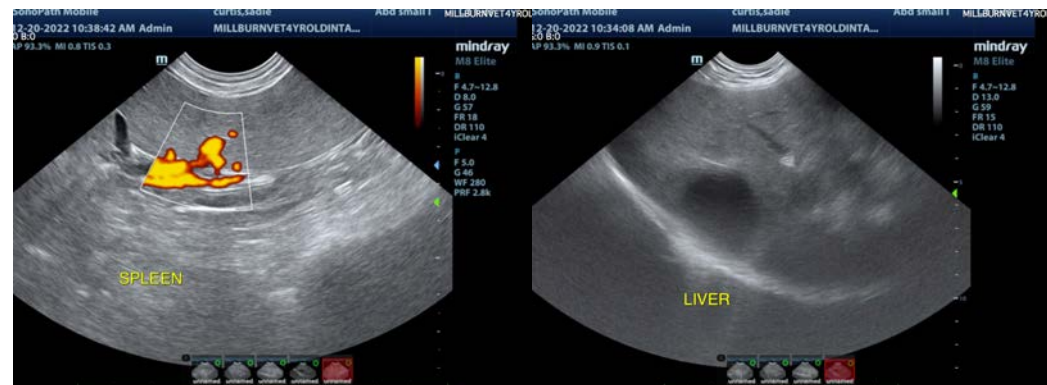No obvious source for the abnormal behavior is observed. The spleen is subjectively enlarged, but this can be normal for a German Shepherd, and in some areas, it does appear folded over upon itself. If no other source of illness is identified, a fine needle aspirate of the spleen could be considered to rule out round cell neoplasia, etc.

**IMAGING PERFORMED BY**

Kelly Vazquez

**HOSPITAL NAME**

Millburn Vet Hospital



**REFERRING VET**

Dr. Turowsky

**INVOICE**

43557

**DATE**

12/20/22



**PATIENT**

Sadie Curtis

**SPECIES**

Canine

**BREED**

German Shepherd

**SEX**

Intact Female

**AGE**

~4 Years

**WEIGHT**

65.8 Pounds

**INTERPRETED BY**

Kathleen Sennello DVM,  
MS, Diplomate ACVIM  
(Small Animal Internal  
Medicine)

**IMAGING  
PERFORMED BY**

Kelly Vazquez

**HOSPITAL NAME**

Millburn Vet Hospital

**REFERRING VET**

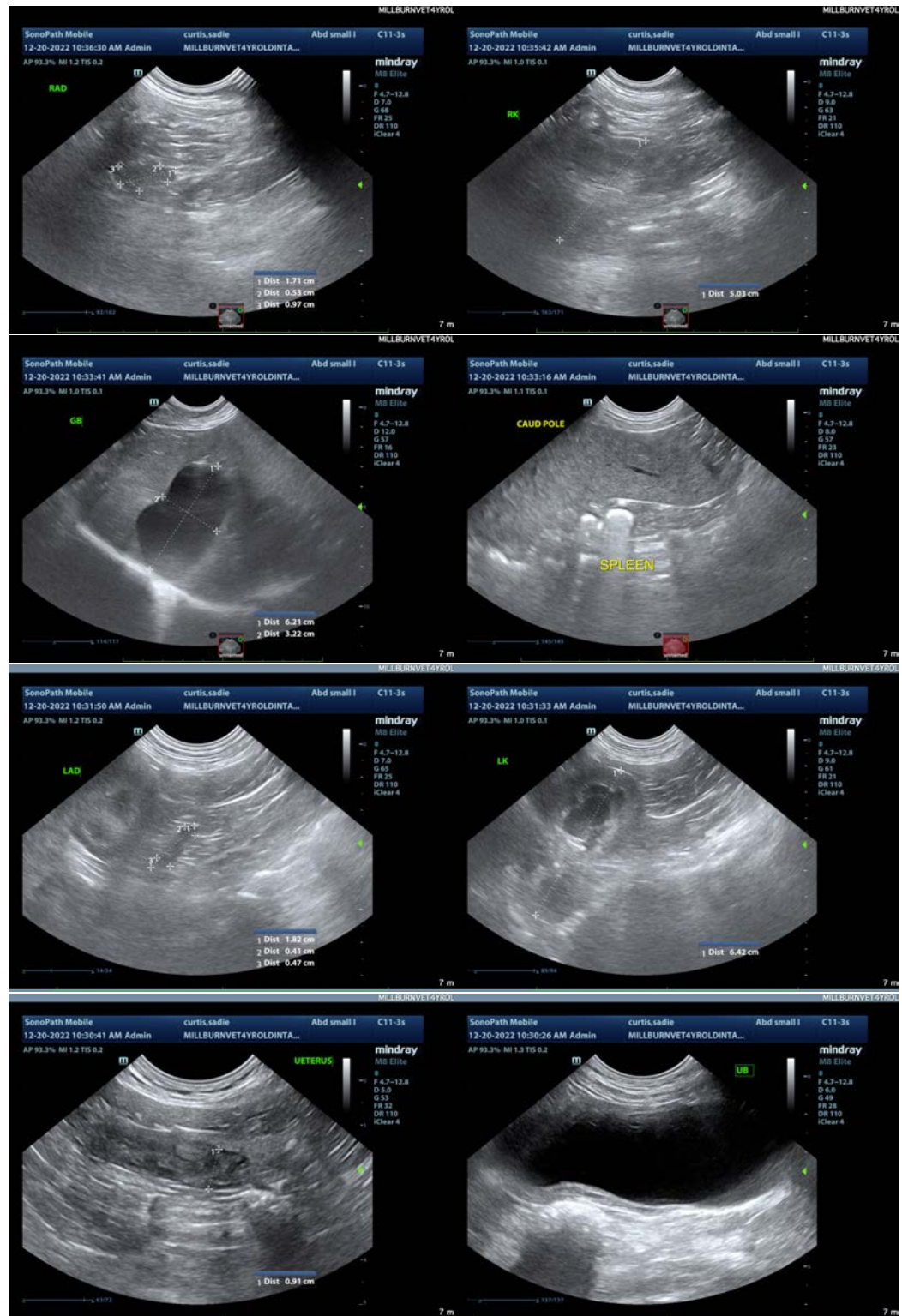
Dr. Turowsky

**INVOICE**

43557

**DATE**

12/20/22





**PATIENT**

Sadie Curtis

The information and recommendations provided are based on the images presented by the referring veterinarian/sonographer. No evaluation can be communicated regarding pathology that was not visible in the image/video clips provided.

**SPECIES**

Canine

Thank you for this referral. If the clinical or image interpretation does not parallel your findings or if I can be of any further assistance please contact me.

Kathleen Sennello DVM,MS, Diplomate ACVIM (Small animal Internal Medicine)

**BREED**

German Shepherd

kathleen.sennello@sonopath.com

**SEX**

Intact Female

**AGE**

~4 Years

**WEIGHT**

65.8 Pounds

**INTERPRETED BY**

Kathleen Sennello DVM,  
MS, Diplomate ACVIM  
(Small Animal Internal  
Medicine)

**IMAGING  
PERFORMED BY**

Kelly Vazquez

**HOSPITAL NAME**

Millburn Vet Hospital

**REFERRING VET**

Dr. Turowsky

**INVOICE**

43557

**DATE**

12/20/22