

IMAGING PERFORMED BY

SVS Mobile Imaging MI 734-637-7711
svsimagingmi@gmail.com



EDUCATIONAL TELECONSULTATION SERVICES™
1-800-838-4268 info@sonopath.com SonoPath.com

PATIENT

Lily Bonahoom

SPECIES

Feline

BREED

DSH

SEX

Spayed Female

AGE

11 Years

WEIGHT

8.81 Pounds

INTERPRETED BY

Kathleen Sennello DVM,
MS, Diplomate ACVIM
(Small Animal Internal
Medicine)

IMAGING PERFORMED BY

Amy Mayhew, LVT

HOSPITAL NAME

SVS Imaging MI

REFERRING VET

Family Pet Practice

INVOICE

43555

DATE

12/20/22

PRESENTING CLINICAL SIGNS

Current Medications: RC USO Revolution Patient History: AUS on 12/20/22. Hx of chronic pancreatitis. Chronic kidney changes. AUS and IH CHP performed 4/14/22. Gabapentin and Butorphanol used during 4/14/22 AUS. Previous AUS 8/3/21. 1 lb weight loss since April 2022.

Abnormal PE/Chem/CBC/UA Results: 4/16/22: Chronic pancreatitis. Decreased appetite and weight loss. Evidence of chronic kidney changes with possible scar tissue developing at her left kidney. Dental disease. Consider GI panel. 4/28/22: Dental performed. 1 tooth extracted.

ULTRASONOGRAPHIC EXAMINATION OF THE ABDOMEN**Urinary System**

The urinary bladder is moderately distended with anechoic urine. The Bladder wall, trigone, ureteral papillae and visible urethra (to a depth of 2cm) appear normal with no evidence of wall thickening, mucosal irregularities, masses or cystic calculi.

The left kidney has a normal shape and size (3.34 cm). Overall echogenicity is increased with a prominent, hyperechoic, somewhat thickened cortex, which contains some patchy, hypoechoic regions, and a contrasting hypoechoic medulla. There is no evidence of focal perinephric inflammation or effusion. There is no evidence of pyelectasia, nephroliths, or hydroureter. The hypoechoic regions could represent early infarcts or less likely infiltrative disease. Renal vasculature is normal.

The right kidney has a normal shape and size (4.08 cm). Overall echogenicity is increased with a prominent, hyperechoic, somewhat thickened cortex, and a contrasting hypoechoic medulla. There is no evidence of focal perinephric inflammation or effusion. There is no evidence of pyelectasia, nephroliths, infarcts or hydroureter. Renal vasculature is normal.

Adrenal Glands

The left adrenal gland is normal in size measuring 0.40 cm at the caudal pole. It is observed in its normal position cranial to the left renal artery. It is normal in appearance (uniformly hypoechoic) and shape with no evidence of a mass effect.

The right adrenal gland is normal in size measuring 0.44 cm at the caudal pole. It is observed in its normal position between the cranial aspect of the right kidney and the caudal vena cava. It is normal in appearance (uniformly hypoechoic) and shape with no evidence of a mass effect.

Spleen

The spleen is subjectively normal in size (0.97 cm), echotexture is homogenous, and the splenic capsule is smooth with no irregularities. The blood flow through the hilus and splenic parenchyma appears normal. No focal parenchymal abnormalities are visualized.

Liver

The liver is subjectively normal in size, and echogenicity with smooth peripheral margins. The parenchyma is homogenous echotexture. The visible portions of the vasculature and biliary tract appear normal. No focal nodules or cystic lesions are observed.

The gallbladder lumen is moderately distended. The wall of the gall bladder is not thickened and has a smooth mucosal surface. Luminal contents are mild and primarily anechoic. The cystic and common bile duct appear somewhat dilated and tortuous measuring 0.49 cm.

IMAGING PERFORMED BY

SVS Mobile Imaging MI 734 - 637 - 7711
svsimagingmi@gmail.com



EDUCATIONAL TELECONSULTATION SERVICES™
1-800-838-4268 info@sonopath.com SonoPath.com

PATIENT

Lily Bonahoom

SPECIES

Feline

BREED

DSH

SEX

Spayed Female

AGE

11 Years

WEIGHT

8.81 Pounds

INTERPRETED BY

Kathleen Sennello DVM,
MS, Diplomate ACVIM
(Small Animal Internal
Medicine)

IMAGING PERFORMED BY

Amy Mayhew, LVT

HOSPITAL NAME

SVS Imaging MI

REFERRING VET

Family Pet Practice

INVOICE

43555

DATE

12/20/22

Gastrointestinal

The stomach contains minimal luminal contents. It measures at a normal thickness of <0.36cm with some variability due to the presence of rugal folds. The distinction of the gastric wall layers is adequate and there is no impression of reduced peristaltic activity. No masses or focal lesions were observed.

The visualized areas of duodenum, jejunum and ileum have a relatively uniform diameter with minimal fluid distension. Wall thickness is normal. Bowel loops follow a curvilinear path with distinct wall layering maintaining the typical 1:3 muscularis:mucosa layer ratio. Duodenum wall measures 0.27 cm. Jejunum wall measures 0.20 cm. Visualized peristalsis appears appropriate. There were no focal lesions consistent with obstruction or a mass effect observed.

The ileocecal junction was visualized and exhibited normal intact wall layering and is subjectively of normal thickness. Sections of colon are visualized with formed fecal material and gas shadowing distally. There is no observed focal or generalized colon wall thickening or loss of layering. Colon wall measures at 0.17 cm in thickness.

Pancreas

The pancreas is prominent and mottled compared to the surrounding isoechoic mesentery. There is no evidence of nodules or cystic lesions. There is no evidence of regional mesenteric inflammation or fluid.

Free Abdomen

Evaluation of the peritoneal cavity did not reveal any evidence of effusion, or subjective lymphadenomegaly. The Medial iliac nodes appear normal and there was no evidence of a caudal aortic thrombus at the bifurcation. The omentum is of normal uniform echogenicity.

ULTRASONOGRAPHIC FINDINGS

- Hyperechoic kidneys with comparatively hypoechoic medullas and some patchy hypoechoic cortical areas in the left kidney – These changes are non-specific and likely correlate with chronic renal disease (interstitial nephritis?). The hypoechoic regions of the left kidney could be consistent with infarcts. Recommend continued monitoring.
- Prominent, mottled pancreas – The pancreatic changes are most consistent with age-related parenchymal remodeling, potentially secondary to a prior inflammatory episode, early fibrosis or chronic pancreatitis. The pancreas appears similar to the previous scan 4/14/22, and this likely represents chronic remodeling.
- Mildly dilated and tortuous bile duct – Dilation of the common bile duct could be consistent with a functional obstruction (i.e. primary hepatic disease resulting in hepatocellular swelling) or with an extrahepatic bile duct obstruction (ie. choledocholith, bile duct tumor, pancreatic disease, other). Previous measurements 4/14/22 were at 0.40 cm. This appears stable to the previous scan.

INTERPRETATION OF THE FINDINGS & FURTHER RECOMMENDATIONS

There are non-specific changes reported associated with both kidneys, which I suspect are associated with chronic progressive age related renal disease. On today's scan, there are some hypoechoic, irregular regions visualized in the cortex of the left kidney. These are non-specific but could represent recently infarcted areas. Recommend continued monitoring, as I cannot definitively rule out an early infiltrative lesion. If not already done, baseline evaluation would include a blood pressure, urine protein to creatinine ratio, urinalysis and culture.

IMAGING PERFORMED BY

SVS Mobile Imaging MI 734-637-7711
svsimagingmi@gmail.com



Clinical Sonography & Telecytology

EDUCATIONAL TELECONSULTATION SERVICES™

1-800-838-4268 info@sonopath.com SonoPath.com

PATIENT

Lily Bonahoom

SPECIES

Feline

BREED

DSH

SEX

Spayed Female

AGE

11 Years

WEIGHT

8.81 Pounds

INTERPRETED BY

Kathleen Sennello DVM,
MS, Diplomate ACVIM
(Small Animal Internal
Medicine)

IMAGING PERFORMED BY

Amy Mayhew, LVT

HOSPITAL NAME

SVS Imaging MI

REFERRING VET

Family Pet Practice

INVOICE

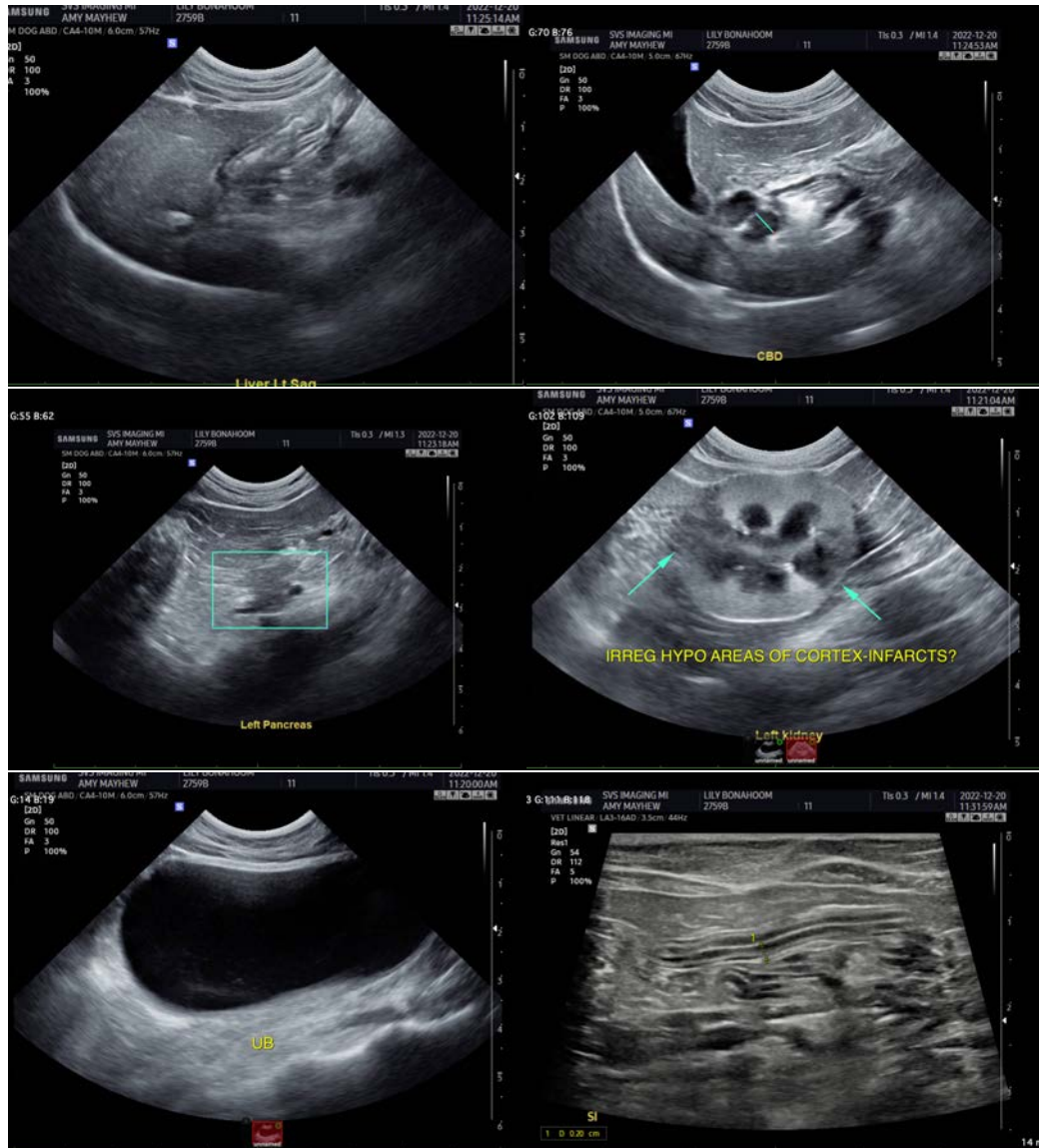
43555

DATE

12/20/22

The pancreas is slightly prominent and appears somewhat mottled. Given that similar changes were described in the previous scan on 4/14/22, I suspect these changes represent chronic remodeling. Correlate with a quantitative fPLI measurement if a recent flare up is suspected.

The bile duct appears somewhat tortuous and dilated. This can be an incidental finding in some older cats. It does not appear to be progressing significantly. Correlate findings with current liver enzyme evaluations to look for any evidence of cholestasis.



IMAGING PERFORMED BY

SVS Mobile Imaging MI 734 - 637 - 7711
svsimagingmi@gmail.com



PATIENT

Lily Bonahoom

SPECIES

Feline

BREED

DSH

SEX

Spayed Female

AGE

11 Years

WEIGHT

8.81 Pounds

INTERPRETED BY

Kathleen Sennello DVM,
MS, Diplomate ACVIM
(Small Animal Internal
Medicine)

**IMAGING
PERFORMED BY**

Amy Mayhew, LVT

HOSPITAL NAME

SVS Imaging MI

REFERRING VET

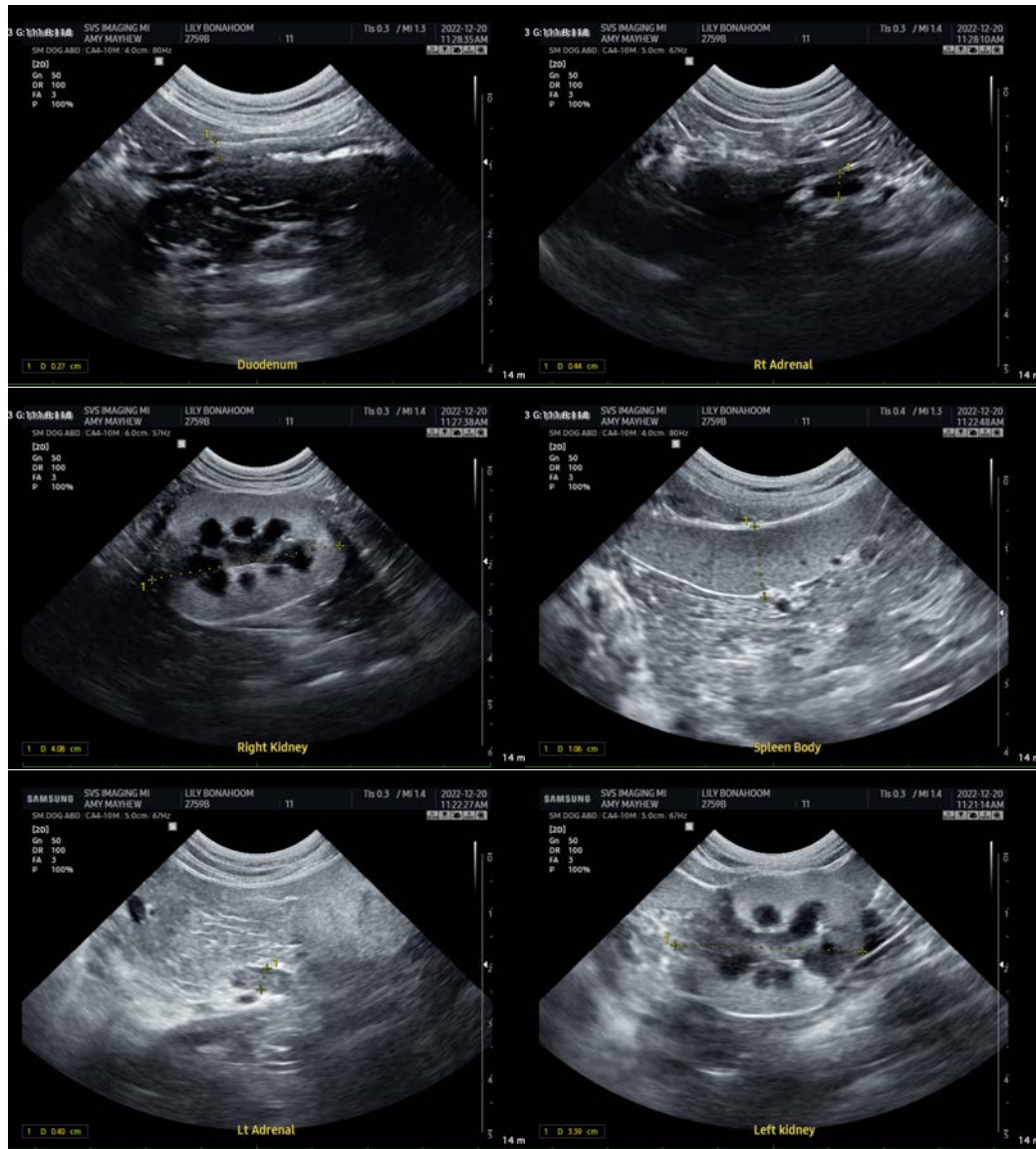
Family Pet Practice

INVOICE

43555

DATE

12/20/22



The information and recommendations provided are based on the images presented by the referring veterinarian/sonographer. No evaluation can be communicated regarding pathology that was not visible in the image/video clips provided.

Thank you for this referral. If the clinical or image interpretation does not parallel your findings or if I can be of any further assistance please contact me.

Kathleen Sennello DVM,MS, Diplomate ACVIM (Small animal Internal Medicine)

kathleen.sennello@sonopath.com