



PATIENT

Amelia Strong

SPECIES

Feline

BREED

Russian Blue

SEX

Spayed Female

AGE

6 years

WEIGHT

12.8 lbs

INTERPRETED BY

Kathleen Sennello DVM,
MS, Diplomate ACVIM
(Small Animal Internal
Medicine)

**IMAGING
PERFORMED BY**

Loetitia Saint-Jacques,
LVT

HOSPITAL NAME

South Reno Veterinary
Hospital

REFERRING VET

Dr. Schmitt

INVOICE

10846

DATE

12/2/2025

PRESENTING CLINICAL SIGNS

On 11/11/2025- CBC: Slight increased eosinophils. Slight decreased MCV. Slight decrease platelets likely clumped a machine error and appears to be insignificant at this time. Chemistry screen: Within normal limits Thoracic x-rays: Cardiac and pulmonary structures are unremarkable. Musculoskeletal structures are unremarkable. Abdominal x-rays: Small intestine normally dilated throughout with a mixed pattern of gas and ingesta. Large intestine has pocket of gas in descending colon with feces orad to it. Normally dilated throughout. Stomach is mildly distended with material. Urinary bladder is slightly distended. What is seen of kidneys liver and spleen are unremarkable. Musculoskeletal structures are unremarkable. A: Patient has vomited frequently, and owner has noted food in it. Concern for possible foreign material in stomach. as Cat eats carpet- Decreased appetite. RAD report concern for FB or pancreatitis. Patient was admitted to ER- and hospitalized overnight on IVF- 11/13/2025- P is not eating, drinking and no vomiting or diarrhea. Vomit once hairball. An ultrasound was recommended. 12/2/2025- doing well, AUS to follow up for previous pancreatitis. No FB was found in previous ER visit.

ULTRASONOGRAPHIC EXAMINATION OF THE ABDOMEN

Urinary System

The urinary bladder is moderately distended with dependent echogenic debris present. The Bladder wall, trigone, ureteral papillae and visible urethra (to a depth of 2cm) appear normal with no evidence of wall thickening, mucosal irregularities, masses or calculi. Echogenic debris of this type can be associated with small crystals, cellular debris and proteinaceous debris.

The left kidney has a normal shape and size (4.06 cm). Overall echogenicity is normal with adequate corticomedullary distinction and a typical 1:3 cortex:medulla ratio. There is no evidence of focal perinephric inflammation or effusion. There is no evidence of pyelectasia, nephroliths, infarcts or hydroureter. Renal vasculature is normal.

The right kidney has a normal shape and size (4.29 cm). There are hyperechoic regions of the cortex, most consistent with previous infarcts, particularly in the cranial pole. The corticomedullary distinction is adequate with a typical 1:3 cortex:medulla ratio. There is no evidence of focal perinephric inflammation or effusion. There is no evidence of pyelectasia, nephroliths or hydroureter. Renal vasculature is normal.

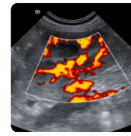
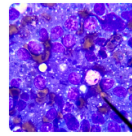
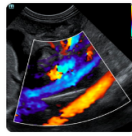
Adrenal Glands

The left adrenal gland is normal in size measuring 0.36 cm at the caudal pole. It is observed in its normal position cranial to the left renal artery. It is normal in appearance (uniformly hypoechoic) and shape with no evidence of a mass effect.

The right adrenal gland is normal in size measuring 0.39 cm at the caudal pole. It is observed in its normal position between the cranial aspect of the right kidney and the caudal vena cava. It is normal in appearance (uniformly hypoechoic) and shape with no evidence of a mass effect.

Spleen

The spleen is subjectively normal in size (0.94 cm), echotexture is homogenous, and the splenic capsule is smooth with no irregularities. The blood flow through the hilus and splenic parenchyma appears normal. No focal parenchymal abnormalities are visualized.



PATIENT

Amelia Strong

SPECIES

Feline

BREED

Russian Blue

SEX

Spayed Female

AGE

6 years

WEIGHT

12.8 lbs

INTERPRETED BY

Kathleen Sennello DVM,
MS, Diplomate ACVIM
(Small Animal Internal
Medicine)

**IMAGING
PERFORMED BY**

Loetitia Saint-Jacques,
LVT

HOSPITAL NAME

South Reno Veterinary
Hospital

REFERRING VET

Dr. Schmitt

INVOICE

10846

DATE

12/2/2025

Liver

The liver is subjectively normal in size, and echogenicity with smooth peripheral margins. The parenchyma is homogenous echotexture. The visible portions of the vasculature and biliary tract appear normal. No focal nodules or cystic lesions are observed.

The gall bladder lumen is moderately distended. The wall of the gall bladder is not thickened and has a smooth mucosal surface. Luminal contents are mild and likely incidental at this time. The cystic and common bile ducts are normal/not visible.

Gastrointestinal

The stomach contains minimal luminal contents. It measures at a normal thickness of <0.36cm with some variability due to the presence of rugal folds. The distinction of the gastric wall layers is adequate and there is no impression of reduced peristaltic activity. No masses or focal lesions were observed.

The visualized areas of duodenum, jejunum and ileum have a relatively uniform diameter with minimal fluid distension. Wall thickness is normal. Bowel loops follow a curvilinear path with distinct wall layering maintaining the typical 1:3 muscularis:mucosa layer ratio. The duodenum measured as normal (0.27 cm in wall thickness) and the jejunum measured as normal (0.22 cm.) Visualized peristalsis appears appropriate. There were no focal lesions consistent with obstruction or a mass effect observed.

The ileocecal junction was visualized and exhibited normal intact wall layering and is subjectively of normal thickness. Sections of colon are visualized with formed fecal material and gas shadowing distally. There is no observed focal or generalized colon wall thickening or loss of layering.

Pancreas

The pancreas is prominent and mottled in the region of the body. There is no evidence of nodules or cystic lesions. There is no evidence of regional mesenteric inflammation or fluid.

Free Abdomen

Evaluation of the peritoneal cavity did not reveal any evidence of effusion, or subjective lymphadenomegaly. The Medial iliac nodes appear normal and there was no evidence of a caudal aortic thrombus at the bifurcation. The omentum is of normal uniform echogenicity.

ULTRASONOGRAPHIC FINDINGS

- Pancreatic changes most consistent with chronic pancreatic remodeling +/- mild chronic pancreatitis/resolving pancreatitis.
- Evidence of previous renal infarcts in the right kidney. The solitary renal lesion identified is ill defined and hyperechoic, this could be consistent with a previous renal infarct and can be an indicator of current or previous renal disease

INTERPRETATION OF THE FINDINGS & FURTHER RECOMMENDATIONS

The body of the pancreas is somewhat prominent and mottled with minimal surrounding inflammation. Findings are most consistent with pancreatic remodeling/resolving pancreatitis.



PATIENT

Amelia Strong

SPECIES

Feline

BREED

Russian Blue

SEX

Spayed Female

AGE

6 years

WEIGHT

12.8 lbs

INTERPRETED BY

Kathleen Sennello DVM,
MS, Diplomate ACVIM
(Small Animal Internal
Medicine)

IMAGING PERFORMED BY

Loetitia Saint-Jacques,
LVT

HOSPITAL NAME

South Reno Veterinary
Hospital

REFERRING VET

Dr. Schmitt

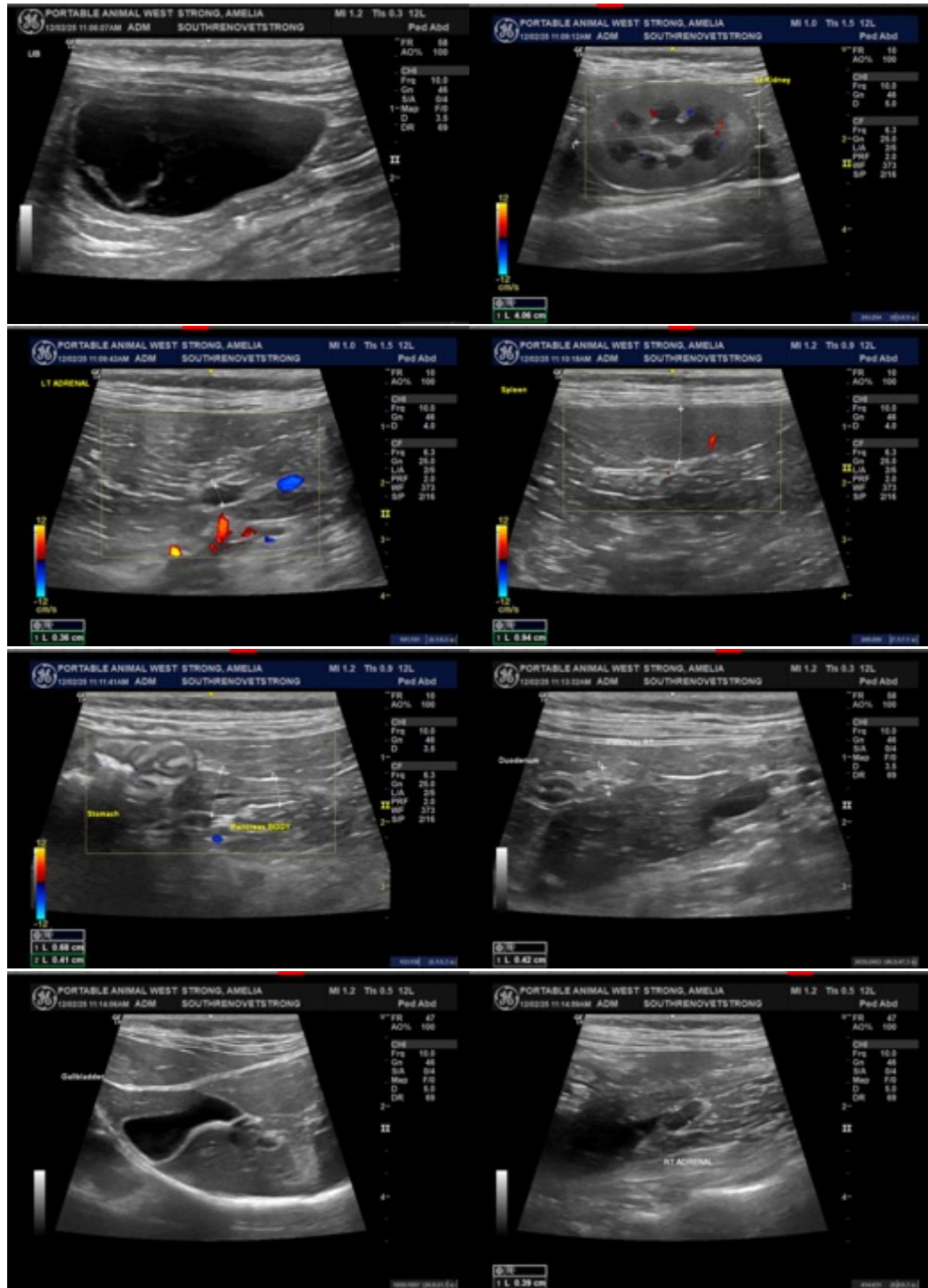
INVOICE

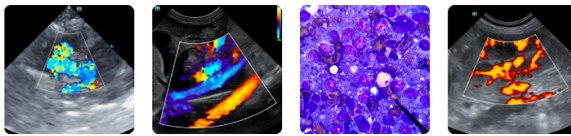
10846

DATE

12/2/2025

There's mild dependent echogenic debris in the urinary bladder and evidence of previous infarcts in the right kidney. Correlate with renal values, urinalysis results, etc.





PATIENT

Amelia Strong

SPECIES

Feline

BREED

Russian Blue

SEX

Spayed Female

AGE

6 years

WEIGHT

12.8 lbs

INTERPRETED BY

Kathleen Sennello DVM,
MS, Diplomate ACVIM
(Small Animal Internal
Medicine)

IMAGING PERFORMED BY

Loetitia Saint-Jacques,
LVT

HOSPITAL NAME

South Reno Veterinary
Hospital

REFERRING VET

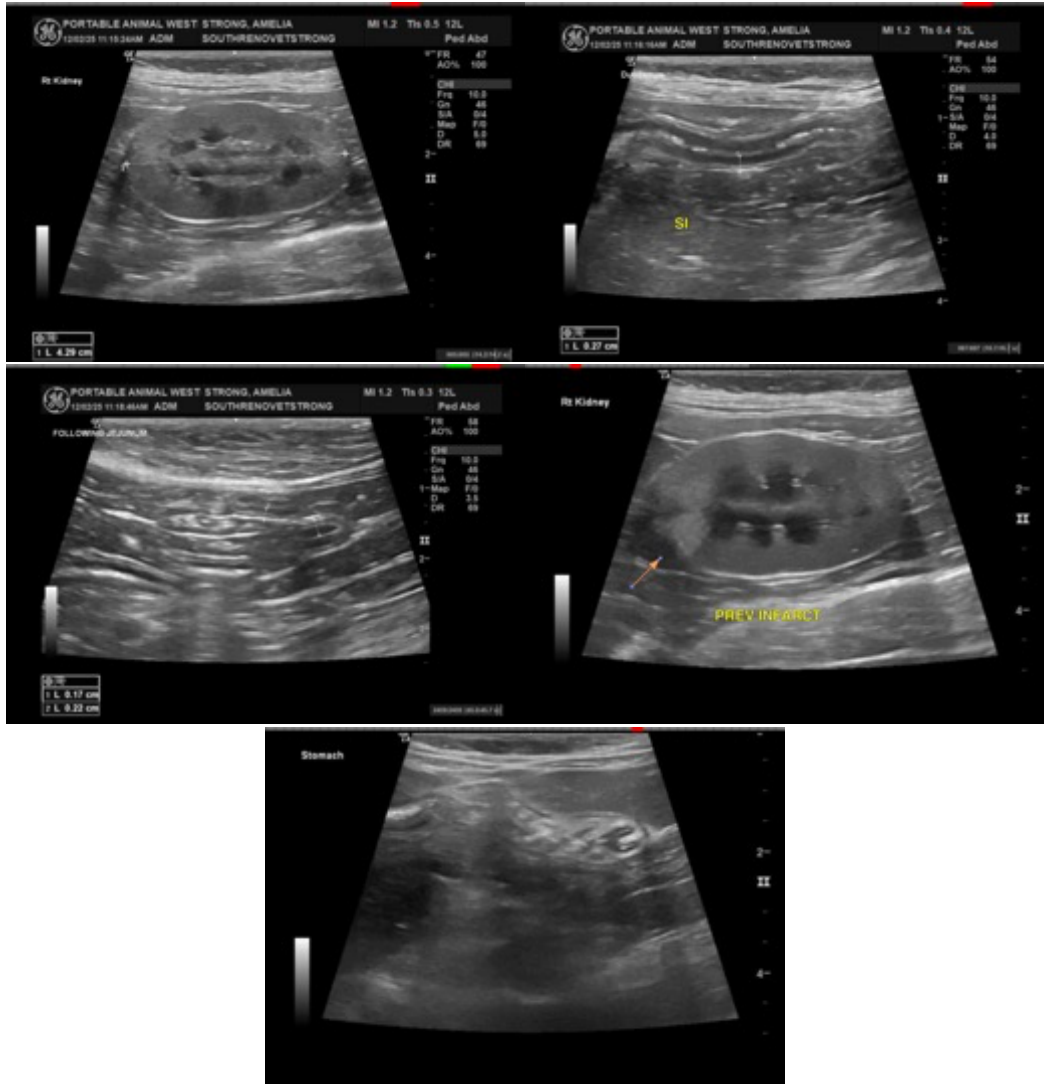
Dr. Schmitt

INVOICE

10846

DATE

12/2/2025



The information and recommendations provided are based on the images presented by the referring veterinarian/sonographer. No evaluation can be communicated regarding pathology that was not visible in the image/video clips provided.

Thank you for this referral. If the clinical or image interpretation does not parallel your findings or if I can be of any further assistance please contact me.

Kathleen Sennello DVM,MS, Diplomate ACVIM (Small animal Internal Medicine)

info@sonopath.com