

**PATIENT**

Rudy Pickett

**SPECIES**

Canine

**BREED**

Lab

**SEX**

Neutered Male

**AGE**

4 Years

**WEIGHT**

82.6 lbs

**INTERPRETED BY**

Kathleen Sennello DVM,  
 MS, Diplomate ACVIM  
 (Small Animal Internal  
 Medicine)

**IMAGING PERFORMED BY**

Kathleen Byrnes

**HOSPITAL NAME**

Shallowford Animal  
 Hospital

**REFERRING VET**

Dr. Eads

**INVOICE**

72677

**DATE**

12/18/25

**PRESENTING CLINICAL SIGNS**

P presented for US due to coughing and gagging a lot, otherwise normal Rads showed increased opacity on spleen CBC/Chem/T4 wnl, 2 rads attached.

Abnormal PE/Chem/CBC/UA Results: usg 1.035, trace protein, WBC 4-10, RBC 11-20, squamous epith 4-10

**ULTRASONOGRAPHIC EXAMINATION OF THE ABDOMEN**

**Urinary System**

The urinary bladder is moderately distended with anechoic urine. The Bladder wall, trigone, ureteral papillae and visible urethra (to a depth of 2cm) appear normal with no evidence of wall thickening, mucosal irregularities, masses or cystic calculi.

The prostate is normal in size (0.80 cm) and shape for this neutered male dog. The parenchyma is homogenous and the external margins are smooth. The prostatic urethra appears normal with no evidence of irregularity, invasion, mass effect or calculi.

The left kidney has a normal shape and size (6.83 cm). Overall echogenicity is normal with adequate corticomedullary distinction and a typical 1:3 cortex:medulla ratio. There is no evidence of focal perinephric inflammation or effusion. There is no evidence of pyelectasia, nephroliths, infarcts or hydroureter. Renal vasculature is normal.

The right kidney has a normal shape and size (7.3 cm). Overall echogenicity is normal with adequate corticomedullary distinction and a typical 1:3 cortex:medulla ratio. There is no evidence of focal perinephric inflammation or effusion. There is no evidence of pyelectasia, nephroliths, infarcts or hydroureter. Renal vasculature is normal.

**Adrenal Glands**

The left adrenal gland is normal in size measuring 0.46 cm at the cranial pole and 0.40 cm at the caudal pole. It is observed in its normal position cranial to the left renal artery. It is normal in appearance (uniformly hypoechoic) and shape with no evidence of a mass effect.

The right adrenal gland is normal in size measuring 0.95 cm at the cranial pole and 0.40 cm at the caudal pole. It is observed in its normal position between the cranial aspect of the right kidney and the caudal vena cava. It is normal in appearance (uniformly hypoechoic) and shape with no evidence of a mass effect.

**Spleen**

The spleen is normal in size (1.94 cm) but slightly irregular in shape. The blood flow through the hilus and splenic parenchyma appears normal. There is a subtle isoechoic “bulge” visualized at the level of the hilus measuring approximately 1.14 cm.

**Liver**

The liver is subjectively normal in size, and echogenicity with smooth peripheral margins. The parenchyma is homogenous echotexture. The visible portions of the vasculature and biliary tract appear normal. No focal nodules or cystic lesions are observed.



**PATIENT**

Rudy Pickett

The gall bladder lumen is moderately distended. The wall of the gall bladder is not thickened and has a smooth mucosal surface. Luminal contents are mild and likely incidental at this time. The cystic and common bile ducts are normal/not visible.

**SPECIES**

Canine

***Gastrointestinal***

The stomach contains minimal luminal contents. It measures at a normal thickness of <0.7cm with some variability due to the presence of rugal folds. The distinction of the gastric wall layers is adequate and there is no impression of reduced peristaltic activity. No masses or focal lesions were observed.

**BREED**

Lab

The visualized areas of duodenum, jejunum and ileum have a relatively uniform diameter with minimal fluid distension. Wall thickness is normal. Bowel loops follow a curvilinear path with distinct wall layering maintaining the typical 1:3 muscularis:mucosa layer ratio. Duodenum wall measures 0.38 cm. Visualized peristalsis appears appropriate. There were no focal lesions consistent with obstruction or a mass effect observed.

**SEX**

Neutered Male

**AGE**

4 Years

The ileocecal junction was visualized and exhibited normal intact wall layering and is subjectively of normal thickness. Sections of colon are visualized with formed fecal material and gas shadowing distally. There is no observed focal or generalized colon wall thickening or loss of layering.

**WEIGHT**

82.6 lbs

***Pancreas***

The pancreas is normal and isoechoic to surrounding mesentery. There is no evidence of nodules or cystic lesions. There is no evidence of regional mesenteric inflammation or fluid.

**INTERPRETED BY**

Kathleen Sennello DVM,  
 MS, Diplomate ACVIM  
 (Small Animal Internal  
 Medicine)

***Free Abdomen***

Evaluation of the peritoneal cavity did not reveal any evidence of effusion, or subjective lymphadenomegaly. The Medial iliac nodes appear normal and there was no evidence of a caudal aortic thrombus at the bifurcation. The omentum is of normal uniform echogenicity.

**IMAGING PERFORMED BY**

Kathleen Byrnes

***Other***

The right auricle and pericardium were visualized and were unremarkable. No obvious pathology is visualized. If cardiac function evaluation is desired a full echocardiogram is warranted.

**HOSPITAL NAME**

Shallowford Animal  
 Hospital

**ULTRASONOGRAPHIC FINDINGS**

- Subtle isoechoic “bulge” visualized in the spleen – I suspect this represents normal anatomic variation. An early mass lesion cannot be ruled out.

**REFERRING VET**

Dr. Eads

**INTERPRETATION OF THE FINDINGS & FURTHER RECOMMENDATIONS**

The majority of today’s exam is normal. On some views of the spleen there is an isoechoic “bulge” near the hilus. I suspect this represents normal anatomic variation but continued monitoring of this region is warranted. If this “bulge” progresses, a fine needle aspirate should be considered.

**INVOICE**

72677

**DATE**

12/18/25



**PATIENT**

Rudy Pickett

**SPECIES**

Canine

**BREED**

Lab

**SEX**

Neutered Male

**AGE**

4 Years

**WEIGHT**

82.6 lbs

**INTERPRETED BY**

Kathleen Sennello DVM,  
 MS, Diplomate ACVIM  
 (Small Animal Internal  
 Medicine)

**IMAGING PERFORMED BY**

Kathleen Byrnes

**HOSPITAL NAME**

Shallowford Animal  
 Hospital

**REFERRING VET**

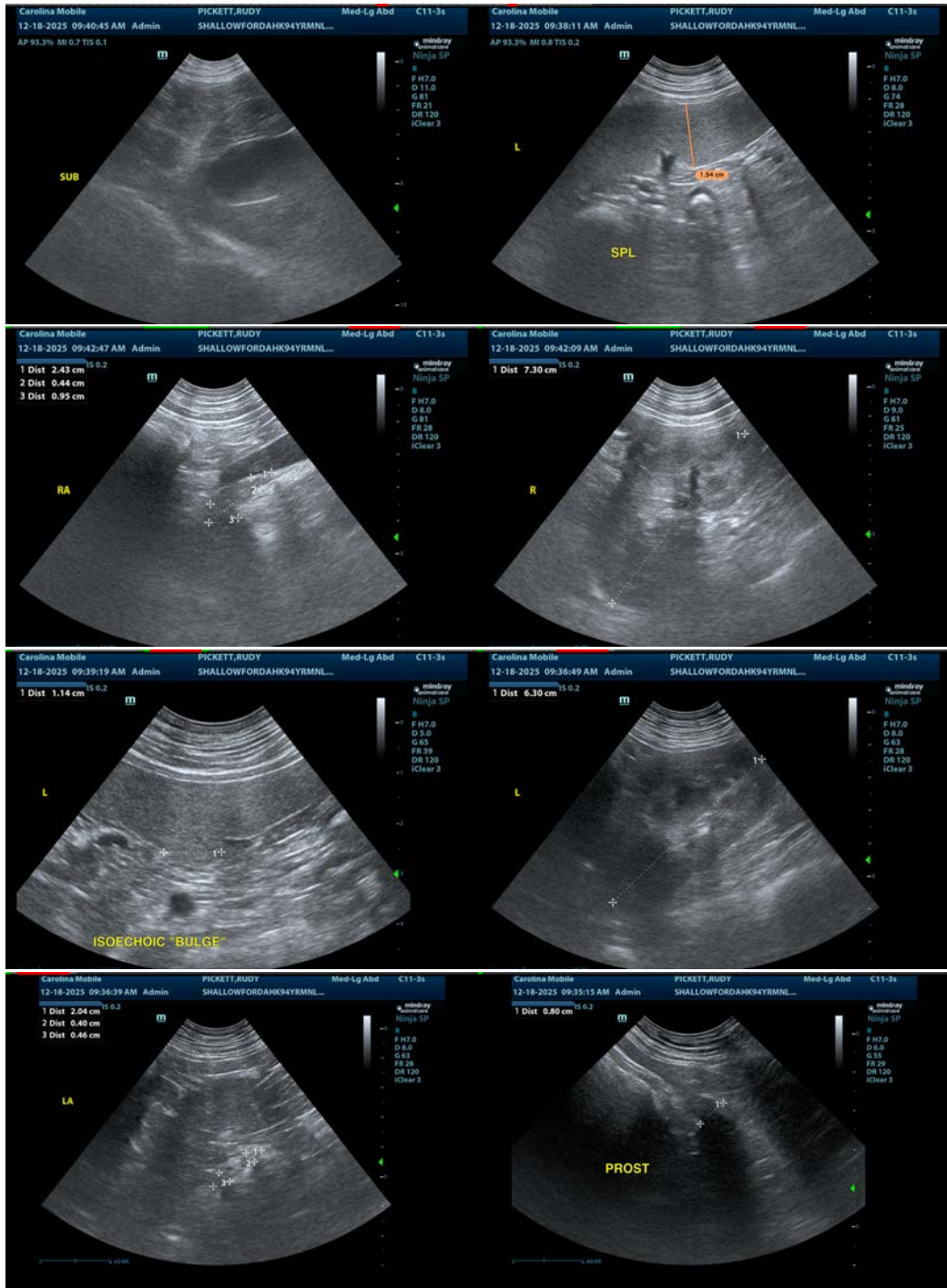
Dr. Eads

**INVOICE**

72677

**DATE**

12/18/25





**PATIENT**

Rudy Pickett

**SPECIES**

Canine

**BREED**

Lab

**SEX**

Neutered Male

**AGE**

4 Years

**WEIGHT**

82.6 lbs

**INTERPRETED BY**

Kathleen Sennello DVM,  
MS, Diplomate ACVIM  
(Small Animal Internal  
Medicine)

**IMAGING  
PERFORMED BY**

Kathleen Byrnes

**HOSPITAL NAME**

Shallowford Animal  
Hospital

**REFERRING VET**

Dr. Eads

**INVOICE**

72677

**DATE**

12/18/25

The information and recommendations provided are based on the images presented by the referring veterinarian/sonographer. No evaluation can be communicated regarding pathology that was not visible in the image/video clips provided.

Thank you for this referral. If the clinical or image interpretation does not parallel your findings or if I can be of any further assistance please contact me.

Kathleen Sennello DVM,MS, Diplomate ACVIM (Small animal Internal Medicine)

[info@sonopath.com](mailto:info@sonopath.com)