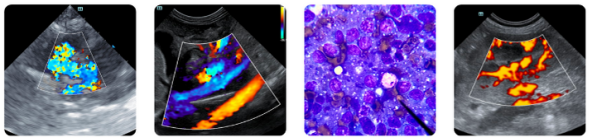

PATIENT
Emma Lou King

SPECIES
Feline

BREED
Siamese

SEX
Spayed Female

AGE
14 years

WEIGHT
11.8 lbs

INTERPRETED BY
Kathleen Sennello DVM, MS, Diplomate ACVIM (Small Animal Internal Medicine)

IMAGING PERFORMED BY
Dr. Brittany Wolfe

HOSPITAL NAME
Home Vets

REFERRING VET
Dr. Brittany Wolfe

INVOICE
10979

DATE
12/18/2025

PRESENTING CLINICAL SIGNS

P has a history of chronic diarrhea (for years). O reports P has never had normal BMs except when eating a brand of food called nom noms which is no longer made. Occasional vomiting, sometimes food, sometimes hairballs.

Abnormal PE/Chem/CBC/UA Results: P a little bloated on abdominal palpation. CBC/Chem/T4/BNP all normal.

ULTRASONOGRAPHIC EXAMINATION OF THE ABDOMEN

Urinary System

The urinary bladder is moderately distended with anechoic urine. The Bladder wall, trigone, ureteral papillae and visible urethra (to a depth of 2cm) appear normal with no evidence of wall thickening, mucosal irregularities, masses or cystic calculi.

The left kidney has a normal shape and size (3.47 cm). Overall echogenicity is normal with adequate corticomedullary distinction and a typical 1:3 cortex:medulla ratio. There is no evidence of focal perinephric inflammation or effusion. There is no evidence of pyelectasia, nephroliths, infarcts or hydroureter. Renal vasculature is normal.

The right kidney has a normal shape and size (3.7 cm). Overall echogenicity is normal with adequate corticomedullary distinction and a typical 1:3 cortex:medulla ratio. There is no evidence of focal perinephric inflammation or effusion. There is no evidence of pyelectasia, nephroliths, infarcts or hydroureter. Renal vasculature is normal.

Adrenal Glands

The left adrenal gland is normal in size measuring 0.22 cm at the caudal pole. It is observed in its normal position cranial to the left renal artery. It is normal in appearance (uniformly hypoechoic) and shape with no evidence of a mass effect.

The right adrenal gland is normal in size measuring 0.34 cm at the caudal pole. It is observed in its normal position between the cranial aspect of the right kidney and the caudal vena cava. It is normal in appearance (uniformly hypoechoic) and shape with no evidence of a mass effect.

Spleen

The spleen is subjectively normal in size (0.79 cm), echotexture is homogenous, and the splenic capsule is smooth with no irregularities. The blood flow through the hilus and splenic parenchyma appears normal. No focal parenchymal abnormalities are visualized.

Liver

The liver is subjectively normal in size, and echogenicity with smooth peripheral margins. The parenchyma is homogenous echotexture. The visible portions of the vasculature and biliary tract appear normal. No focal nodules or cystic lesions are observed.

The gall bladder lumen is moderately distended. The wall of the gall bladder is not thickened and has a smooth mucosal surface. Luminal contents are mild and likely incidental at this time. The bile duct

PATIENT
Emma Lou King

SPECIES
Feline

BREED
Siamese

SEX
Spayed Female

AGE
14 years

WEIGHT
11.8 lbs

INTERPRETED BY
Kathleen Sennello DVM, MS, Diplomate ACVIM (Small Animal Internal Medicine)

IMAGING PERFORMED BY
Dr. Brittany Wolfe

HOSPITAL NAME
Home Vets

REFERRING VET
Dr. Brittany Wolfe

INVOICE
10979

DATE
12/18/2025

appears slightly prominent and tortuous measuring 0.21 cm. Duodenal papillae is normal measuring at 0.3 cm.

Gastrointestinal

The stomach contains minimal luminal contents. It measures at a normal thickness of <0.36cm with some variability due to the presence of rugal folds. The distinction of the gastric wall layers is adequate and there is no impression of reduced peristaltic activity. No masses or focal lesions were observed.

The visualized areas of duodenum (0.3 cm), jejunum (0.27 cm) and ileum have a uniform diameter with minimal fluid distension. Wall appears subjectively, mildly increased. Bowel loops follow a typical curvilinear path with distinct wall layering. Visualized peristalsis appears appropriate. There were no focal lesions consistent with obstruction or a mass effect observed

The ileocecal junction was visualized and exhibited normal intact wall layering and is subjectively of normal thickness. Sections of colon are visualized with non-formed fecal material and gas shadowing distally. The descending colon wall appears normal with intact wall layering, measuring at 0.14 cm.

Pancreas

The pancreas is prominent and hypoechoic in the right limb. There is no evidence of nodules or cystic lesions. There is no evidence of regional mesenteric inflammation or fluid.

Free Abdomen

Evaluation of the peritoneal cavity did not reveal any evidence of effusion. There is occasional prominent mesenteric lymph nodes. There's a prominent lymph node near the ileocecal junction measuring 0.44 cm. The omentum is of normal uniform echogenicity.

ULTRASONOGRAPHIC FINDINGS

- Prominent, hypoechoic right limb of the pancreas. Findings are most consistent with chronic pancreatic remodeling +/- chronic pancreatitis.
- Mild, diffuse thickening of the small intestine. The mild small intestinal wall changes may be a normal variant in this patient or could be consistent with an inflammatory process (e.g., inflammatory bowel disease).
- Mild reactive lymphadenopathy.

INTERPRETATION OF THE FINDINGS & FURTHER RECOMMENDATIONS

Changes observed on today's scan are relatively mild. There is the impression of diffuse, mild small intestinal thickening with a mild reactive lymphadenopathy, and the pancreas has chronic changes consistent with remodeling +/- chronic pancreatitis. Consider the following:

- Consider a prescription ultra low fat/hydrolyzed protein prescription diet (Royal Canin has one.)
- Consider a GI panel to Texas A&M for evaluation of B12 levels, folate, PLI/TLI etc.. to further evaluate for pancreatic/small intestinal disease. This will screen for exocrine pancreatic

PATIENT

Emma Lou King

SPECIES

Feline

BREED

Siamese

SEX

Spayed Female

AGE

14 years

WEIGHT

11.8 lbs

INTERPRETED BY

Kathleen Sennello DVM, MS, Diplomate ACVIM (Small Animal Internal Medicine)

IMAGING PERFORMED BY

Dr. Brittany Wolfe

HOSPITAL NAME

Home Vets

REFERRING VET

Dr. Brittany Wolfe

INVOICE

10979

DATE

12/18/2025

insufficiency, and help give information regarding small intestinal dysbiosis, b12 deficiency, etc.

- Recommend chronic probiotic therapy.
- Recommend full lab work, including thyroid evaluation.

If there's no response to the above treatments, strongly consider GI biopsies to further evaluate.

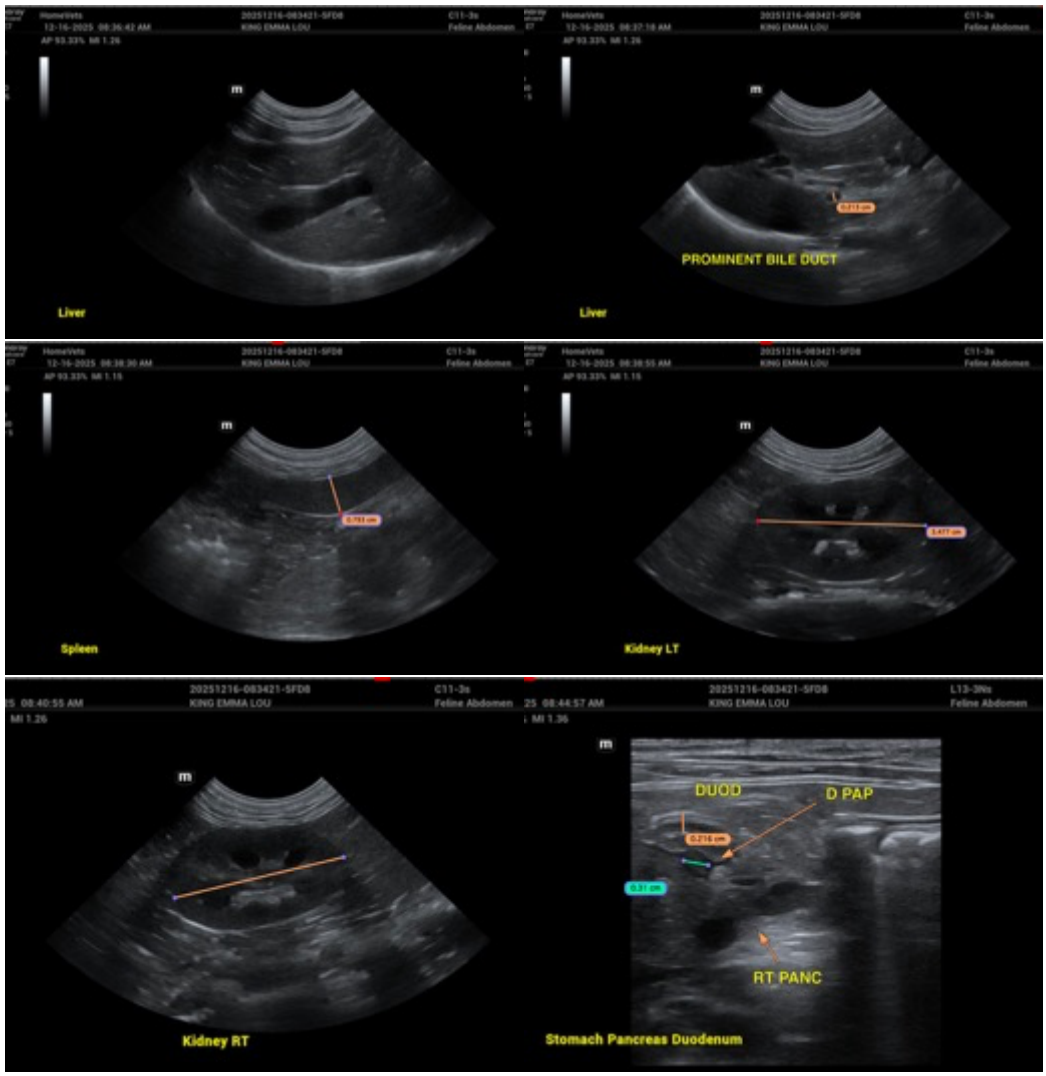

SonoPath
FOSTERING THE ART OF VETERINARY MEDICINE™

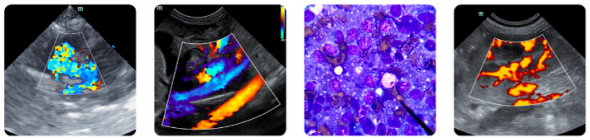

Clinical Sonography & Telecytology
Educational Teleconsultation Services™

SonoPath.com *info@sonopath.com* *1.800.838.4268*

PATIENT

Emma Lou King

SPECIES

Feline

BREED

Siamese

SEX

Spayed Female

AGE

14 years

WEIGHT

11.8 lbs

INTERPRETED BY

Kathleen Sennello DVM, MS, Diplomate ACVIM (Small Animal Internal Medicine)

IMAGING PERFORMED BY

Dr. Brittany Wolfe

HOSPITAL NAME

Home Vets

REFERRING VET

Dr. Brittany Wolfe

INVOICE

10979

DATE

12/18/2025

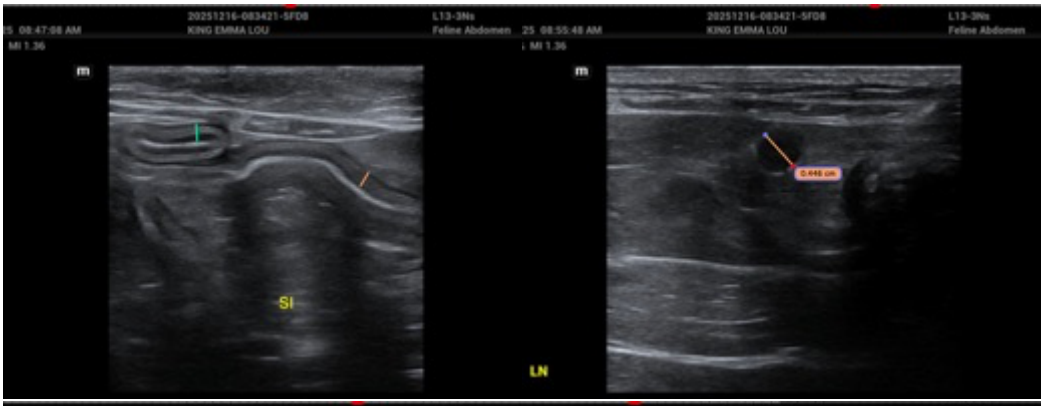

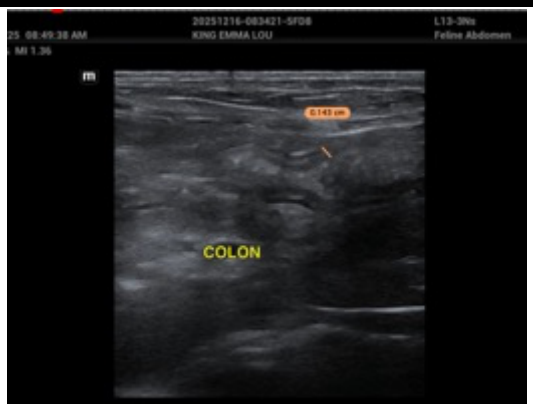

The information and recommendations provided are based on the images presented by the referring veterinarian/sonographer. No evaluation can be communicated regarding pathology that was not visible in the image/video clips provided.

Thank you for this referral. If the clinical or image interpretation does not parallel your findings or if I can be of any further assistance please contact me.

Kathleen Sennello DVM,MS, Diplomate ACVIM (Small animal Internal Medicine)

info@sonopath.com