

PATIENT PRESENTING CLINICAL SIGNS

Bruce Yonaitis History: Recheck ultrasound- initial clinical signs were v+/ decreased appetite/ diarrhea/ wt loss. Possible linear FB seen on AUS and chronic enteropathy. Started hypoallergenic diet and vomiting resolved but has continued to lose weight.

SPECIES

Feline Abnormal PE/Chem/CBC/UA Results: No new BW from last AUS.

BREED ULTRASONOGRAPHIC EXAMINATION OF THE ABDOMEN

DSH *Urinary System*

SEX

Neutered Male The urinary bladder is moderately distended with mild suspended echogenic debris present. The bladder wall, trigone, ureteral papillae and visible urethra (to a depth of 2.0 cm) appear normal with no evidence of wall thickening, mucosal irregularities, masses or calculi. Echogenic debris of this type can be associated with small crystals, cellular debris and proteinaceous debris.

AGE

13 Years The left kidney has a normal shape and size (3.94 cm). Overall echogenicity is slightly hyperechoic with decreased corticomedullary distinction and a typical 1:3 cortex:medulla ratio. There is no evidence of focal perinephric inflammation or effusion. There is no evidence of pyelectasia, nephroliths, infarcts or hydroureter. Renal vasculature is normal.

WEIGHT

9.4 Pounds The right kidney has a normal shape and size (3.84 cm). Overall echogenicity is slightly hyperechoic with decreased corticomedullary distinction and a typical 1:3 cortex:medulla ratio. There is no evidence of focal perinephric inflammation or effusion. There is no evidence of pyelectasia, nephroliths, infarcts or hydroureter. Renal vasculature is normal.

INTERPRETED BY

Kathleen Sennello
DVM, MS, Diplomate
ACVIM (Small animal
Internal Medicine)

IMAGING PERFORMED BY

Meghan Morse, LVT,
CVT

HOSPITAL NAME

Kingston AH

REFERRING VET

Dr. Rosen

INVOICE

35955

DATE

12/18/25

Adrenal Glands

The left adrenal gland is normal in size measuring 0.42 cm at the caudal pole. It is observed in its normal position cranial to the left renal artery. It is normal in appearance (uniformly hypoechoic) and shape with no evidence of a mass effect.

The right adrenal gland is normal in size measuring 0.36 cm at the caudal pole. It is observed in its normal position between the cranial aspect of the right kidney and the caudal vena cava. It is normal in appearance (uniformly hypoechoic) and shape with no evidence of a mass effect.

Spleen

The spleen is subjectively normal in size (0.88 cm), echotexture is homogenous, and the splenic capsule is smooth with no irregularities. The blood flow through the hilus and splenic parenchyma appears normal. No focal parenchymal abnormalities are visualized.

Liver

The liver is subjectively normal in size, and echogenicity with smooth peripheral margins. The parenchyma is homogenous echotexture. The visible portions of the vasculature and biliary tract appear normal. No focal nodules or cystic lesions are observed. The gall bladder lumen is moderately distended. The wall of the gall bladder is not thickened and has a smooth mucosal surface. Luminal contents are primarily anechoic. The cystic and common bile ducts are normal/not visible.

Gastrointestinal



PATIENT

Bruce Yonaitis

The stomach contains minimal luminal contents. It measures at a normal thickness of <0.7 cm with some variability due to the presence of rugal folds. The distinction of the gastric wall layers is adequate and there is no impression of reduced peristaltic activity. No masses or focal lesions were observed.

SPECIES

Feline

Most of the areas of duodenum, jejunum and ileum have a uniform diameter with mild to moderate fluid and gas distension. Wall thickness is normal to slightly increased. Bowel loops follow a typical curvilinear path with distinct wall layering, but some areas display a prominent muscularis layer which does not display the typical 1:3 muscularis:mucosa layer ratio. The duodenum measured 0.32 cm in diameter, and the jejunum measured 0.25 cm in diameter. Visualized peristalsis appears appropriate. The small intestine appears diffusely “ropey” with some areas exhibiting a mildly prominent muscularis layer, along with mild to moderate fluid and gas distention. A focal area of small intestine is visualized which appears more significantly thickened, measuring 0.39 cm with reduced detailed wall layering.

BREED

DSH

SEX

Neutered Male

Sections of colon are visualized with formed fecal material and gas shadowing distally. There is no observed focal or generalized colon wall thickening or loss of layering.

AGE

13 Years

Pancreas

The pancreas is prominent and mottled in both limbs compared to the surrounding isoechoic mesentery. There is no evidence of nodules or cystic lesions. There is no evidence of regional mesenteric inflammation or fluid.

WEIGHT

9.4 Pounds

Free Abdomen

There is no free fluid. There is a focal lymphadenopathy with a cluster of large hypoechoic mesenteric lymph nodes surrounded by hyperechoic mesentery. These lymph nodes measure 1.06 cm x 1.23 cm and 1.11 cm x 1.26 cm.

INTERPRETED BY

Kathleen Sennello
DVM, MS, Diplomate
ACVIM (Small animal
Internal Medicine)

ULTRASONOGRAPHIC FINDINGS

IMAGING PERFORMED BY

Meghan Morse, LVT,
CVT

Primary Findings

- Prominent mottled pancreas visualized in both limbs- Findings are most consistent with chronic pancreatic remodeling +/- chronic active pancreatitis.
- Diffusely mildly/moderately fluid and gas distended small intestine with some focal areas exhibiting significant wall thickening and reduced detailed wall layering – Findings are most consistent with a generalized inflammatory pattern, although the focal thickened areas are concerning for possible progression to a neoplastic process.

HOSPITAL NAME

Kingston AH

- Clusters of large mesenteric lymph nodes- Findings are most consistent with reactive or early neoplastic lymph nodes.

REFERRING VET

Dr. Rosen

Secondary Findings

INVOICE

35955

- Mild suspended echogenic debris in the urinary bladder- The echogenic debris in the bladder lumen could be consistent with cells, crystals, and/or mucus. Recommend urinalysis and culture.

DATE

12/18/25

- Age-related changes associated with both kidneys.

INTERPRETATION OF THE FINDINGS & FURTHER RECOMMENDATIONS



PATIENT

Bruce Yonaitis

SPECIES

Feline

BREED

DSH

SEX

Neutered Male

AGE

13 Years

WEIGHT

9.4 Pounds

INTERPRETED BY

Kathleen Sennello
 DVM, MS, Diplomate
 ACVIM (Small animal
 Internal Medicine)

**IMAGING
 PERFORMED BY**

Meghan Morse, LVT,
 CVT

HOSPITAL NAME

Kingston AH

REFERRING VET

Dr. Rosen

INVOICE

35955

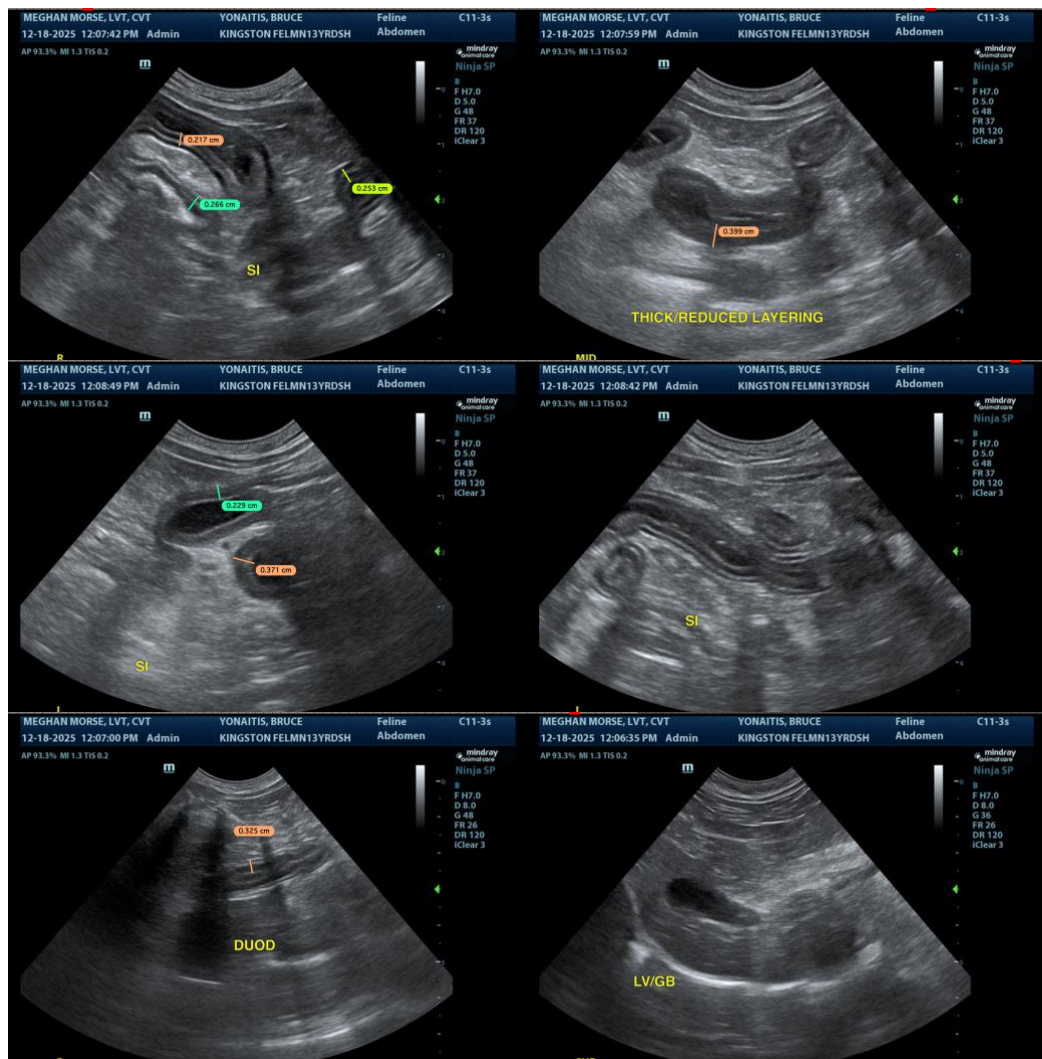
DATE

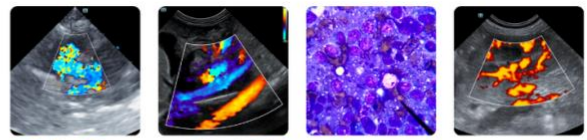
12/18/25

The changes observed on the previous exam 8/2025 are persistent with some focal sections of bowel, which appear more thickened and hypoechoic, concerning for possible progression. Ideally, this patient should have biopsies of the GI tract and lymph nodes to further evaluate, as well as a GI panel to Texas A & M for a qualitative fPLI, TLI, cobalamin, and folate, looking for a B-12 deficiency, concurrent exocrine pancreatic insufficiency, etc. Both limbs of the pancreas are also prominent, consistent with pancreatic remodeling, but mild inflammation may also be present, which could be evaluated with PLI level.

If biopsies are not possible and you're already on a hypoallergenic diet, probiotic therapy, etc., then steroid therapy should be discussed with the owner (pros and cons) and continued monitoring with ultrasound.

If a safe window for sampling is available, a fine needle aspirate of a mesenteric lymph node could be considered for cytologic evaluation.





PATIENT

Bruce Yonaitis

SPECIES

Feline

BREED

DSH

SEX

Neutered Male

AGE

13 Years

WEIGHT

9.4 Pounds

INTERPRETED BY

Kathleen Sennello
 DVM, MS, Diplomate
 ACVIM (Small animal
 Internal Medicine)

**IMAGING
 PERFORMED BY**

Meghan Morse, LVT,
 CVT

HOSPITAL NAME

Kingston AH

REFERRING VET

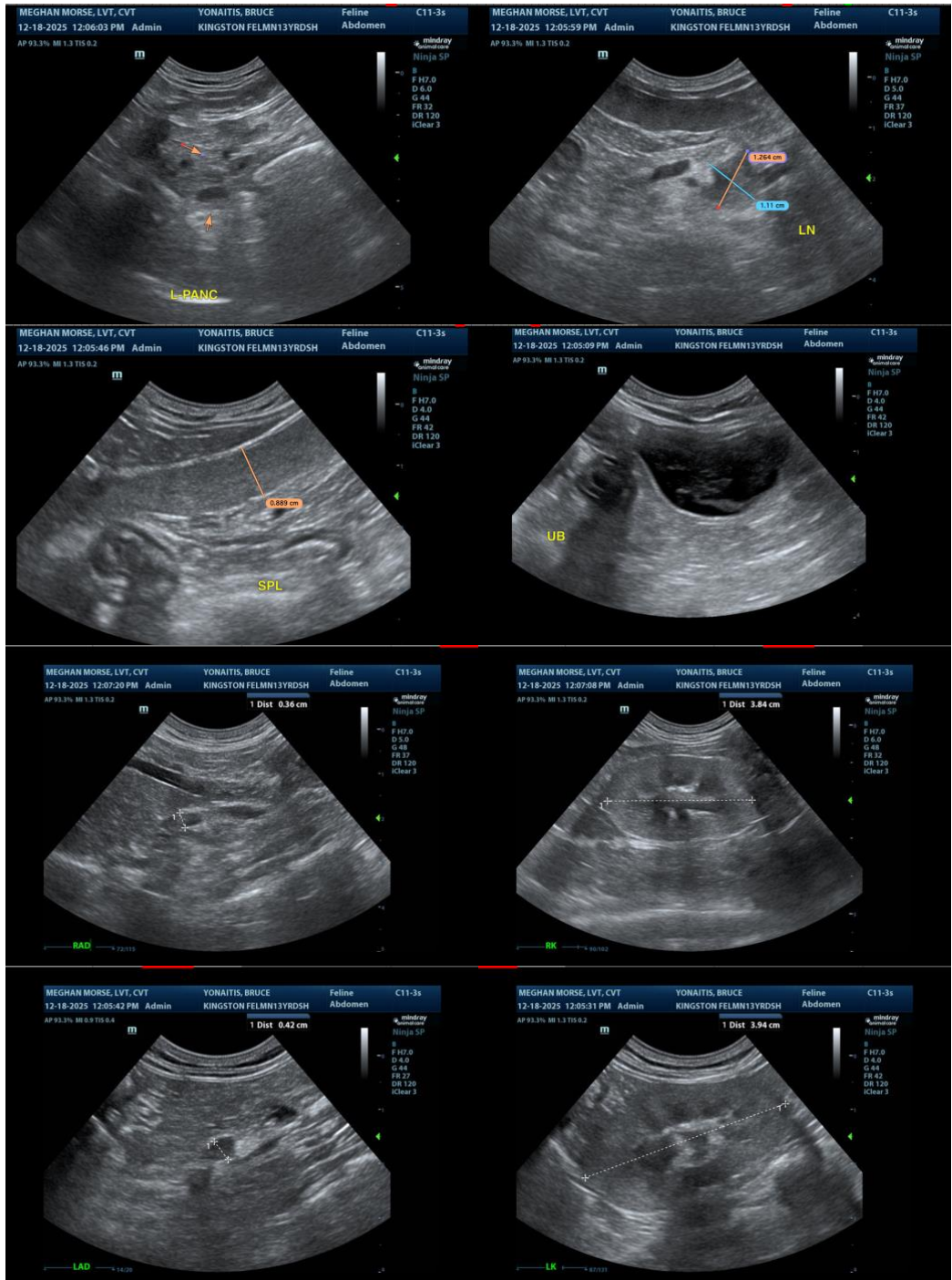
Dr. Rosen

INVOICE

35955

DATE

12/18/25





PATIENT

Bruce Yonaitis

SPECIES

Feline

BREED

DSH

SEX

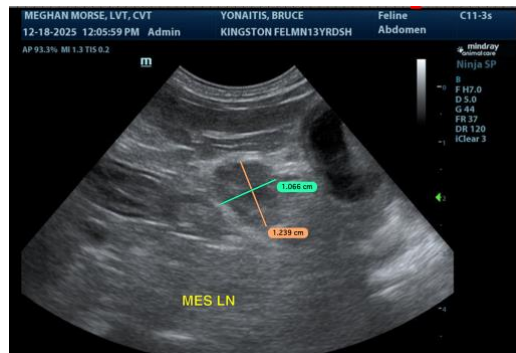Neutered Male

AGE

13 Years

WEIGHT

9.4 Pounds



The information and recommendations provided are based on the images presented by the referring veterinarian/sonographer. No evaluation can be communicated regarding pathology that was not visible in the image/video clips provided.

Thank you for this referral. If the clinical or image interpretation does not parallel your findings or if I can be of any further assistance, please contact me.

Kathleen Sennello DVM, MS, Diplomate ACVIM (Small animal Internal Medicine)

info@sonopath.com

INTERPRETED BY

Kathleen Sennello
DVM, MS, Diplomate
ACVIM (Small animal
Internal Medicine)

IMAGING PERFORMED BY

Meghan Morse, LVT,
CVT

HOSPITAL NAME

Kingston AH

REFERRING VET

Dr. Rosen

INVOICE

35955

DATE

12/18/25