



DATE PRESENTING CLINICAL SIGNS

12/16/25

Patient History: Vito was recently diagnosed with ckd stage 2. He is doing pretty well but we want to better assess the kidney structure and also just get a general impression of the other abdominal organs.

PATIENT

Vito Peltier

Current Medications: None except for renal diet

Labwork Results: Labwork attached, reported as: Urine s.g.=1.018, Creat=2.0

Date of Previous IntraPet Ultrasound: No previous.

Sedation: Dexdomitor.

SPECIES

Feline

Stat Report: Not requested.

Imaging Performed by: Stephanie Warga RDCS, RVT.

BREED

DSH

ULTRASONOGRAPHIC EXAMINATION OF THE ABDOMEN

Urinary System

The urinary bladder is moderately distended with anechoic urine. The Bladder wall, trigone, ureteral papillae and visible urethra (to a depth of 2cm) appear normal with no evidence of wall thickening, mucosal irregularities, masses or cystic calculi.

SEX

Neutered Male

The left kidney has a normal shape and size (4.26 cm). The cortex is increased in echogenicity with mildly reduced corticomedullary distinction and a typical 1:3 cortex:medulla ratio. There is no evidence of focal perinephric inflammation or effusion. There is no evidence of pyelectasia, nephroliths, infarcts or hydroureter. Renal vasculature is normal.

AGE

6/4/14

WEIGHT

13.75 lbs

The right kidney is normal in shape but borderline small in size (3.34 cm). The cortex is increased in echogenicity with mildly reduced corticomedullary distinction and a typical 1:3 cortex:medulla ratio. There is no evidence of focal perinephric inflammation or effusion. There is no evidence of pyelectasia, nephroliths, infarcts or hydroureter. Renal vasculature is normal.

INTERPRETED BY

Kathleen Sennello DVM,
MS, Diplomate ACVIM
(Small Animal Internal
Medicine)

Adrenal Glands

The left adrenal gland is normal in size measuring 0.44 cm at the caudal pole. It is observed in its normal position cranial to the left renal artery. It is normal in appearance (uniformly hypoechoic) and shape with no evidence of a mass effect.

HOSPITAL NAME

Cat Sense Feline
Hospital

The right adrenal gland is normal in size measuring 0.29 cm at the caudal pole. It is observed in its normal position between the cranial aspect of the right kidney and the caudal vena cava. It is normal in appearance (uniformly hypoechoic) and shape with no evidence of a mass effect.

REFERRING VET

Dr. Sinclair

Spleen

The spleen is subjectively normal in size (1.0 cm), echotexture is homogenous, and the splenic capsule is smooth with no irregularities. The blood flow through the hilus and splenic parenchyma appears normal. No focal parenchymal abnormalities are visualized.

INVOICE

72615

Liver

The liver is subjectively normal in size, and echogenicity with smooth peripheral margins. The parenchyma is homogenous echotexture. The visible portions of the vasculature and biliary tract appear normal. No focal nodules or cystic lesions are observed.

The gall bladder lumen is moderately distended. The wall of the gall bladder is not thickened and has a smooth mucosal surface. Luminal contents are mild and likely incidental at this time. The cystic and common bile ducts are normal/not visible.

Gastrointestinal

The stomach contains minimal luminal contents. It measures at a normal thickness of <0.36cm with some variability due to the presence of rugal folds. The distinction of the gastric wall layers is adequate and there is no impression of reduced peristaltic activity. No masses or focal lesions were observed.

The visualized areas of duodenum, jejunum and ileum have a relatively uniform diameter with minimal fluid distension. Wall thickness is normal. Bowel loops follow a curvilinear path with distinct wall layering maintaining the typical 1:3 muscularis:mucosa layer ratio. Duodenum wall measures 0.28 cm. Jejunum wall measures 0.23 cm. Visualized peristalsis appears appropriate. There were no focal lesions consistent with obstruction or a mass effect observed.

The ileocecal junction was visualized and exhibited normal intact wall layering and is subjectively of normal thickness. Sections of colon are visualized with formed fecal material and gas shadowing distally. There is no observed focal or generalized colon wall thickening or loss of layering.

Pancreas

The pancreas is prominent and hypoechoic as compared to the surrounding isoechoic mesentery. There is no evidence of nodules or cystic lesions. There is no evidence of regional mesenteric inflammation or fluid. Prominent pancreatic duct noted.

Free Abdomen

Evaluation of the peritoneal cavity did not reveal any evidence of effusion, or subjective lymphadenomegaly. The Medial iliac nodes appear normal and there was no evidence of a caudal aortic thrombus at the bifurcation. The omentum is of normal uniform echogenicity.

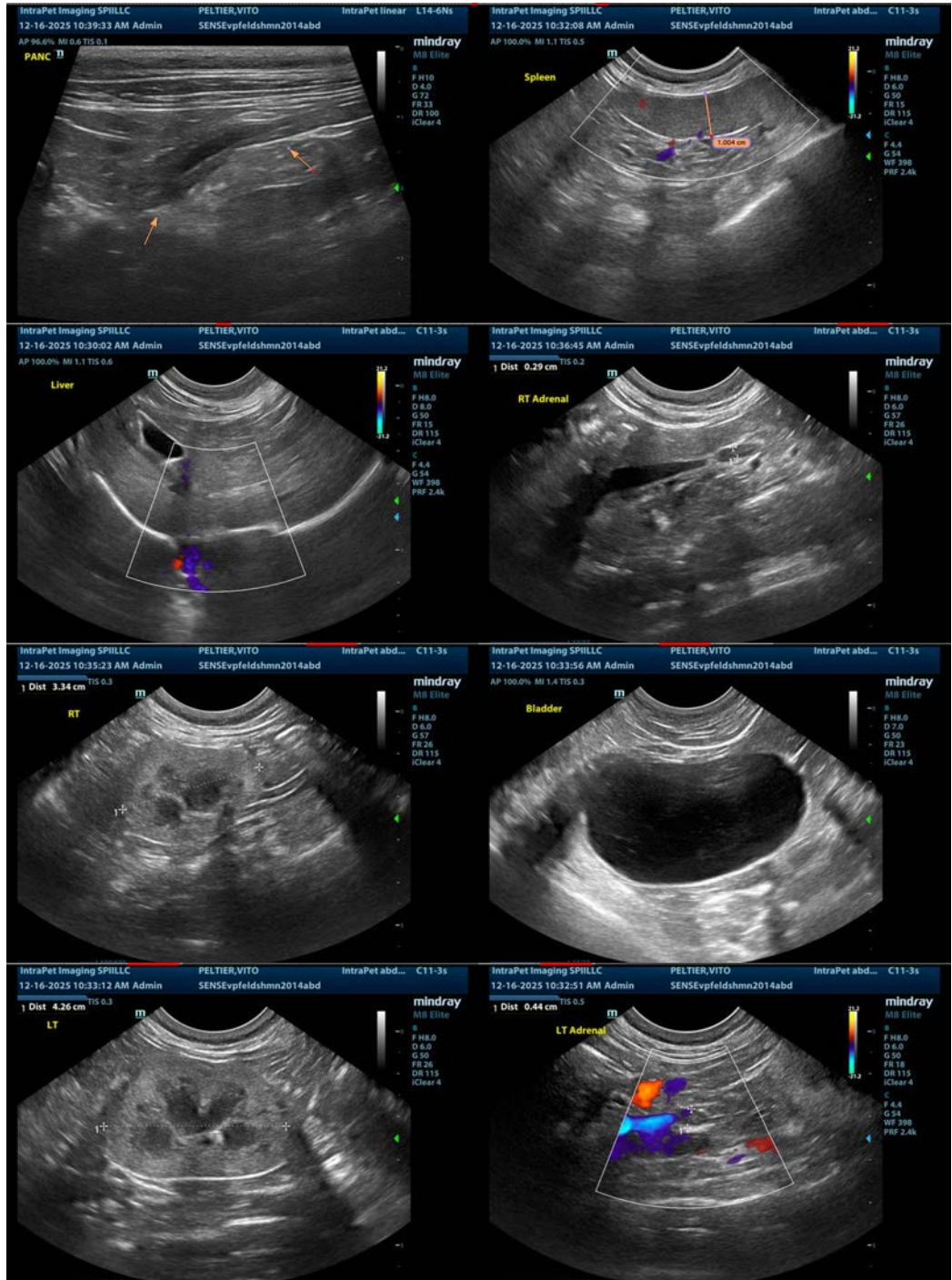
ULTRASONOGRAPHIC FINDINGS

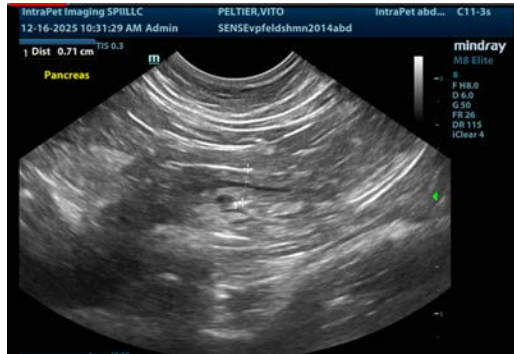- Mildly reduced corticomedullary distinction in both kidneys – Mild loss of corticomedullary distinction in both kidneys could be consistent with chronic degenerative disease or interstitial nephrosis.
- Prominent, hypoechoic pancreas – Findings are most consistent with chronic pancreatic remodeling +/- mild chronic inflammation.

INTERPRETATION OF THE FINDINGS & FURTHER RECOMMENDATIONS

There are mild changes visualized associated with both kidneys. There is no evidence of significant pyelectasia, nephroliths, an obstructive process, etc. Initial dietary therapy for early renal disease would be indicated, as well as blood pressure evaluation to establish baseline.

The pancreas is prominent and hypoechoic. Correlate these findings with a PLI level. I suspect these changes are consistent with chronic remodeling, although mild inflammation is possible.





The information and recommendations provided are based on the images presented by the referring veterinarian/sonographer. No evaluation can be communicated regarding pathology that was not visible in the image/video clips provided.

Thank you for this referral. If the clinical or image interpretation does not parallel your findings or if I can be of any further assistance please contact me.

Kathleen Sennello DVM,MS, Diplomate ACVIM (Small animal Internal Medicine)
info@sonopath.com