



DATE PRESENTING CLINICAL SIGNS

12/16/25 **Patient History:** exam-retching and vomited 1 sock.

PATIENT Current Medications: None.

Skylar King **Labwork Results:** Diagnostics not attached, reported as: material after fasting still in stomach, large amount of material (FB?) moved to colon overnight-dilated, intestines in am radiographs as well. Bloodwork pending

Date of Previous IntraPet Ultrasound: No previous.

Sedation: Not required to complete full diagnostic ultrasound.

SPECIES Stat Report: Not requested.

Canine **Imaging Performed by:** Stephanie Warga RDCS, RVT.

BREED ULTRASONOGRAPHIC EXAMINATION OF THE ABDOMEN

English Springer **Urinary System**
Spaniel

The urinary bladder is moderately distended with anechoic urine. The Bladder wall, trigone, ureteral papillae and visible urethra (to a depth of 2cm) appear normal with no evidence of wall thickening, mucosal irregularities, masses or cystic calculi.

SEX

Spayed Female The left kidney has a normal shape and size (6.53 cm). Overall echogenicity is normal with adequate corticomedullary distinction and a typical 1:3 cortex:medulla ratio. There is no evidence of focal perinephric inflammation or effusion. There is no evidence of pyelectasia, nephroliths, infarcts or hydroureter. Renal vasculature is normal.

AGE

6/28/14

WEIGHT

47.6 lbs

The right kidney has a normal shape and size (6.28 cm). Overall echogenicity is normal with adequate corticomedullary distinction and a typical 1:3 cortex:medulla ratio. There is no evidence of focal perinephric inflammation or effusion. There is no evidence of pyelectasia, nephroliths, infarcts or hydroureter. Renal vasculature is normal.

INTERPRETED BY

Kathleen Sennello DVM,
MS, Diplomate ACVIM
(Small Animal Internal
Medicine)

Adrenal Glands

The left adrenal gland is large and mottled, measuring 0.93 cm at the cranial pole and 0.79 cm at the caudal pole. It is observed in its normal position cranial to the left renal artery. There are occasional poorly defined hyperechoic areas/nodules in the parenchyma that do not deviate the adrenal capsule, measuring 1.43 cm x 0.58 cm and 0.95 cm x 1.05 cm.

HOSPITAL NAME

Chadwell Animal
Hospital

The right adrenal gland is normal in size measuring 1.18 cm at the cranial pole and 0.72 cm at the caudal pole. It is observed in its normal position between the cranial aspect of the right kidney and the caudal vena cava. It is somewhat abnormal in appearance in that there is a poorly defined hyperechoic nodule in the cranial pole measuring 1.15 cm x 0.77 cm. No evidence of vascular invasion is visualized.

REFERRING VET

Dr. Gold

Spleen

The spleen is subjectively normal in size (1.77 cm in width at the level of the hilus). The spleen echotexture is mildly mottled, the splenic capsule is smooth with no irregularities. The blood flow through the hilus and splenic parenchyma appears normal. No focal parenchymal abnormalities are visualized.

INVOICE

72611

Liver

The liver is subjectively normal in size, and echogenicity with smooth peripheral margins. The parenchyma is homogenous echotexture. The visible portions of the vasculature and biliary tract appear normal. No focal nodules or cystic lesions are observed.

The gall bladder lumen is moderately distended. The wall of the gall bladder is not thickened and has a smooth mucosal surface. Luminal contents are mild and likely incidental at this time. The cystic and common bile ducts are normal/not visible.

Gastrointestinal

The stomach contains mild fluid and gas. It measures at a normal thickness of <0.7cm with some variability due to the presence of rugal folds. The distinction of the gastric wall layers is adequate and there is no impression of reduced peristaltic activity. There is some focal shadowing material visualized within the gastric lumen. This is accompanied by some gas and a small amount of fluid. Findings are concerning for ingested foreign material, although ingesta is also possible. The pylorus appears somewhat thickened, measuring at 0.77 cm, with focal gas and a small amount of shadowing ingesta. A definitive obstructive pattern is not observed.

Most of the visualized areas of duodenum, jejunum and ileum have a relatively uniform diameter with minimal to moderate fluid and gas. Wall thickness is normal. Bowel loops follow a curvilinear path with distinct wall layering maintaining the typical 1:3 muscularis:mucosa layer ratio. Duodenum wall measures 0.36 cm. Jejunum wall measures 0.24 cm. Visualized peristalsis appears appropriate. The proximal duodenum appears mildly fluid and gas distended. A definitive foreign object is not clearly observed but cannot be ruled out.

The ileocecal junction was visualized and exhibited normal intact wall layering and is subjectively of normal thickness. The descending colon has areas of distinct shadowing material most consistent with formed fecal material or passing foreign material. There is no observed focal or generalized colon wall thickening or loss of layering.

Pancreas

The pancreas is normal and isoechoic to surrounding mesentery. There is a focal area in the left limb that appears somewhat prominent and mottled. There is no evidence of regional mesenteric inflammation or fluid.

Free Abdomen

Evaluation of the peritoneal cavity did not reveal any evidence of effusion. There is no significant lymphadenopathy. A slightly prominent mesenteric lymph node is visualized measuring 0.44 cm x 4.02 cm.

ULTRASONOGRAPHIC FINDINGS

- Poorly defined hyperechoic nodules visualized in both adrenals with a borderline large left adrenal and a prominent cranial pole of the right adrenal – These changes generally have a somewhat benign appearance, most consistent with hyperplasia, etc. Early neoplastic lesions cannot be ruled out.
- Mildly mottled spleen – The diffuse splenic changes are non-specific and could be consistent with lymphoid hyperplasia, extramedullary hematopoiesis, infiltrative neoplasia, inflammation, other. Cytology or histopathology would be necessary to get a definitive diagnosis.
- Prominent area of the left pancreas – Findings could be consistent with mild focal remodeling or inflammation.
- Shadowing ingesta and some fluid and gas visualized within the gastric lumen – If the patient had a prolonged fast, this would be concerning for foreign material. A definitive obstruction is not visualized at this time, but the pylorus appears thickened and there is some gas and shadowing in this region.

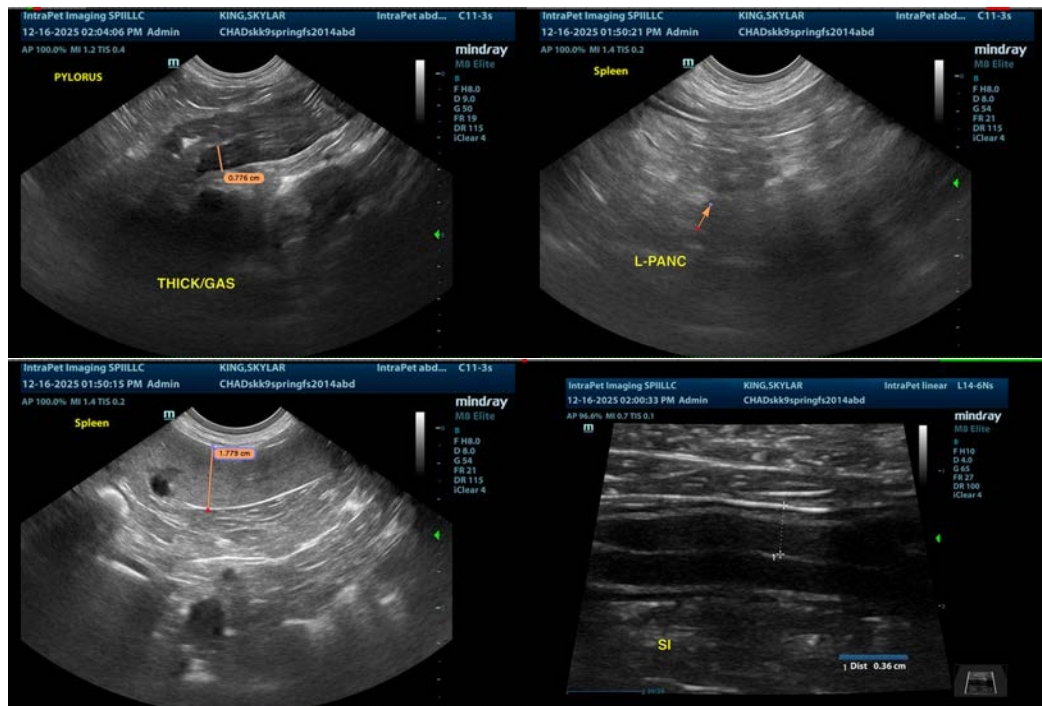
INTERPRETATION OF THE FINDINGS & FURTHER RECOMMENDATIONS

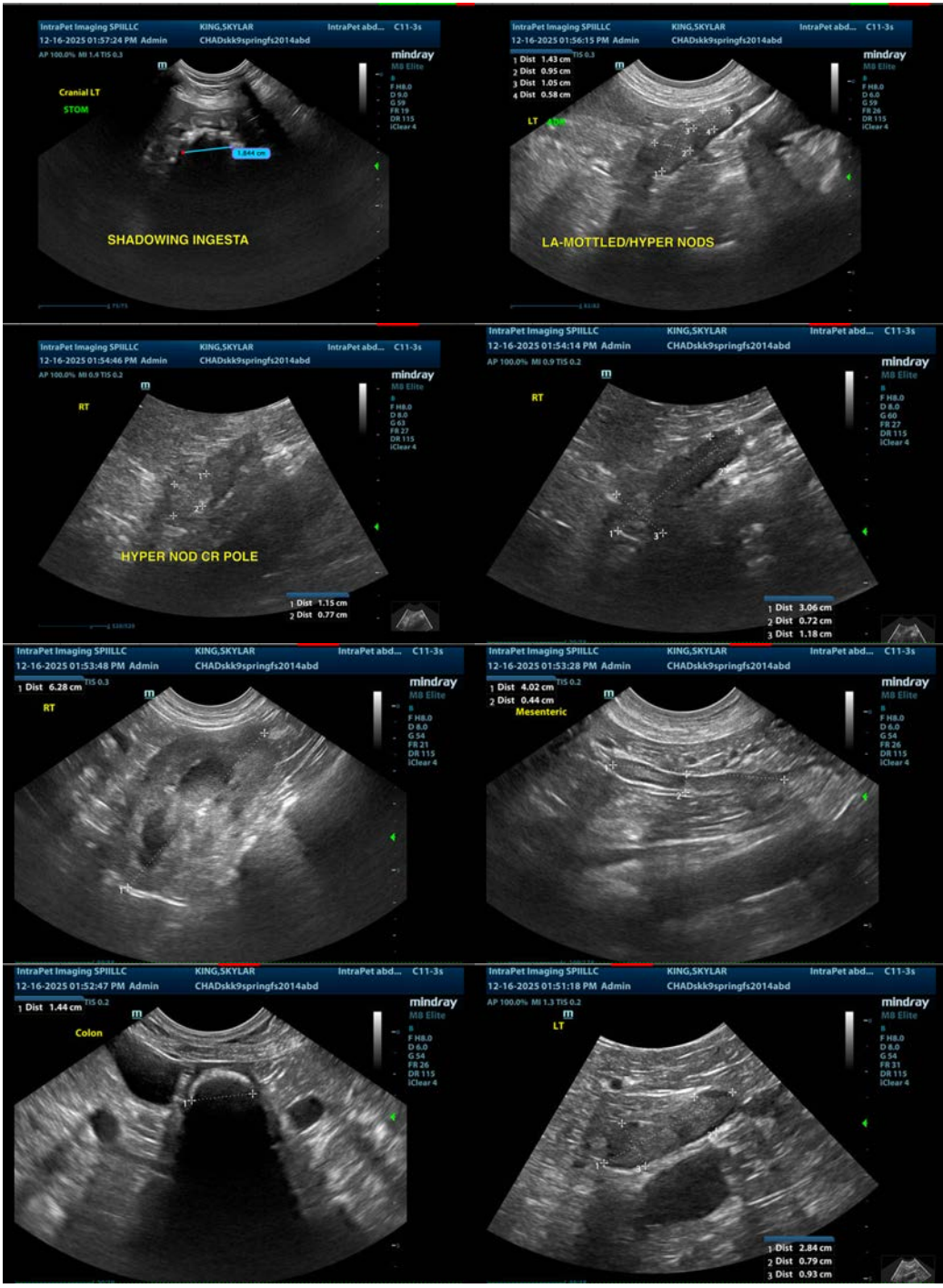
There is some focal shadowing material visualized in the stomach. No evidence of an outflow tract obstruction is visualized, but there is some gas obscuring some areas of the pylorus, and the proximal duodenum is mildly fluid and gas distended. Partially obstructive material at the level of the pylorus cannot be ruled out. Options would include continued monitoring with a more prolonged fast, or upper GI endoscopy to further investigate.

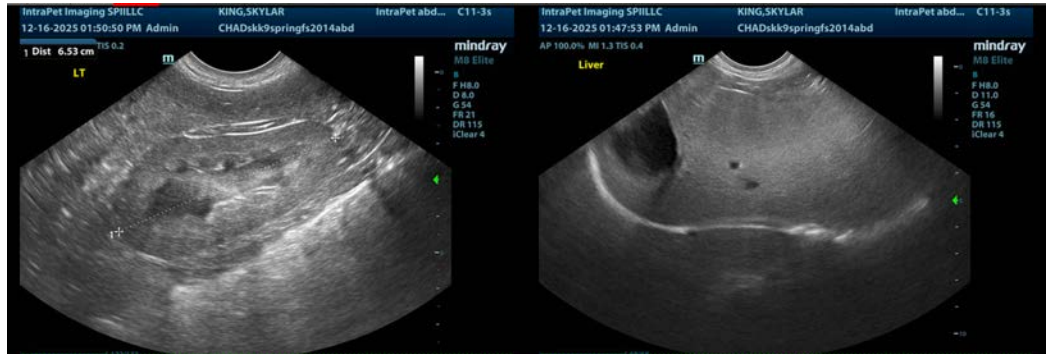
There is no evidence of a small intestinal obstructive pattern at this time. Some areas of the colon have hard shadowing material most consistent with formed fecal material or passing foreign material.

Both adrenals are mottled with some poorly defined nodules. These generally have a somewhat benign appearance, possibly consistent with hyperplasia, etc. although early neoplastic changes cannot be ruled out. If the patient has symptoms consistent with Cushing's after this episode of illness has resolved, you could consider adrenal function testing. Additionally consider follow up evaluation of the adrenals in the future, looking for progression of these changes (2-3 months).

The spleen subjectively appears very mildly mottled. The significance of this is uncertain. Options would include continued monitoring or fine needle aspirate.







The information and recommendations provided are based on the images presented by the referring veterinarian/sonographer. No evaluation can be communicated regarding pathology that was not visible in the image/video clips provided.

Thank you for this referral. If the clinical or image interpretation does not parallel your findings or if I can be of any further assistance please contact me.

Kathleen Sennello DVM,MS, Diplomate ACVIM (Small animal Internal Medicine)
info@sonopath.com