



PATIENT

Kupo Verile

SPECIES

Canine

BREED

Pug

SEX

Neutered Male

AGE

7

WEIGHT

25 lbs

INTERPRETED BY

Kathleen Sennello DVM,
MS, Diplomate ACVIM
(Small Animal Internal
Medicine)

IMAGING PERFORMED BY

Dr. Elaina Petrone

HOSPITAL NAME

Long Branch Animal
Hospital

REFERRING VET

Dr. Elaina Petrone

INVOICE

10943

DATE

12/16/2025

PRESENTING CLINICAL SIGNS

Recently had a mast cell tumor removed from the right lateral thorax, Grade 2/low grade, extended to subcutaneous layer. CXR clear AUS to stage.

ULTRASONOGRAPHIC EXAMINATION OF THE ABDOMEN

Urinary System

The urinary bladder is moderately distended with anechoic urine. The Bladder wall, trigone, ureteral papillae and visible urethra (to a depth of 2cm) appear normal with no evidence of wall thickening, mucosal irregularities, masses or cystic calculi.

The prostate is normal in size (0.83cm) and shape for this neutered male dog. The parenchyma is homogenous and the external margins are smooth. The prostatic urethra appears normal with no evidence of irregularity, invasion, mass effect or calculi.

The left kidney has a normal shape and size (4.5 cm). Overall echogenicity is normal with adequate corticomedullary distinction and a typical 1:3 cortex:medulla ratio. There is no evidence of focal perinephric inflammation or effusion. There is no evidence of pyelectasia, nephroliths, infarcts or hydroureter. Renal vasculature is normal.

The right kidney has a normal shape and size (4.86 cm). Overall echogenicity is normal with adequate corticomedullary distinction and a typical 1:3 cortex:medulla ratio. There is no evidence of focal perinephric inflammation or effusion. There is no evidence of pyelectasia, nephroliths, infarcts or hydroureter. Renal vasculature is normal.

Adrenal Glands

The left adrenal gland is normal in size measuring 0.36 cm at the cranial pole and 0.4 cm at the caudal pole. It is observed in its normal position cranial to the left renal artery. It is normal in appearance (uniformly hypoechoic) and shape with no evidence of a mass effect.

The region of the right adrenal (between right cranial kidney and vena cava) is unremarkable, but the adrenal is not distinctly visualized. No evidence of a mass effect.

Spleen

The spleen is subjectively normal in size (1.39 cm) and the echotexture is homogenous. The splenic capsule is smooth with no visible irregularities. The blood flow through the hilus and splenic parenchyma appears normal. No focal parenchymal abnormalities are visualized.

Liver

The liver is subjectively normal in size, and echogenicity with smooth peripheral margins. The parenchyma is homogenous echotexture. The visible portions of the vasculature and biliary tract appear normal. No focal nodules or cystic lesions are observed.

The gall bladder lumen is moderately distended. The wall of the gall bladder is not thickened and has a smooth mucosal surface. Luminal contents are mild and likely incidental at this time. The cystic and common bile ducts are normal/not visible.

Gastrointestinal



PATIENT

Kupo Verile

SPECIES

Canine

BREED

Pug

SEX

Neutered Male

AGE

7

WEIGHT

25 lbs

INTERPRETED BY

Kathleen Sennello DVM,
MS, Diplomate ACVIM
(Small Animal Internal
Medicine)

IMAGING PERFORMED BY

Dr. Elaina Petrone

HOSPITAL NAME

Long Branch Animal
Hospital

REFERRING VET

Dr. Elaina Petrone

INVOICE

10943

DATE

12/16/2025

The stomach contains minimal luminal contents. It measures at a normal thickness of <0.7cm with some variability due to the presence of rugal folds. The distinction of the gastric wall layers is adequate and there is no impression of reduced peristaltic activity. No masses or focal lesions were observed.

The visualized areas of duodenum, jejunum and ileum have a relatively uniform diameter with minimal fluid distension. Wall thickness is normal. Bowel loops follow a curvilinear path with distinct wall layering maintaining the typical 1:3 muscularis:mucosa layer ratio. The duodenum measured as normal (0.45 cm in wall thickness) and the jejunum measured as normal (0.36 cm.) Visualized peristalsis appears appropriate. There were no focal lesions consistent with obstruction or a mass effect observed.

Sections of colon are visualized with formed fecal material and gas shadowing distally. There is no observed focal or generalized colon wall thickening or loss of layering.

Pancreas

The pancreas is normal and isoechoic to surrounding mesentery. There is no evidence of nodules or cystic lesions. There is no evidence of regional mesenteric inflammation or fluid.

Free Abdomen

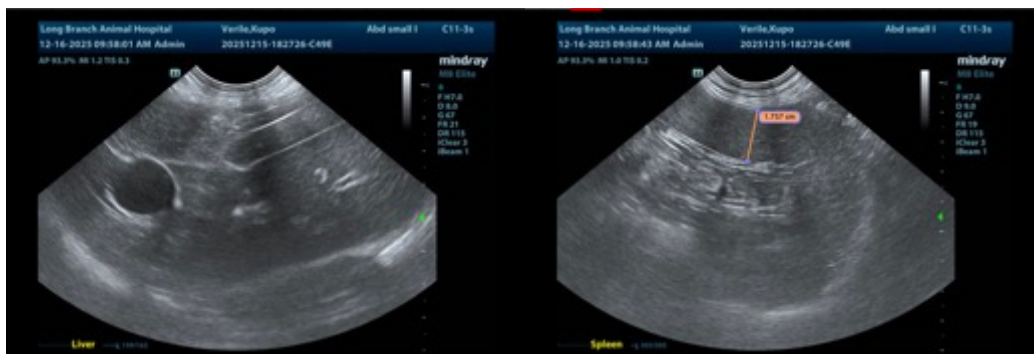Evaluation of the peritoneal cavity did not reveal any evidence of effusion, or subjective lymphadenomegaly. The Medial iliac nodes appear normal and there was no evidence of a caudal aortic thrombus at the bifurcation. The omentum is of normal uniform echogenicity.

ULTRASONOGRAPHIC FINDINGS

- No significant ultrasonographic lesions visualized.

INTERPRETATION OF THE FINDINGS & FURTHER RECOMMENDATIONS

No nodules or focal mass lesions are observed on today's exam. The spleen is slightly curled in the abdomen but otherwise appears within normal limits. No evidence of metastatic disease is evident at this time.





PATIENT

Kupo Verile

SPECIES

Canine

BREED

Pug

SEX

Neutered Male

AGE

7

WEIGHT

25 lbs

INTERPRETED BY

Kathleen Sennello DVM,
MS, Diplomate ACVIM
(Small Animal Internal
Medicine)

IMAGING PERFORMED BY

Dr. Elaina Petrone

HOSPITAL NAME

Long Branch Animal
Hospital

REFERRING VET

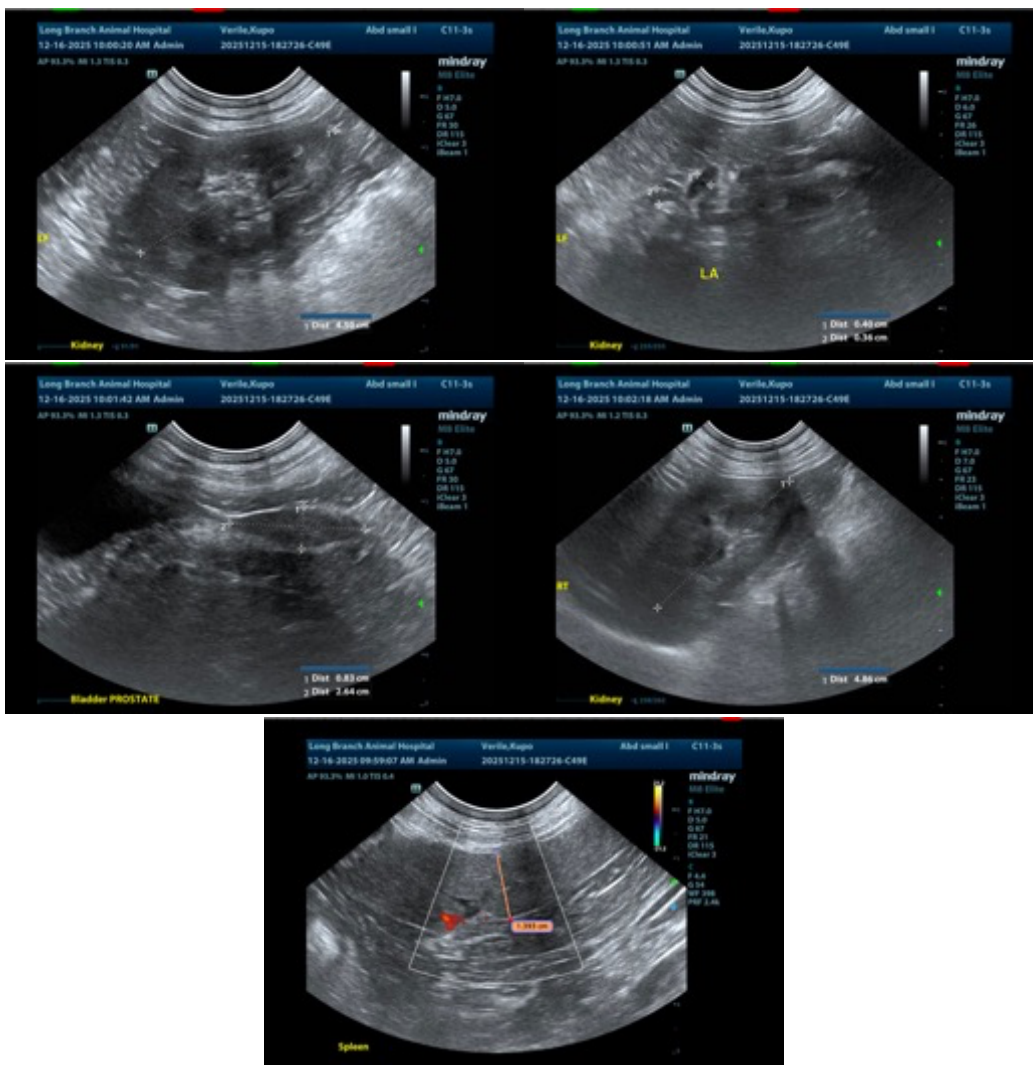
Dr. Elaina Petrone

INVOICE

10943

DATE

12/16/2025



The information and recommendations provided are based on the images presented by the referring veterinarian/sonographer. No evaluation can be communicated regarding pathology that was not visible in the image/video clips provided.

Thank you for this referral. If the clinical or image interpretation does not parallel your findings or if I can be of any further assistance please contact me.

Kathleen Sennello DVM,MS, Diplomate ACVIM (Small animal Internal Medicine)

info@sonopath.com