

**DATE**

12/16/22

PRESENTING CLINICAL SIGNS

History: Hx of PLN, pancreatitis, UTI's, urinary incontinence. Recent episode of gastroenteritis 12/12/22 Tx with Cerenia and Metronidazole. Recent UTI 11/25/22 Tx with Marbofloxacin. BP 12/12/22 #2 cuff, 124/77, MAP 92, HR110.

PATIENT

Bijou Munoz

Current Medications: Long-term meds semintra 2.5mg/kg/day (0.7ml PO BID) ursodiol 60 mg SID, denamarin SID. 12/12/22 - Cerenia 16mg 1 PO SID x 4 days, Metronidazole 250mg 1/4 PO BID x 7 days. 11/25/22 - Marboquin 25mg 1 PO SID x 14 days - D/C after 10 days d/t anorexia.

SPECIES

Canine

Lab Results: CBC: HCT 37%. Chem: BUN 69, Creat 1.4, SDMA 11, Ca 12.0H, K 5.5H, Na/K 27, ALP 1164, Alb 3.4, T4 1.0, UA (FC) 1.013, Inactive sediment, UPC 1.0 (hx 1.6 in June 2022).

BREED

Miniature Schnauzer

Date of Previous IntraPet Ultrasound: No previous.

Sedation: Not required to complete full diagnostic ultrasound.

Stat Report: Not requested.

Imaging Performed By: Andi Parkinson, BS, RDMS.

SEX

Spayed Female

ULTRASONOGRAPHIC EXAMINATION OF THE ABDOMEN**AGE**

12/13/11

Urinary System

The urinary bladder is moderately distended with anechoic urine. The bladder wall, trigone, ureteral papillae and visible urethra (to a depth of 2.0 cm) appear normal with no evidence of wall thickening, mucosal irregularities, masses or cystic calculi.

WEIGHT

11.6 Pounds

The left kidney has a normal shape and size (4.54 cm). Overall echogenicity is slightly hyperechoic with poor corticomedullary distinction and a typical 1:3 cortex:medulla ratio. There is no evidence of focal perinephric inflammation or effusion. There is no evidence of nephroliths, infarcts or hydroureter. Renal vasculature is normal. Numerous small cortical cysts are noted. Pyelectasia is present, measuring 0.32 cm.

INTERPRETED BY

Kathleen Sennello DVM,
MS, Diplomate ACVIM
(Small Animal Internal
Medicine)

The right kidney has a normal shape and size (5.03 cm). Overall echogenicity is slightly hyperechoic with poor corticomedullary distinction and a typical 1:3 cortex:medulla ratio. There is no evidence of focal perinephric inflammation or effusion. There is no evidence of nephroliths, infarcts or hydroureter. Renal vasculature is normal. Numerous small cortical cysts are noted, the largest measuring 0.82 cm. Mild pyelectasia is present, measuring 0.27 cm.

HOSPITAL NAME

Timonium AH

Adrenal Glands

The left adrenal gland is normal/borderline small in size measuring 0.4 cm at the caudal pole. It is observed in its normal position cranial to the left renal artery. It is normal in appearance (uniformly hypoechoic) and shape with no evidence of a mass effect.

REFERRING VET

Dr. Brand

The right adrenal gland is normal/borderline small in size measuring 0.39 cm at the caudal pole. It is observed in its normal position between the cranial aspect of the right kidney and the caudal vena cava. It is normal in appearance (uniformly hypoechoic) and shape with no evidence of a mass effect.

INVOICE

20117

Spleen

The spleen is subjectively normal in size, echotexture is homogenous, and the splenic capsule is smooth with no irregularities. The blood flow through the hilus and splenic parenchyma appears normal. No focal parenchymal abnormalities are visualized.

Liver

The liver is subjectively large in size with smooth peripheral margins. The parenchyma is hyperechoic and homogenous in echotexture. The visible portions of the vasculature and biliary tract appear normal. No focal nodules or cystic lesions are observed.

The gall bladder lumen is significantly distended. Some areas of the wall appear mildly thickened with adherent debris. There is a large amount of primarily non-organized echogenic debris. There is no evidence of bile duct dilation.

Gastrointestinal

The stomach contains minimal luminal contents. It measures at a normal thickness of <0.7cm with some variability due to the presence of rugal folds. The distinction of the gastric wall layers is adequate and there is no impression of reduced peristaltic activity. No masses or focal lesions were observed.

The visualized areas of duodenum, jejunum and ileum have a relatively uniform diameter with minimal fluid distension. Wall thickness is normal. Bowel loops follow a curvilinear path with distinct wall layering maintaining the typical 1:3 muscularis:mucosa layer ratio. The duodenum measured as normal (0.5 cm in wall thickness) and the jejunum measured as normal (0.38 cm). Visualized peristalsis appears appropriate. There were no focal lesions consistent with obstruction or a mass effect observed.

The ileocecal junction was visualized and exhibited normal intact wall layering and is subjectively of normal thickness. Sections of colon are visualized with formed fecal material and gas shadowing distally. There is no observed focal or generalized colon wall thickening or loss of layering.

Pancreas

The pancreas is normal and isoechoic to surrounding mesentery. There is no evidence of nodules or cystic lesions. There is no evidence of regional mesenteric inflammation or fluid.

Free Abdomen

Evaluation of the peritoneal cavity did not reveal any evidence of effusion, or subjective lymphadenomegaly. The Medial iliac nodes appear normal and there was no evidence of a caudal aortic thrombus at the bifurcation. The omentum is of normal uniform echogenicity.

ULTRASONOGRAPHIC FINDINGS

Primary Findings

- Decreased corticomedullary distinction in both kidneys with numerous cortical cysts and pyelectasia bilaterally. Mild loss of corticomedullary distinction in both kidneys could be consistent with chronic degenerative disease or interstitial nephrosis. Pyelectasia of the kidneys could be consistent with pyelonephritis, chronic renal disease, secondary to PU/PD or fluid therapy (if applicable), other.
- Large hyperechoic liver. The diffuse hepatic changes are non-specific and can be seen with vacuolar hepatopathy, reactive change, nodular hyperplasia or, less likely, inflammatory/immune-mediated disease, infiltrative neoplasia, or other hepatopathy.
- Large gallbladder debris. A large amount of debris is evident in the gall bladder with no evidence of a mucocele or associated inflammation at this time. This could represent an early mucocele or cholestasis, with minimal evidence of associated inflammation at this time. Continued monitoring of lab work and ultrasound are warranted for progression of this lesion. Ursodiol therapy could be considered.

Secondary Findings

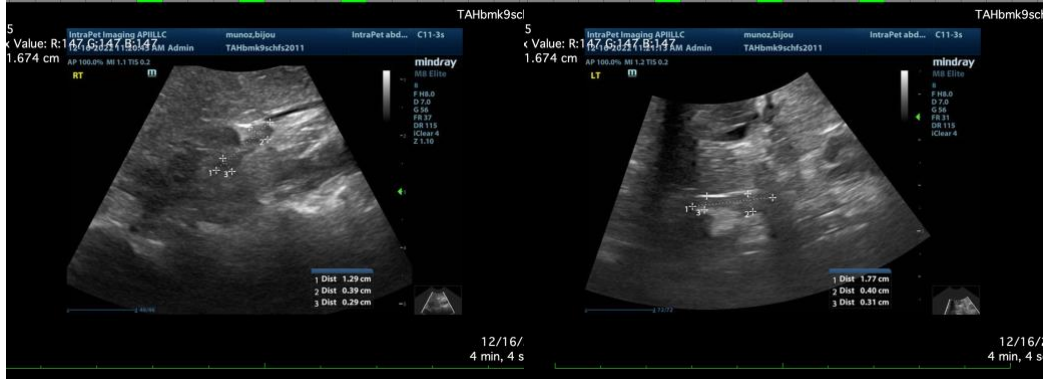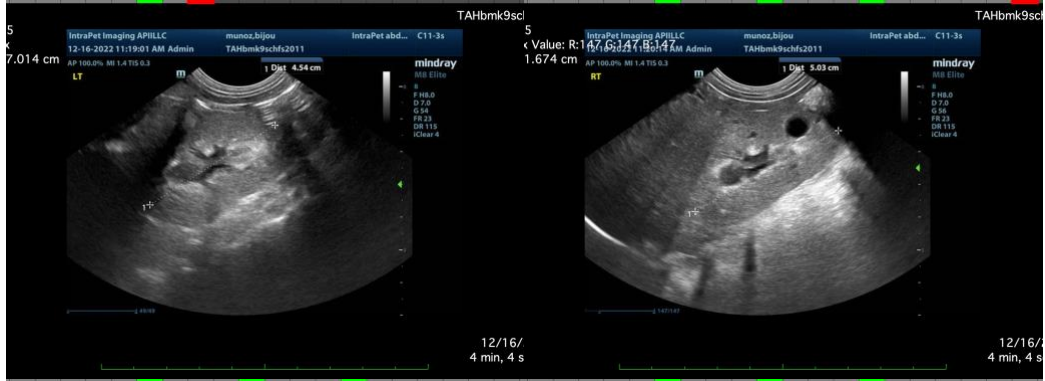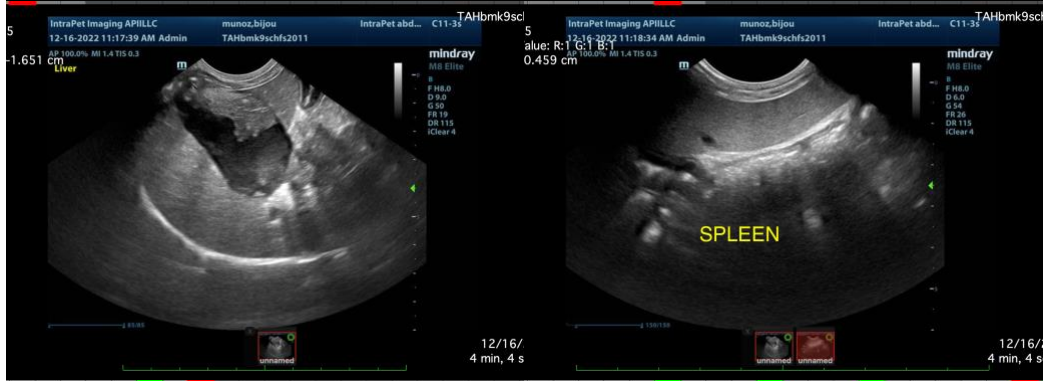
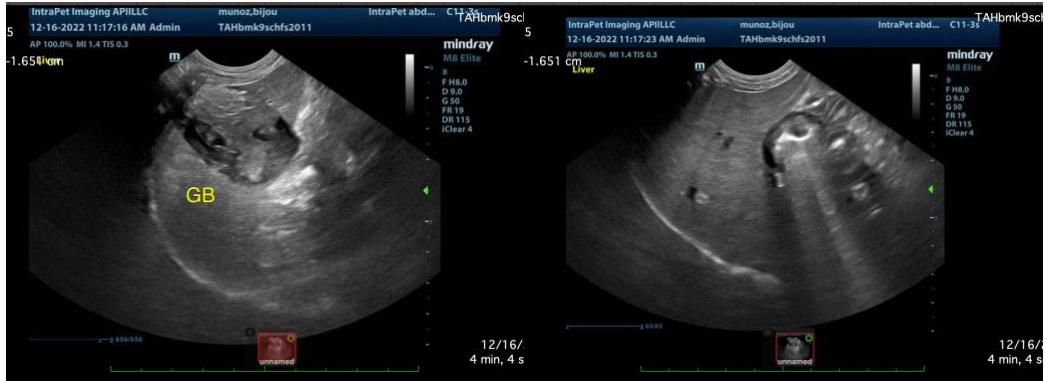
- Borderline small adrenals. This is likely within normal limits for such a small schnauzer.

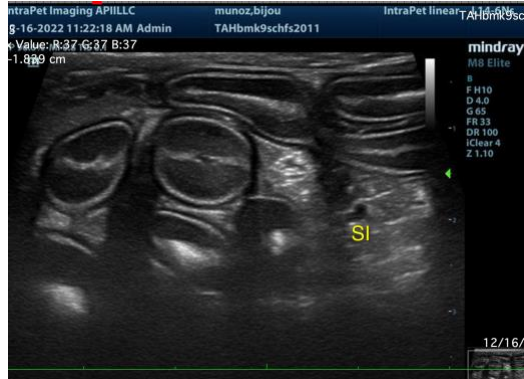INTERPRETATION OF THE FINDINGS & FURTHER RECOMMENDATIONS

Both kidneys show decreased corticomedullary distinction with cortical cysts and bilateral pyelectasia. These findings are most consistent with chronic progressive age-related renal disease and could be consistent with the protein losing nephropathy described.

The liver is large and hyperechoic. No focal lesions are visualized but the gallbladder has a large amount of intraluminal debris with minimal surrounding inflammation. This could be consistent with a breed associated vacuolar hepatopathy. Consider a liver function test +/- fine needle aspirate and therapy and treatment of the gallbladder. These are my general recommendations for further evaluation of a patient with primary ALP elevation.

- Induction phenomena are the most common cause for an elevation in ALP. These are systemic illnesses that 'turn on' the liver enzyme. Causes of this include Cushing's disease, dental disease, arthritis, and numerous others. In many cases the exact cause is unclear but as long as ultrasound and bile acids tests are normal most patients do not have progressive changes in their liver. While liver biopsy is not routinely performed, vacuolar hepatopathy, is noted on most biopsies. This is often non-progressive but in rare cases can be more severe and lead to liver failure.
- If signs of Cushing's disease are present recommend endocrine function testing to evaluate for Cushing's disease.
- Consider fine needle aspirate to rule out round cell neoplasia -if this is a concern.
- If a cause for the ALP elevation is not identified: I recommend recheck general blood work every 6 months, ultrasound once per year, and bile acids test every 1-2 years based on other results. If the ALP continues to climb a biopsy could be considered.
- Consider long term use of Denamarin, and monitoring for the signs of Cushing's developing.
- A primary vacuolar hepatopathy can be breed related and is seen in Scottish Terriers, Schnauzers, Cocker spaniels etc.





The information and recommendations provided are based on the images presented by the referring veterinarian. No evaluation can be communicated regarding pathology that was not visible in the image/video clips provided.

Thank you for this referral. If the clinical or image interpretation does not parallel your findings or if I can be of any further assistance please contact me.

Kathleen Sennello DVM,MS, Diplomate ACVIM (Small animal Internal Medicine)
kathleen.sennello@sonopath.com