



DATE PRESENTING CLINICAL SIGNS

12/16/21 History: Coughing Gagging, hyporexia Crackles on auscultation Grade IV/VI murmur, Hepatomegaly.

PATIENT Current Medications: Furosemide 12.5 mg BID, Vetmedin 1.25 mg BID, Clavamox 125 1 BID, Denamarin Small; 1 daily....(Enalapril possible in the near future).

Peanut Grant Lab Results: ALk Phos 500+ ALT 4995, WBC 36,000 w Neutrophilia and Bands.
Date of Previous IntraPet Ultrasound: No previous IntraPet scans.

SPECIES Sedation: Not required for a full diagnostic ultrasound.
Stat Report: Not requested.

Canine

ULTRASONOGRAPHIC EXAMINATION OF THE ABDOMEN

BREED *Urinary System*

Chihuahua The urinary bladder is moderately distended with anechoic urine. The Bladder wall, trigone, ureteral papillae and visible urethra (to a depth of 2cm) appear normal with no evidence of wall thickening, mucosal irregularities, masses or cystic calculi.

SEX

Neutered Male The prostate is normal in size (0.86 cm) and shape for this neutered male dog. The parenchyma is homogenous and the external margins are smooth. The prostatic urethra appears normal with no evidence of irregularity, invasion, mass effect or calculi.

AGE

7/4/10 The left kidney has a normal shape and size (4.22 cm) with small non-obstructive nephroliths. Overall echogenicity is slightly hyperechoic with mildly reduced corticomedullary distinction and a typical 1:3 cortex:medulla ratio. There is no evidence of perinephric inflammation or effusion. There is no evidence of pyelectasia, infarcts or hydroureter. Renal vasculature is normal.

WEIGHT

12 Pounds

INTERPRETED BY

Kathleen Sennello DVM,
MS, Diplomate ACVIM
(Small Animal Internal
Medicine)

The right kidney has a normal shape and size (4.01 cm) with small non-obstructive nephroliths.. Overall echogenicity is slightly hyperechoic with mildly reduced corticomedullary distinction and a typical 1:3 cortex:medulla ratio. There is no evidence of perinephric inflammation or effusion. There is no evidence of pyelectasia, nephroliths, infarcts or hydroureter. Renal vasculature is normal.

Adrenal Glands

The left adrenal gland is normal in size measuring 0.41 cm at the caudal pole. It is observed in its normal position cranial to the left renal artery. It is normal in appearance (uniformly hypoechoic) and shape with no evidence of a mass effect.

IMAGING PERFORMED BY

Stephanie Pearce
RDMS, RVT

The right adrenal gland is normal in size measuring 0.59 cm at the caudal pole. It is observed in its normal position between the cranial aspect of the right kidney and the caudal vena cava. It is normal in appearance (uniformly hypoechoic) and shape with no evidence of a mass effect.

HOSPITAL NAME

North Laurel AH

Spleen

The spleen is subjectively normal in size, echotexture is homogenous, and the splenic capsule is smooth with no irregularities. The blood flow through the hilus and splenic parenchyma appears normal. No focal parenchymal abnormalities are visualized.

REFERRING VET

Dr. Cohn

Liver

The liver is large in size, and normal in echogenicity with smooth peripheral margins. The parenchyma is heterogenous in echotexture with subtle, indistinct focal mottling. The visible portions of the vasculature and biliary tract appear normal. There are numerous ill-defined, hypoechoic nodules visualized within the parenchyma, one measuring 0.52 cm x 0.6 cm. In general, they range from approximately 0.3-1.0 cm in size.

INVOICE

33513

The gall bladder lumen is moderately distended. The wall of the gall bladder is not thickened and has a smooth mucosal surface. There is a moderate amount of non-organized echogenic debris. The cystic and common bile ducts are normal/not visible.

Gastrointestinal

The stomach is moderately dilated with fluid and irregular shadowing material most consistent with normal ingesta and gas. It measures at a normal thickness of <0.7cm with some variability due to the presence of rugal folds. The distinction of the gastric wall layering is adequate and there is no impression of reduced peristaltic activity. No masses or focal lesions were observed.

The visualized areas of duodenum, jejunum and ileum have a relatively uniform diameter with minimal fluid distension. Wall thickness is normal. Bowel loops follow a curvilinear path with distinct wall layering maintaining the typical 1:3 muscularis:mucosa layer ratio. Duodenum wall measured 0.38 cm. Jejunum wall measured 0.19 cm. Visualized peristalsis appears appropriate. There were no focal lesions consistent with obstruction or a mass effect observed.

The ileocecal junction was visualized and exhibited normal intact wall layering and is subjectively of normal thickness. Sections of colon are visualized with formed fecal material and gas shadowing distally. There is no observed focal or generalized colon wall thickening or loss of layering.

Pancreas

The pancreas is normal and isoechoic to surrounding mesentery. There is no evidence of nodules or cystic lesions. There is no evidence of regional mesenteric inflammation or fluid.

Free Abdomen

Evaluation of the peritoneal cavity did not reveal any evidence of effusion, or subjective lymphadenomegaly. The Medial iliac nodes appear normal and there was no evidence of a caudal aortic thrombus at the bifurcation. The omentum is of normal uniform echogenicity.

ULTRASONOGRAPHIC FINDINGS

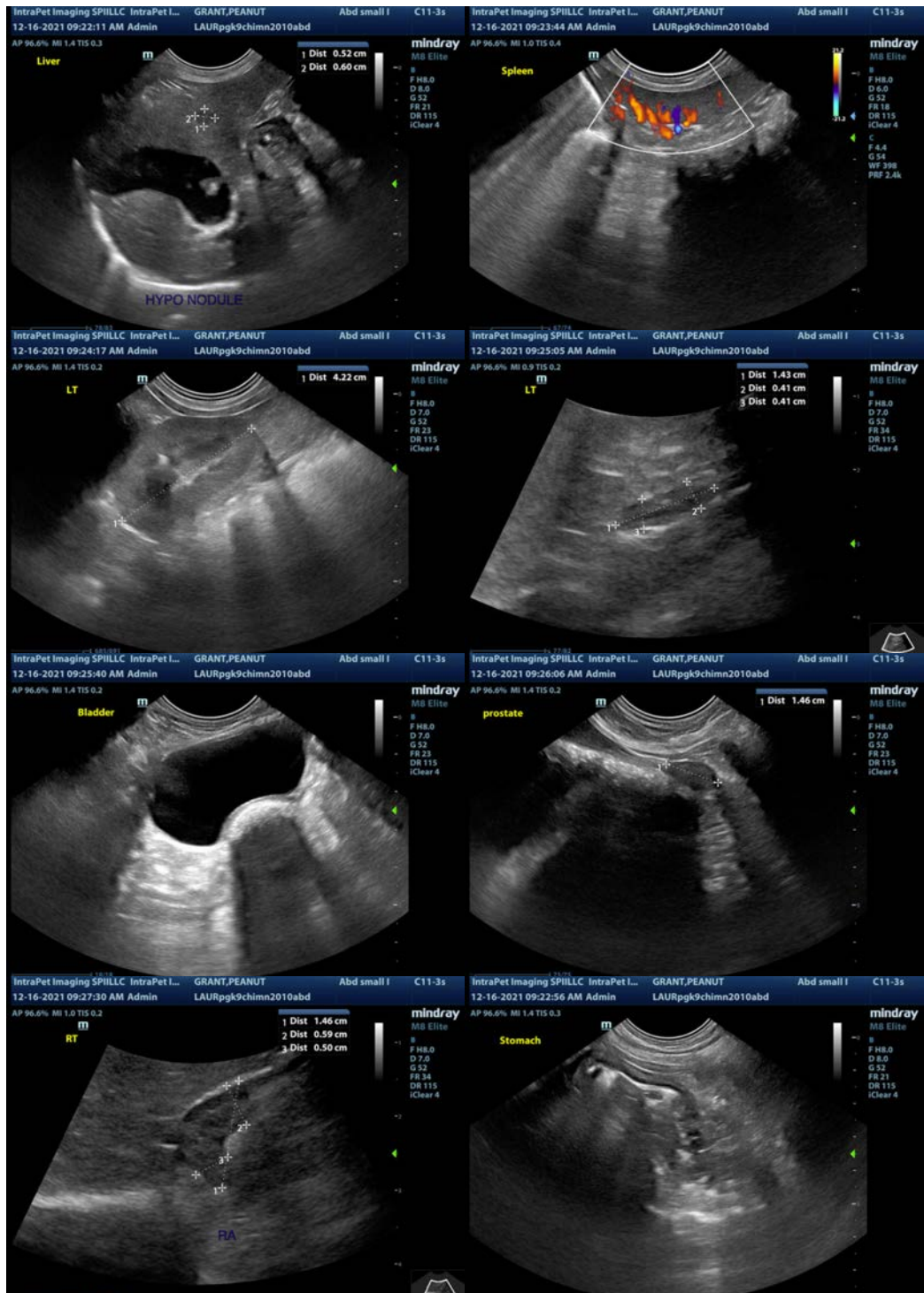
- Large, heterogeneous liver with ill-defined, hypoechoic nodules – The diffuse hepatic changes are non-specific and could be consistent with vacuolar hepatopathy, nodular hyperplasia, inflammatory/immune-mediated disease, fibrosis, extramedullary hematopoiesis, toxic hepatopathy (e.g., copper), infiltrative neoplasia (less likely) or other hepatopathy. The ill-defined nodules have a somewhat benign appearance, although an underlying neoplastic process cannot be ruled out.
- Moderate gallbladder sludge – The significance of the aggregated gallbladder sludge is unclear. This could represent an early mucocele, cholestasis, or may be secondary to fasting.

INTERPRETATION OF THE FINDINGS & FURTHER RECOMMENDATIONS

Given the significant lab work changes reported in the history, the ultrasonographic lesions appear relatively mild. Unfortunately, the sonographic changes do not always correlate with the clinical picture. The liver changes are relatively non-specific. If the bilirubin is normal:

- Consider pre- and post-prandial bile acids to assess liver function.
- Consider a fine needle aspirate of the liver.
- Recommend testing for Leptospirosis.
- Recommend supportive medical therapy with Denamarin, antibiotics +/- Ursodiol and close monitoring. If there is no improvement, then consider liver biopsy for histopathology, culture and copper levels.

Given the elevated white blood cell count, I was expecting to see significant pancreatitis or an abnormal gallbladder, etc., but this was not the case. Consider other possibilities such as drug reaction, toxins, etc., and evaluate chest radiographs for possible pneumonia/pulmonary infection.



The information and recommendations provided are based on the images presented by the referring veterinarian. No evaluation can be communicated regarding pathology that was not visible in the image/video clips provided.

Thank you for this referral. If the clinical or image interpretation does not parallel your findings or if I can be of any further assistance please contact me.

Kathleen Sennello DVM,MS, Diplomate ACVIM (Small animal Internal Medicine)
kathleen.sennello@sonopath.com