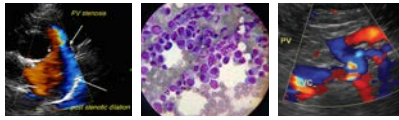


IMAGING PERFORMED BY

IntraPet.com



SonoPath

Clinical Sonography & Telecytology

EDUCATIONAL TELECONSULTATION SERVICES™

1-800-838-4268 info@sonopath.com SonoPath.com

DATE PRESENTING CLINICAL SIGNS

12/15/21

History: For the past year, P has had intermittent vomiting; will vomit 3 - 4 times per day every few weeks; P is otherwise doing well. P was diagnosed w/ diabetes two years ago and has been well managed with Glargine 4U BID.

PATIENT

Bandit Gerner

Current Medications: Glargine 4U SQ q 12 hrs.
Date of Previous IntraPet Ultrasound: No previous IntraPet scans.
Sedation: DKT.
Stat Report: Not requested.

SPECIES

Feline

ULTRASONOGRAPHIC EXAMINATION OF THE ABDOMEN

BREED

DSH

Urinary System

The urinary bladder is moderately distended with anechoic urine. The Bladder wall, trigone, ureteral papillae and visible urethra (to a depth of 2cm) appear normal with no evidence of wall thickening, mucosal irregularities, masses or cystic calculi.

SEX

Neutered Male

The left kidney has a normal shape and size (4.86 cm). Overall echogenicity is normal with adequate corticomedullary distinction and a typical 1:3 cortex:medulla ratio. There is no evidence of perinephric inflammation or effusion. There is no evidence of pyelectasia, nephroliths, infarcts or hydroureter. Renal vasculature is normal.

AGE

6/30/14

The right kidney has a normal shape and size (4.42 cm) with a 0.37 cm non-obstructive nephrolith. Overall echogenicity is normal with adequate corticomedullary distinction and a typical 1:3 cortex:medulla ratio. There is no evidence of perinephric inflammation or effusion. There is no evidence of pyelectasia, infarcts or hydroureter. Renal vasculature is normal.

WEIGHT

18.7 Pounds

Adrenal Glands

The left adrenal gland is normal in size measuring 0.45 cm at the caudal pole. It is observed in its normal position cranial to the left renal artery. It is normal in appearance (uniformly hypoechoic) and shape with no evidence of a mass effect.

INTERPRETED BY

Kathleen Sennello DVM,
MS, Diplomate ACVIM
(Small Animal Internal
Medicine)

The right adrenal gland is normal in size measuring 0.50 cm at the caudal pole. It is observed in its normal position between the cranial aspect of the right kidney and the caudal vena cava. It is normal in appearance (uniformly hypoechoic) and shape with no evidence of a mass effect.

IMAGING PERFORMED BY

Stephanie Pearce
RDMS, RVT

Spleen

The spleen is subjectively normal in size, echotexture is homogenous, and the splenic capsule is smooth with no irregularities. The blood flow through the hilus and splenic parenchyma appears normal. No focal parenchymal abnormalities are visualized.

HOSPITAL NAME

Charm City VH

Liver

The liver is subjectively normal in size, and echogenicity with smooth peripheral margins. The parenchyma is homogenous echotexture. The visible portions of the vasculature and biliary tract appear normal. No focal nodules or cystic lesions are observed.

REFERRING VET

Dr. Karbonik

The gallbladder lumen is moderately distended. The wall of the gall bladder is not thickened and has a smooth mucosal surface. Luminal contents are primarily anechoic. The cystic and common bile ducts are normal/not visible.

INVOICE

33467

Gastrointestinal

The stomach is moderately dilated with fluid and irregular shadowing material most consistent with normal ingesta/fluid. It measures at a normal thickness of <0.36cm with some variability due to the presence of rugal

folds. The distinction of the gastric wall layering is adequate and there is no impression of reduced peristaltic activity. No masses or focal lesions were observed.

The visualized areas of duodenum, jejunum and ileum have a uniform diameter with minimal fluid distension. Wall thickness is normal to slightly increased. Bowel loops follow a typical curvilinear path with distinct wall layering, but some areas display a prominent muscularis layer which does not display the typical 1:3 muscularis:mucosa layer ratio. Duodenum wall measured 0.24 cm. Jejunum wall measured 0.27 cm. Visualized peristalsis appears appropriate. There were no focal lesions consistent with obstruction or a mass effect observed.

The ileocecal junction was visualized and exhibited normal intact wall layering and is subjectively of normal thickness. Sections of colon are visualized with formed fecal material and gas shadowing distally. There is no observed focal or generalized colon wall thickening or loss of layering.

Pancreas

The pancreas is normal and isoechoic to surrounding mesentery. There is no evidence of nodules or cystic lesions. There is no evidence of regional mesenteric inflammation or fluid.

Free Abdomen

Evaluation of the peritoneal cavity did not reveal any evidence of effusion. There is a significant cluster of prominent mesenteric lymph nodes, particularly in the area of the ileocecal junction, measuring 0.46, 0.42, 0.32, 0.65 cm. The omentum is of increased echogenicity, particularly around the ileocecal junction.

PRIMARY FINDINGS

- Thickened small intestine with prominent muscularis layer – The bowel wall thickening could be consistent with inflammation, edema, or infiltrative neoplasia.
- Mesenteric lymphadenopathy – The prominent abdominal lymph nodes are most consistent with reactive lymphadenitis or lymphoid hyperplasia. Neoplastic infiltration is considered less likely.

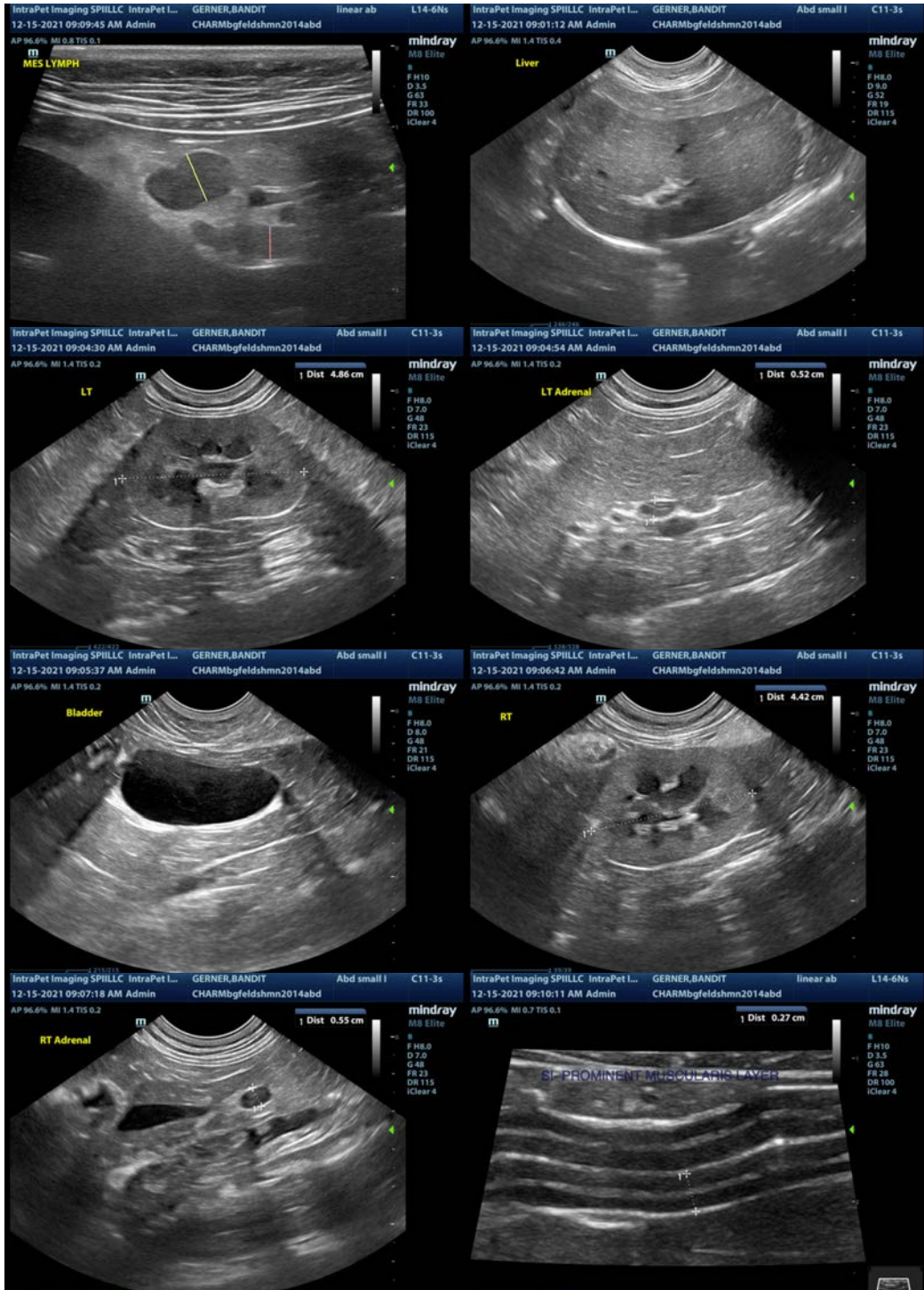
SECONDARY FINDINGS

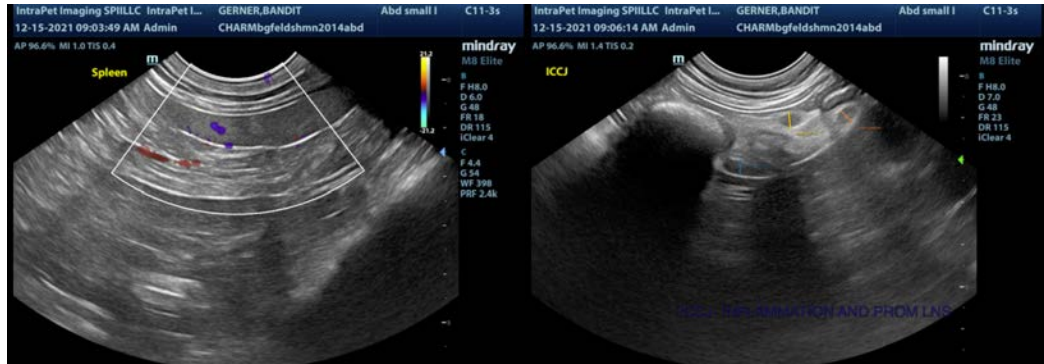- Small non-obstructive nephrolith in the right kidney – The hyperechoic mineralized foci observed at the corticomedullary junction of the right kidney are consistent with small, non-obstructive nephroliths.

INTERPRETATION OF THE FINDINGS & FURTHER RECOMMENDATIONS

No significant changes were observed associated with the stomach. There is some mild fluid retention/ingesta, but no focal lesions are observed. The small intestine appears somewhat thickened with a very prominent muscularis layer, and there is a focal cluster of inflammation and mesenteric lymph nodes around the ileocecal junction. This is suggestive of underlying inflammation, and an underlying neoplastic process cannot be entirely ruled out. Possible differentials for primary GI disease in this situation would be parasitism, dietary indiscretion, mild pancreatitis, bacterial dysbiosis, food allergy, IBD, and less likely intestinal neoplasia. Consider:

- GI panel to Texas A&M for a qualitative fPLI, TLI, cobalamin and folate to further evaluate for any evidence of pancreatic disease (none observed here) or small intestinal disease.
- Consider a novel protein or hydrolyzed protein prescription diet.
- If symptoms persist despite a diet change, etc., then I would consider obtaining GI biopsies either via endoscopy or surgery. I suspect the lymph nodes are too deep/small to sample for a fine needle aspirate.





The information and recommendations provided are based on the images presented by the referring veterinarian. No evaluation can be communicated regarding pathology that was not visible in the image/video clips provided.

Thank you for this referral. If the clinical or image interpretation does not parallel your findings or if I can be of any further assistance please contact me.

Kathleen Sennello DVM,MS, Diplomate ACVIM (Small animal Internal Medicine)
kathleen.sennello@sonopath.com