

IMAGING PERFORMED BY

IntraPet.com



SonoPath

Clinical Sonography & Telecytology

EDUCATIONAL TELECONSULTATION SERVICES™

1-800-838-4268 info@sonopath.com SonoPath.com

DATE PRESENTING CLINICAL SIGNS

12/14/22 History of renal disease that has been stable, but now evident weight loss. Hyperthyroidism ruled out with a free T4 in normal reference interval

PATIENT

Rosa Glazier Current Medications: Viralys (Lysine) Powder 3.5oz - 1 scoop into food BID
Date of Previous IntraPet Ultrasound: No previous.
Sedation: Not required to complete full diagnostic ultrasound.
Stat Report: Not requested.

SPECIES

Feline

ULTRASONOGRAPHIC EXAMINATION OF THE ABDOMEN

BREED

DSH

Urinary System

The urinary bladder is moderately distended with anechoic urine. The Bladder wall, trigone, ureteral papillae and visible urethra (to a depth of 2cm) appear normal with no evidence of wall thickening, mucosal irregularities, masses or cystic calculi.

SEX

Spayed Female

The left kidney is irregular shape (likely due to previous infarct) and slightly small, measuring 0.23 cm. Overall echogenicity is slightly hyperechoic with poor corticomedullary distinction and a typical 1:3 cortex:medulla ratio. There is no evidence of focal perinephric inflammation or effusion. There is no evidence of pyelectasia, nephroliths or hydroureter. Renal vasculature is normal.

AGE

10/18/09

Overall echogenicity is slightly hyperechoic with mildly reduced corticomedullary distinction and a typical 1:3 cortex:medulla ratio. There is no evidence of focal perinephric inflammation or effusion. There is no evidence of pyelectasia, nephroliths or hydroureter. Renal vasculature is normal.

WEIGHT

8.34 Pounds

Adrenal Glands

The region of left adrenal (Cranial to left renal artery) is unremarkable but the adrenal is not distinctly visualized. No evidence of a mass effect.

INTERPRETED BY

Kathleen Sennello DVM,
MS, Diplomate ACVIM
(Small Animal Internal
Medicine)

The region of the right adrenal (between right cranial kidney and vena cava) is unremarkable, but the adrenal is not distinctly visualized. No evidence of a mass effect.

IMAGING PERFORMED BY

Andi Parkinson RDMS

Spleen

The spleen is borderline large (1.0 cm), echotexture is homogenous, and the splenic capsule is smooth with no irregularities. The blood flow through the hilus and splenic parenchyma appears normal. No focal parenchymal abnormalities are visualized.

HOSPITAL NAME

Taylorsville VC

Liver

The liver is subjectively normal in size, and echogenicity with smooth peripheral margins. The parenchyma is homogenous echotexture. The visible portions of the vasculature and biliary tract appear normal. No focal nodules or cystic lesions are observed.

REFERRING VET

Dr. Lucas

The gallbladder lumen is moderately distended. The wall of the gall bladder is not thickened and has a smooth mucosal surface. Luminal contents are mild and primarily anechoic. The cystic and common bile ducts are normal/not visible.

INVOICE

43452

Gastrointestinal

The stomach contains minimal luminal contents. It measures at a normal thickness of <0.36cm with some variability due to the presence of rugal folds. The distinction of the gastric wall layers is adequate and there is no impression of reduced peristaltic activity. No masses or focal lesions were observed.

The visualized areas of duodenum, jejunum and ileum have a relatively uniform diameter with minimal fluid distension. Wall thickness is normal. Bowel loops follow a curvilinear path with distinct wall layering maintaining the typical 1:3 muscularis:mucosa layer ratio. Jejunum wall measures 0.23 cm. Visualized peristalsis appears appropriate. There is a section of small bowel that appears to have an isoechoic non-shadowing rounded structure visualized within the lumen measuring approximately 0.75 cm x 0.56 cm. There is mild bowel dilation in this area but there does not appear to be a complete obstruction. Proximal to this intraluminal structure is intraluminal shadowing material within the bowel, which could represent partially obstructed foreign material.

The ileocecal junction was visualized and exhibited normal intact wall layering and is subjectively of normal thickness. Sections of colon are visualized with formed fecal material and gas shadowing distally. There is no observed focal or generalized colon wall thickening or loss of layering.

Pancreas

The pancreas is prominent and hypoechoic as compared to the surrounding isoechoic mesentery. There is no evidence of nodules or cystic lesions. There is no evidence of regional mesenteric inflammation or fluid.

Free Abdomen

Evaluation of the peritoneal cavity did not reveal any evidence of effusion, or subjective lymphadenomegaly. The Medial iliac nodes appear normal and there was no evidence of a caudal aortic thrombus at the bifurcation. The omentum is of normal uniform echogenicity.

ULTRASONOGRAPHIC FINDINGS

- Small, irregular left kidney and larger, irregular right kidney with mildly reduced corticomedullary distinction – Mild loss of corticomedullary distinction in both kidneys could be consistent with chronic degenerative disease or interstitial nephrosis. The solitary renal lesion identified is ill defined and hyperechoic, this could be consistent with a previous renal infarct and can be an indicator of current or previous renal disease.
- Prominent, hypoechoic pancreas – The pancreatic changes are most consistent with mild pancreatitis or a recent episode of pancreatic inflammation.
- Non-shadowing intraluminal structure visualized within the small intestine, shadowing material visualized proximal to this lesion – The intraluminal material could represent a mass lesion or non-shadowing foreign material. The shadowing material proximal to this lesion is likely an accumulation of material, possibly a partial obstruction.

INTERPRETATION OF THE FINDINGS & FURTHER RECOMMENDATIONS

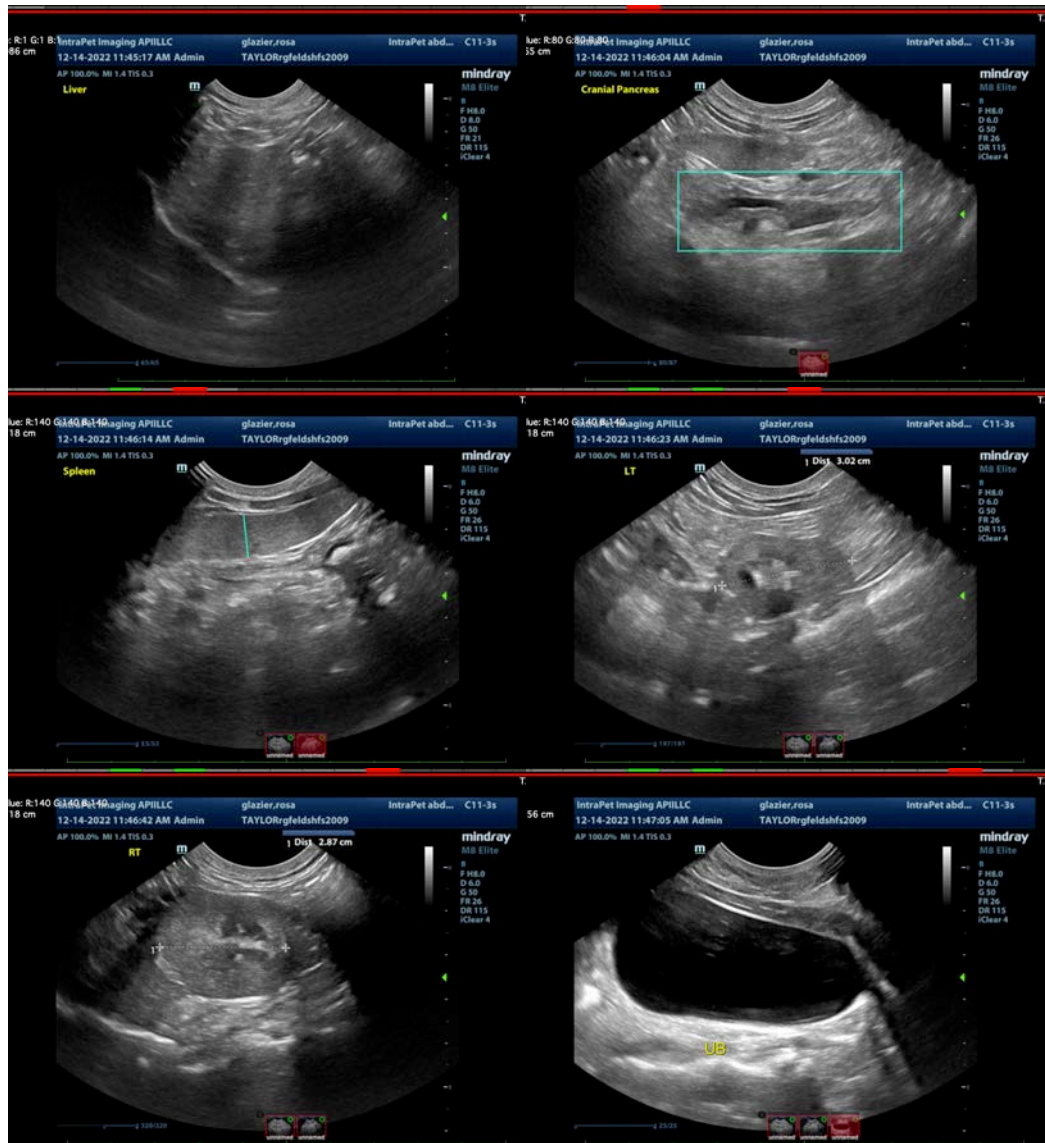
There is a rounded structure visualized within the small intestinal lumen that is non-shadowing. This could represent soft tissue. There is no significant change to the bowel wall in this region, so this could be a benign or neoplastic lesion. Additionally, this could be non-shadowing intraluminal material. There is shadowing material proximal to this lesion, which is likely accumulating, creating a mild, partial obstruction.

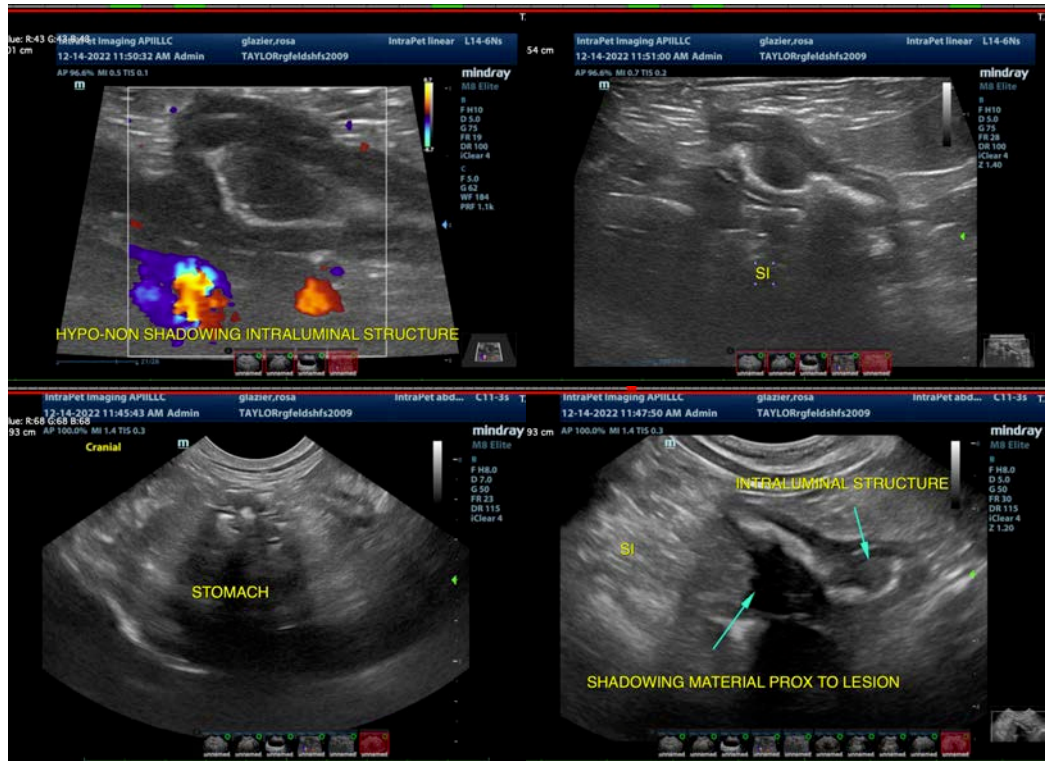
Options moving forward include surgical evaluation of this area and at the same time obtaining biopsies of the stomach, duodenum, jejunum, and ileum to look for more diffuse small intestinal disease. Alternately, if the patient is stable, you could consider medical therapy and reevaluation of this region in 12-24 hours to see if the lesion persists.

Both kidneys appear slightly irregular in shape, the left kidney more so than the right, and the left kidney is smaller. This is likely due to the chronic progressive renal disease described and previous infarcts.

The spleen measures as slightly enlarged but has a relatively normal appearance. Recommend continued monitoring. If round cell neoplasia is of concern, then a fine needle aspirate could be considered.

Recommend three view thoracic radiographs to evaluate for possible concurrent thoracic disease/involvement.





The information and recommendations provided are based on the images presented by the referring veterinarian/sonographer. No evaluation can be communicated regarding pathology that was not visible in the image/video clips provided.

Thank you for this referral. If the clinical or image interpretation does not parallel your findings or if I can be of any further assistance please contact me.

Kathleen Sennello DVM,MS, Diplomate ACVIM (Small animal Internal Medicine)
 kathleen.sennello@sonopath.com