

**DATE PRESENTING CLINICAL SIGNS**

12/14/21

History: Intermittent vomiting. Hx of mass effect in cranial abdomen. Elevated ALT, tBili, BUN, Albumin. Otherwise doing well at home.

PATIENT

Tucker Blume

Current Medications: Starting Denamarin Advanced on 12/4/2021.

Lab Results: ALT elevated (167)- historically has been elevated intermittently, BUN elevated (31), TBil elevated (2.3), Albumin elevated (4.4).

SPECIES

Canine

Date of Previous IntraPet Ultrasound: No previous IntraPet scans.

Sedation: Not required to complete full diagnostic ultrasound.

Stat Report: Not requested.

BREED

Chihuahua X

ULTRASONOGRAPHIC EXAMINATION OF THE ABDOMEN**Urinary System**

The urinary bladder is moderately distended with anechoic urine. The Bladder wall, trigone, ureteral papillae and visible urethra (to a depth of 2cm) appear normal with no evidence of wall thickening, mucosal irregularities, masses or cystic calculi.

SEX

Neutered Male

The prostate is normal in size (0.88 cm) and shape for this neutered male dog. The parenchyma is homogenous and the external margins are smooth. The prostatic urethra appears normal with no evidence of irregularity, invasion, mass effect or calculi.

AGE

4/13/19

The left kidney has a normal shape and size (4.06 cm). Overall echogenicity is normal with adequate corticomedullary distinction and a typical 1:3 cortex:medulla ratio. There is no evidence of perinephric inflammation or effusion. There is no evidence of pyelectasia, nephroliths, infarcts or hydroureter. Renal vasculature is normal.

WEIGHT

15.6 Pounds

The right kidney has a normal shape and size (3.85 cm). Overall echogenicity is normal with adequate corticomedullary distinction and a typical 1:3 cortex:medulla ratio. There is no evidence of perinephric inflammation or effusion. There is no evidence of pyelectasia, nephroliths, infarcts or hydroureter. Renal vasculature is normal.

INTERPRETED BY

Kathleen Sennello DVM,
MS, Diplomate ACVIM
(Small Animal Internal
Medicine)

Adrenal Glands

The left adrenal gland is normal in size measuring 0.54 cm at the caudal pole. It is observed in its normal position cranial to the left renal artery. It is normal in appearance (uniformly hypoechoic) and shape with no evidence of a mass effect.

IMAGING PERFORMED BY

Rachel Brilhart RDMS

The right adrenal gland is normal in size measuring 0.68 cm at the caudal pole. It is observed in its normal position between the cranial aspect of the right kidney and the caudal vena cava. It is normal in appearance (uniformly hypoechoic) and shape with no evidence of a mass effect.

HOSPITAL NAME

Greenbrier Vet Clinic

REFERRING VET

Dr. Whitfield

Spleen

The spleen is subjectively normal in size, echotexture is homogenous, and the splenic capsule is smooth with no irregularities. The blood flow through the hilus and splenic parenchyma appears normal. No focal parenchymal abnormalities are visualized.

INVOICE

33418

Liver

The liver is subjectively normal in size, and echogenicity with smooth peripheral margins. The parenchyma is heterogenous in echotexture with subtle, indistinct focal mottling. The visible portions of the vasculature and biliary tract appear normal. No focal nodules or cystic lesions are observed.

The gallbladder lumen is moderately distended. The wall of the gall bladder is not thickened and has a smooth mucosal surface. Luminal contents are primarily anechoic. The cystic and common bile ducts are normal/not visible.

Gastrointestinal

The stomach contains minimal luminal contents. It measures at a normal thickness of <0.7cm with some variability due to the presence of rugal folds. The distinction of the gastric wall layers is adequate and there is no impression of reduced peristaltic activity. No masses or focal lesions were observed.

The visualized areas of duodenum, jejunum and ileum have a uniform diameter with minimal fluid distension. Wall appears subjectively, mildly increased. Bowel loops follow a typical curvilinear path with distinct wall layering. Duodenum wall measured 0.4 cm. Jejunum wall measured 0.33 cm. There is mild mucosal speckling visualized. Visualized peristalsis appears appropriate. There were no focal lesions consistent with obstruction or a mass effect observed.

The ileocecal junction was visualized and exhibited normal intact wall layering and is subjectively of normal thickness. Sections of colon are visualized with formed fecal material and gas shadowing distally. There is no observed focal or generalized colon wall thickening or loss of layering.

Pancreas

The pancreas is prominent and mottled compared to the surrounding isoechoic mesentery. There is no evidence of nodules or cystic lesions. There is no evidence of regional mesenteric inflammation or fluid.

Free Abdomen

Evaluation of the peritoneal cavity did not reveal any evidence of effusion, or subjective lymphadenomegaly. The Medial iliac nodes appear normal and there was no evidence of a caudal aortic thrombus at the bifurcation. The omentum is of normal uniform echogenicity.

ULTRASONOGRAPHIC FINDINGS

- Prominent, mottled pancreas – The pancreatic changes are most consistent with mild pancreatitis or a recent episode of pancreatic inflammation.
- Mildly heterogeneous liver – The diffuse hepatic changes are non-specific and could be consistent with vacuolar hepatopathy, nodular hyperplasia, inflammatory/immune-mediated disease, fibrosis, extramedullary hematopoiesis, toxic hepatopathy (e.g., copper), infiltrative neoplasia (less likely) or other hepatopathy.
- Mucosal speckling visualized – Bright mucosal speckling has been proposed to represent dilated lacteals or focal accumulation of mucus, cellular debris etc.. in the mucosal crypts of the small intestine.

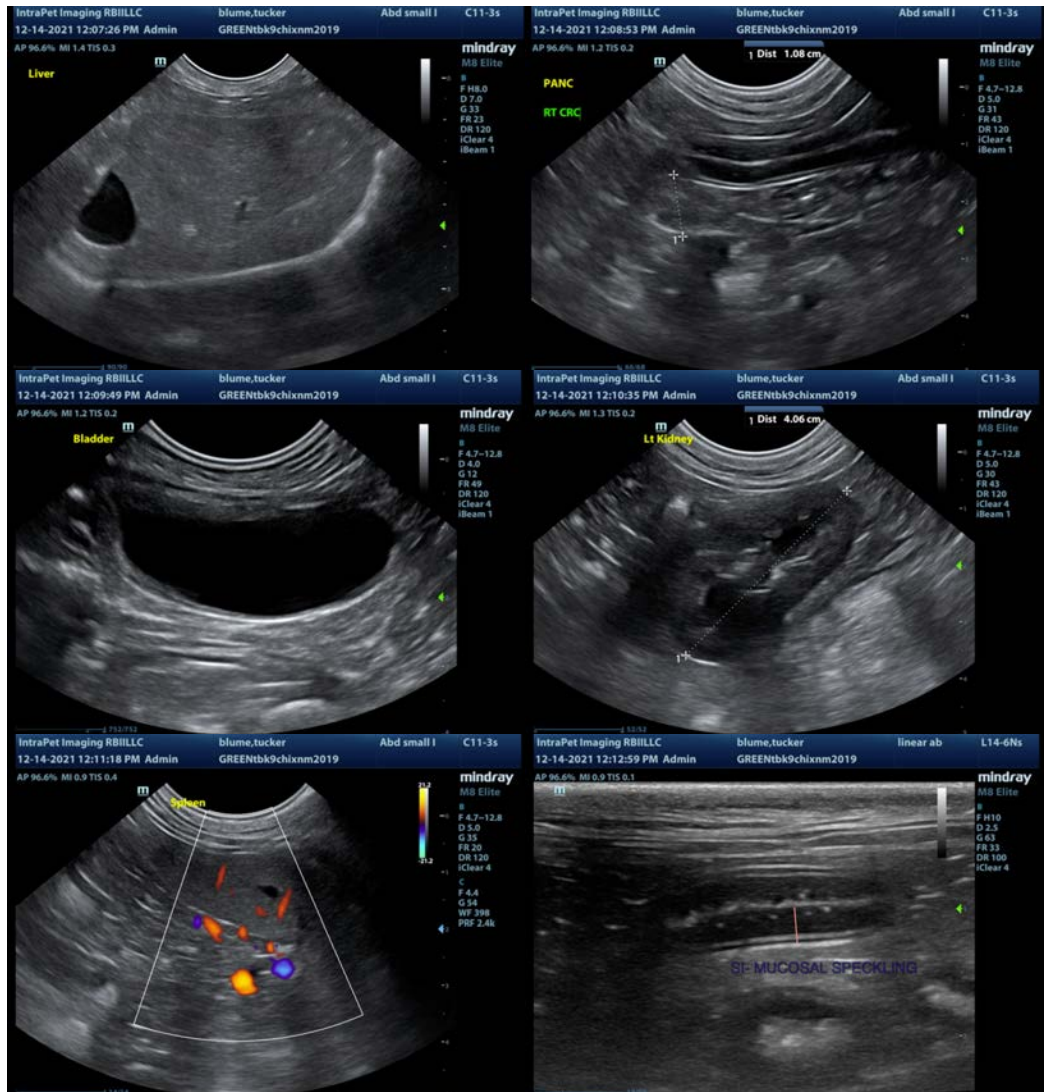
INTERPRETATION OF THE FINDINGS & FURTHER RECOMMENDATIONS

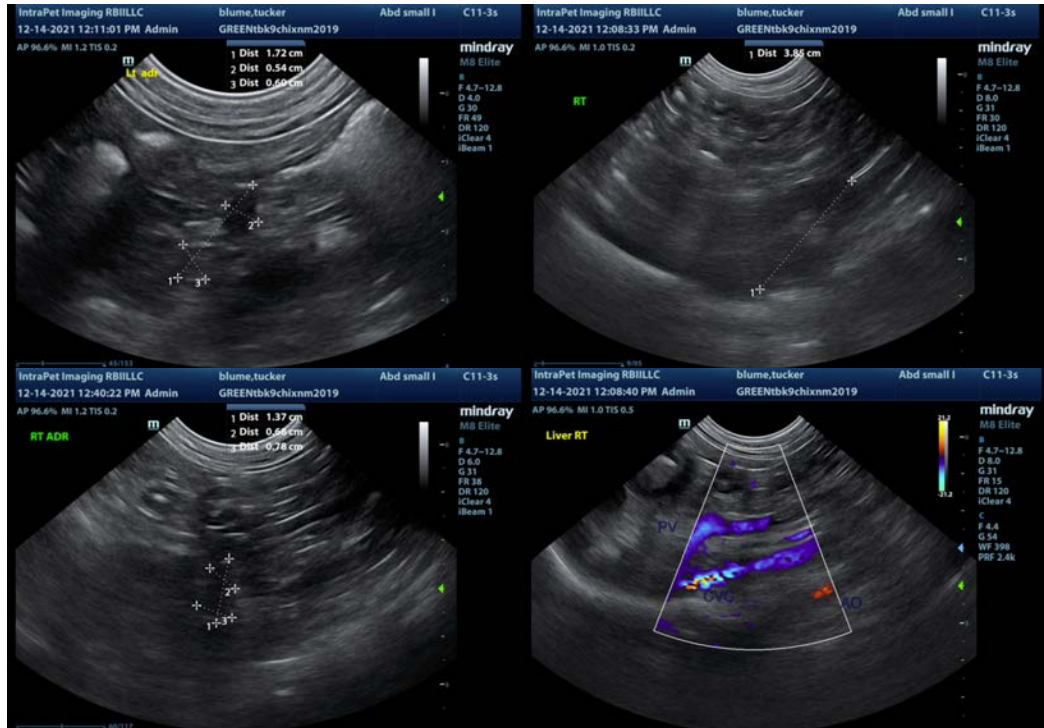
The ultrasonographic lesions visualized are relatively mild and non-specific. No focal lesions associated with the liver or the gallbladder visualized. The pancreatic changes are relatively subtle.

- Consider close evaluation of history for possible toxic changes examine medications, diet, dietary indiscretion etc...
- Consider PCR on urine/serum for leptospirosis (if not on antibiotics)/serology if recent antibiotic history
- If not already done, consider pre and post prandial bile acids to evaluate liver function

- Consider Fine needle aspirate if round cell neoplasia is on your differential list (25 g needle, normal coags)
- If no response to medical care (Denamarin +/- fluids +/- antibiotics, +/- ursodiol etc...) Consider liver biopsy with samples obtained for histopathology, culture, and copper levels.
- Consider a GI panel to Texas A&M for a quantitative PLI, TLI, cobalamin and folate to further evaluate the mottled, prominent pancreas and the small intestinal changes observed.

The changes visualized in the liver were not consistent with a liver shunt, but this could not be 100% ruled out. I think an inflammatory, infectious or toxic event is more likely. If liver biopsy is pursued, then consider getting samples of small intestine as well. Additionally, consider screening for Addison's disease and submitting a urine culture.





The information and recommendations provided are based on the images presented by the referring veterinarian. No evaluation can be communicated regarding pathology that was not visible in the image/video clips provided.

Thank you for this referral. If the clinical or image interpretation does not parallel your findings or if I can be of any further assistance please contact me.

Kathleen Sennello DVM,MS, Diplomate ACVIM (Small animal Internal Medicine)
 kathleen.sennello@sonopath.com