

IMAGING PERFORMED BY

IntraPet.com



SonoPath

Clinical Sonography & Telecytology

EDUCATIONAL TELECONSULTATION SERVICES™

1-800-838-4268 info@sonopath.com SonoPath.com

DATE PRESENTING CLINICAL SIGNS

12/14/21 History: neurologist requested to have an abdominal ultrasound done. (VNoC record attached separately).

PATIENT Current Medications: Potassium bromide- 1.25ml SID; Kepra.
Lab Results: Attached separately.

Jack Garrett Radiographs: Attached separately.
Date of Previous IntraPet Ultrasound: No previous IntraPet scans.

SPECIES Sedation: Not required to complete full diagnostic ultrasound.
Stat Report: Not requested.

Canine

ULTRASONOGRAPHIC EXAMINATION OF THE ABDOMEN

BREED ****Client declined limited chest exam.**

Shih Tzu

Urinary System

SEX

The urinary bladder is moderately distended with anechoic urine. The Bladder wall, trigone, ureteral papillae and visible urethra (to a depth of 2cm) appear normal with no evidence of wall thickening, mucosal irregularities, masses or cystic calculi.

Neutered Male

AGE

The prostate is normal in size (0.91 cm) and shape for this neutered male dog. The parenchyma is homogenous and the external margins are smooth. The prostatic urethra appears normal with no evidence of irregularity, invasion, mass effect or calculi.

5/28/13

WEIGHT

The left kidney has a normal shape and size (4.81 cm). Overall echogenicity is normal with adequate corticomedullary distinction and a typical 1:3 cortex:medulla ratio. There is no evidence of perinephric inflammation or effusion. There is no evidence of pyelectasia, nephroliths, infarcts or hydroureter. Renal vasculature is normal.

30 Pounds

INTERPRETED BY

Kathleen Sennello DVM,
MS, Diplomate ACVIM
(Small Animal Internal
Medicine)

The right kidney has a normal shape and size (5.37 cm). Overall echogenicity is normal with adequate corticomedullary distinction and a typical 1:3 cortex:medulla ratio. There is no evidence of perinephric inflammation or effusion. There is no evidence of pyelectasia, nephroliths, infarcts or hydroureter. Renal vasculature is normal.

IMAGING PERFORMED BY

Adrenal Glands

The left adrenal gland is normal in size measuring 0.66 cm at the caudal pole. It is observed in its normal position cranial to the left renal artery. It is normal in appearance (uniformly hypoechoic) and shape with no evidence of a mass effect.

Andi Parkinson RDMS

HOSPITAL NAME

The right adrenal gland is normal in size measuring 0.33 cm at the caudal pole. It is observed in its normal position between the cranial aspect of the right kidney and the caudal vena cava. It is normal in appearance (uniformly hypoechoic) and shape with no evidence of a mass effect.

AMC of Bel Air

REFERRING VET

Spleen

The spleen is subjectively normal in size. The spleen echotexture is heterogenous and mottled, the splenic capsule is smooth with no irregularities. The blood flow through the hilus and splenic parenchyma appears normal. There is a small, hypoechoic nodule visualized, measuring 1.17 cm x 0.75 cm.

Dr. Chaudhry

INVOICE

Liver

The liver is large in size with smooth peripheral margins. The parenchyma is hyperechoic and homogenous in echotexture. The visible portions of the vasculature and biliary tract appear normal. No focal nodules or cystic lesions are observed.

33415

The gallbladder lumen is moderately distended. The wall of the gall bladder is not thickened and has a smooth mucosal surface. Luminal contents are primarily anechoic. The cystic and common bile ducts are normal/not visible.

Gastrointestinal

The stomach contains minimal luminal contents. It measures at a normal thickness of <0.7cm with some variability due to the presence of rugal folds. The distinction of the gastric wall layers is adequate and there is no impression of reduced peristaltic activity. No masses or focal lesions were observed.

The visualized areas of duodenum, jejunum and ileum have a relatively uniform diameter with minimal fluid distension. Wall thickness is normal. Bowel loops follow a curvilinear path with distinct wall layering maintaining the typical 1:3 muscularis:mucosa layer ratio. Jejunum wall measured 0.36 cm. Visualized peristalsis appears appropriate. There were no focal lesions consistent with obstruction or a mass effect observed.

The ileocecal junction was visualized and exhibited normal intact wall layering and is subjectively of normal thickness. Sections of colon are visualized with formed fecal material and gas shadowing distally. There is no observed focal or generalized colon wall thickening or loss of layering.

Pancreas

The pancreas is normal and isoechoic to surrounding mesentery. There is no evidence of nodules or cystic lesions. There is no evidence of regional mesenteric inflammation or fluid.

Free Abdomen

Evaluation of the peritoneal cavity did not reveal any evidence of effusion, or subjective lymphadenomegaly. The Medial iliac nodes appear normal and there was no evidence of a caudal aortic thrombus at the bifurcation. The omentum is of normal uniform echogenicity.

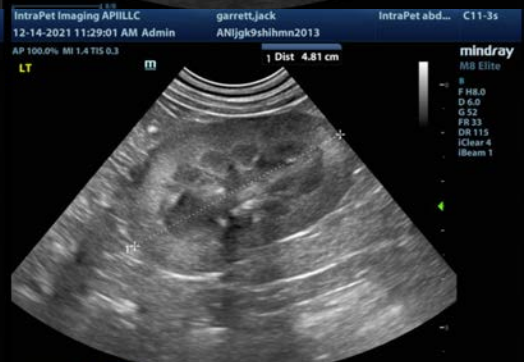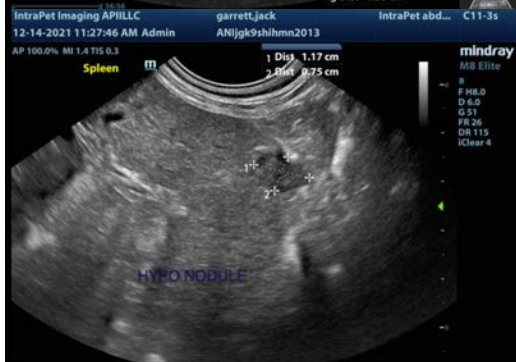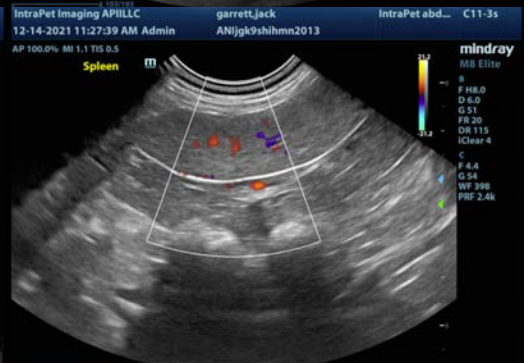
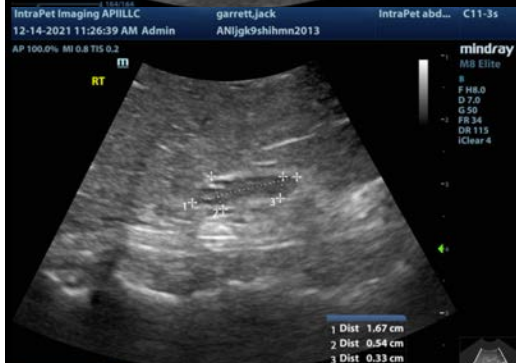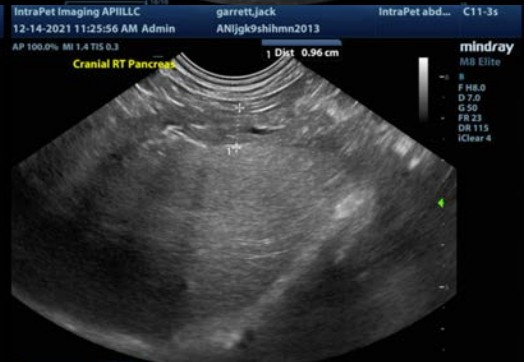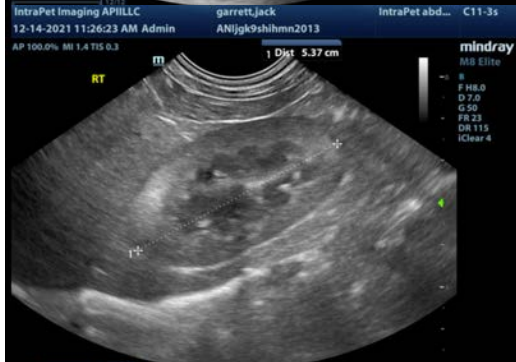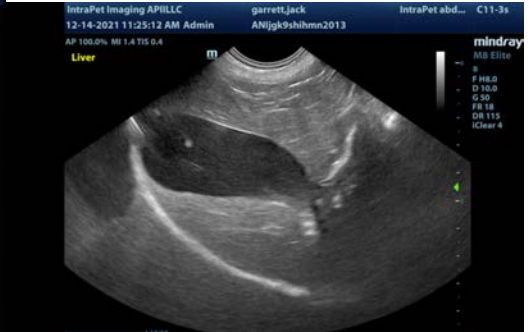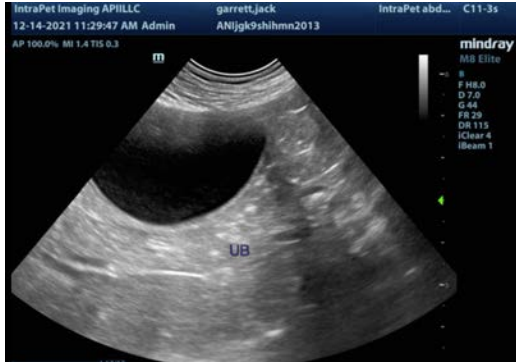ULTRASONOGRAPHIC FINDINGS

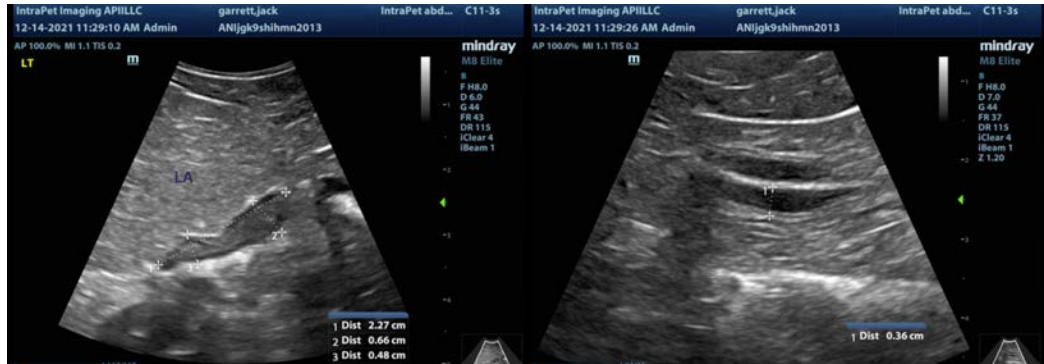- Large, hyperechoic liver – The diffuse hepatic changes are non-specific and can be seen with vacuolar hepatopathy, reactive change, nodular hyperplasia or, less likely, inflammatory/immune-mediated disease, infiltrative neoplasia, or other hepatopathy.
- Mildly mottled spleen with hypoechoic nodule visualized – There is a non-cavitated, hypoechoic splenic nodule visualized. Differentials include lymphoid hyperplasia, extramedullary hematopoiesis, infiltrative neoplasia, inflammation, other. Cytology or histopathology would be necessary to get a definitive diagnosis.

INTERPRETATION OF THE FINDINGS & FURTHER RECOMMENDATIONS

The changes observed in the liver could be consistent with the Phenobarbital therapy reported in the history. The splenic changes are non-specific. The hypoechoic nodule could be consistent with either a benign or a cancerous process. Consider a fine needle aspirate to further evaluate this area. Recommend 3-view thoracic radiographs and continued monitoring of the spleen.

An obvious cause for the reported anemia is not noted. There is no free fluid, etc. Recommend a pathologist review of a blood smear and further evaluation as indicated.





The information and recommendations provided are based on the images presented by the referring veterinarian. No evaluation can be communicated regarding pathology that was not visible in the image/video clips provided.

Thank you for this referral. If the clinical or image interpretation does not parallel your findings or if I can be of any further assistance please contact me.

Kathleen Sennello DVM,MS, Diplomate ACVIM (Small animal Internal Medicine)
kathleen.sennello@sonopath.com