

**DATE PRESENTING CLINICAL SIGNS**

12/14/21

History: P presented with bloody urine 1 week ago and UA consistent with UTI, started on Baytril. Today presented with poor appetite, abd pain. No V/D.

PATIENT

Badger Sharpeta

Current Medications: Baytril 136mg 1.5 SID, Gabapentin 300mg BID.

Lab Results: CBC- wnl, Chem- K 3.2, rest nsf, 4DX- slight pos for ehrlichia, but has been positive in the past. Date of Previous IntraPet Ultrasound: No previous IntraPet scans.

SPECIES

Canine

Sedation: Gabapentin. Butorphanol 10mg/ml -0.7cc IV

Stat Report: Not requested.

BREED

Labrador Retriever

ULTRASONOGRAPHIC EXAMINATION OF THE ABDOMEN**SEX**

Neutered Male

Urinary System

The urinary bladder is moderately distended with anechoic urine. The Bladder wall, trigone, ureteral papillae and visible urethra (to a depth of 2cm) appear normal with no evidence of wall thickening, mucosal irregularities, masses or cystic calculi.

AGE

3/8/13

The prostate is normal in size (0.64 cm) and shape for this neutered male dog. The parenchyma is homogenous and the external margins are smooth. The prostatic urethra appears normal with no evidence of irregularity, invasion, mass effect or calculi.

WEIGHT

75.5 Pounds

The left kidney has a normal shape and size (7.17 cm). Overall echogenicity is normal with adequate corticomedullary distinction and a typical 1:3 cortex:medulla ratio. There is no evidence of perinephric inflammation or effusion. There is no evidence of pyelectasia, nephroliths, infarcts or hydroureter. Renal vasculature is normal.

INTERPRETED BY

Kathleen Sennello DVM,
MS, Diplomate ACVIM
(Small Animal Internal
Medicine)

The right kidney is relatively normal in size, measuring 8.5 cm in length. The majority of its echotexture and echogenicity appear normal, but there is a large heterogeneous mass effect that appears to be arising from the kidney, and surrounded by free fluid in the retroperitoneal space. This mass effect with the fluid measures 8.27 cm x 6.39 cm. The mass itself is 5.47 cm x 4.05 cm. In the more normal appearing kidney, there is no evidence of pyelectasia, nephroliths, infarcts or hydroureter.

IMAGING PERFORMED BY

Rachel Brilhart RDMS

Adrenal Glands

The left adrenal gland is normal in size measuring 0.52 cm at the caudal pole. It is observed in its normal position cranial to the left renal artery. It is normal in appearance (uniformly hypoechoic) and shape with no evidence of a mass effect.

HOSPITAL NAME

Greenbrier Vet Clinic

Visualization of the right adrenal gland is obscured by the mass adjacent to the right kidney. It is possible that the right adrenal gland is involved with this mass effect.

REFERRING VET

Dr. Dellinger

Spleen

The spleen is subjectively normal in size, echotexture is homogenous, and the splenic capsule is smooth with no irregularities. The blood flow through the hilus and splenic parenchyma appears normal. No focal parenchymal abnormalities are visualized.

INVOICE

33424

Liver

The liver is subjectively normal in size, and echogenicity with smooth peripheral margins. The parenchyma is heterogenous in echotexture with subtle, indistinct focal mottling. The visible portions of the vasculature and biliary tract appear normal. No focal nodules or cystic lesions are observed.

The gall bladder lumen is moderately distended. The wall of the gall bladder is not thickened and has a smooth mucosal surface. There is a moderate amount of non-organized echogenic debris. The cystic and common bile ducts are normal/not visible.

Gastrointestinal

The stomach contains minimal luminal contents. It measures at a normal thickness of <0.7cm with some variability due to the presence of rugal folds. The distinction of the gastric wall layers is adequate and there is no impression of reduced peristaltic activity. No masses or focal lesions were observed.

The visualized areas of duodenum, jejunum and ileum have a relatively uniform diameter with minimal fluid distension. Wall thickness is normal. Bowel loops follow a curvilinear path with distinct wall layering maintaining the typical 1:3 muscularis:mucosa layer ratio. The duodenum measured as normal (between 0.3-0.5cm in wall thickness) and the jejunum measured as normal (between 0.2-0.47cm.) Visualized peristalsis appears appropriate. There were no focal lesions consistent with obstruction or a mass effect observed.

The ileocecal junction was visualized and exhibited normal intact wall layering and is subjectively of normal thickness. Sections of colon are visualized with formed fecal material and gas shadowing distally. There is no observed focal or generalized colon wall thickening or loss of layering.

Pancreas

The pancreas is normal and isoechoic to surrounding mesentery. There is no evidence of nodules or cystic lesions. There is no evidence of regional mesenteric inflammation or fluid.

Free Abdomen

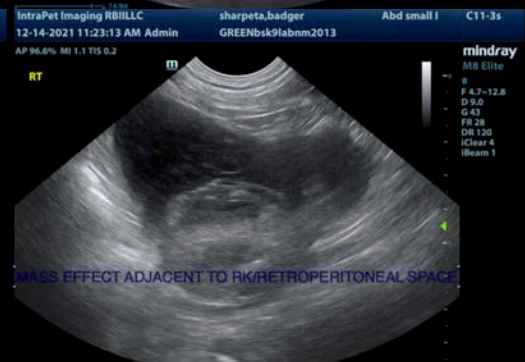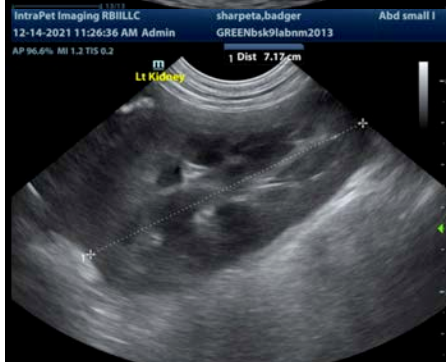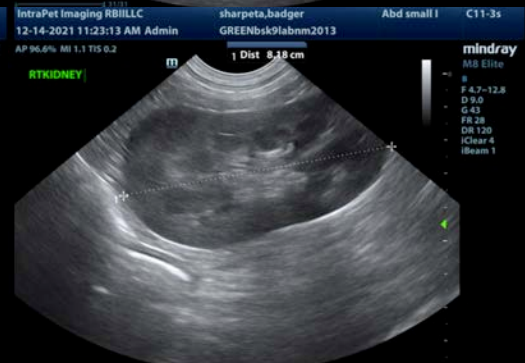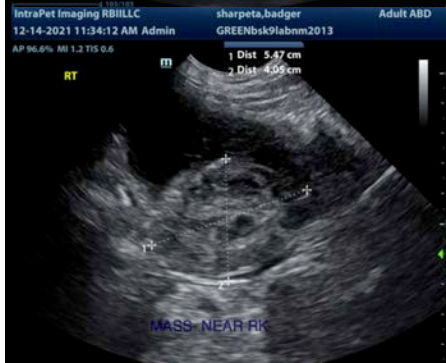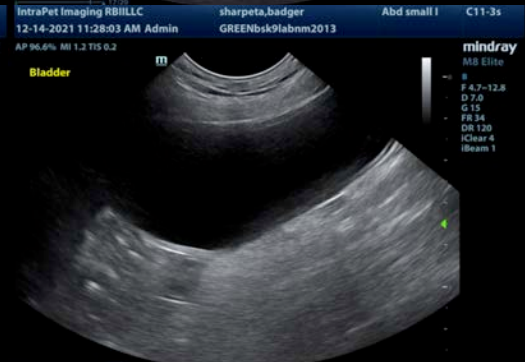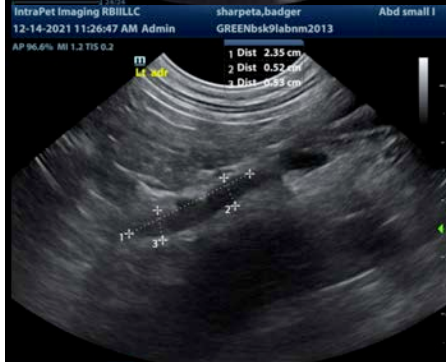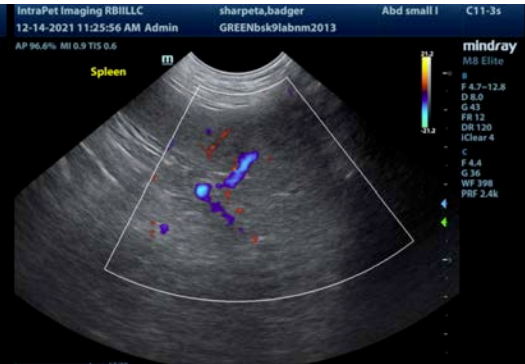
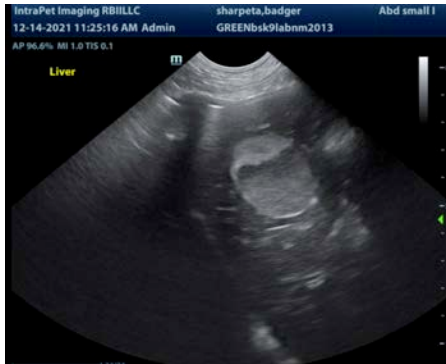Evaluation of the peritoneal cavity did not reveal any evidence of effusion, or subjective lymphadenomegaly. The Medial iliac nodes appear normal and there was no evidence of a caudal aortic thrombus at the bifurcation. The omentum is of increased echogenicity around the right kidney.

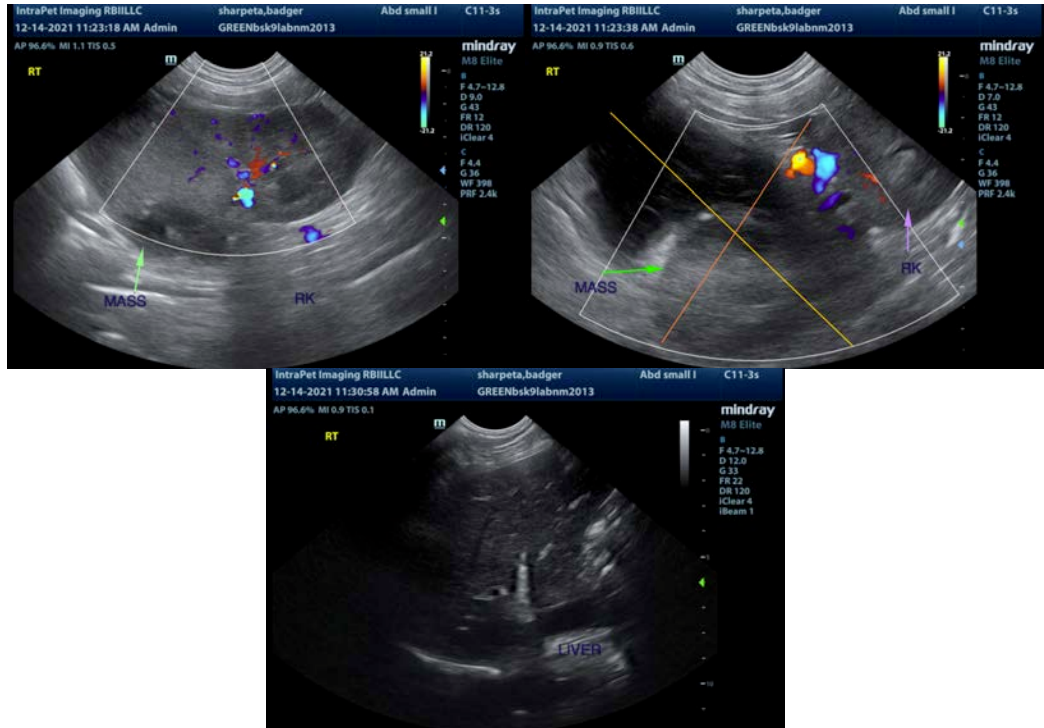
ULTRASONOGRAPHIC FINDINGS

- Suspect right renal mass with fluid in the retroperitoneal space – suggestive of a renal mass and hemorrhage. Underlying neoplasia is strong concern.
- Heterogeneous liver – The diffuse hepatic changes are non-specific and could be consistent with vacuolar hepatopathy, nodular hyperplasia, inflammatory/immune-mediated disease, fibrosis, extramedullary hematopoiesis, toxic hepatopathy (e.g., copper), infiltrative neoplasia (less likely) or other hepatopathy.
- Moderate gallbladder sludge – The significance of the aggregated gallbladder sludge is unclear. This could represent an early mucocele, cholestasis, or may be secondary to fasting.

INTERPRETATION OF THE FINDINGS & FURTHER RECOMMENDATIONS

There is a large mass effect adjacent to/originating from the right kidney. This mass effect is heterogeneous and surrounded by fluid. There is concern that this represents hemorrhage, and based on the blood reported in the urine, this most likely represents a renal mass, although the right adrenal gland cannot be excluded as a possible source. Strongly recommend CT scan of the abdomen to better evaluate this area for surgery and to better evaluate for possible metastasis. Recommend 3-view thoracic radiographs and blood pressure evaluation.





The information and recommendations provided are based on the images presented by the referring veterinarian. No evaluation can be communicated regarding pathology that was not visible in the image/video clips provided.

Thank you for this referral. If the clinical or image interpretation does not parallel your findings or if I can be of any further assistance please contact me.

Kathleen Sennello DVM,MS, Diplomate ACVIM (Small animal Internal Medicine)
kathleen.sennello@sonopath.com