PATIENT

Jesse Knight

SPECIES

Canine

BREED

Dachshund Mix

SEX

Intact Male

AGE

5/5/23

WEIGHT

6.6 kg

INTERPRETED BY

Kathleen A. Sennello DVM, MS, DACVIM (SAIM)

IMAGING PERFORMED BY

Loetitia Saint-Jacques, LVT

HOSPITAL NAME

MountainView AH

REFERRING VET

Dr. Pablo Mendoza

INVOICE

36862

DATE

12/12/25

PRESENTING CLINICAL SIGNS

Patient has a history of bladder stones. Brief ultrasound no obvious stones have been seen recently. Primary issue is an elevation in his liver value. Hepato support 1c SID Sedated with dexdomitor.

Abnormal PE/Chem/CBC/UA Results: Primary issue is an elevation in his liver value. 4.5.25 is was 175 compared to last check was 430 on 11.11.25. He has been on VRS Hepato Support. Asymptomatic for liver disease. Bile acids test was normal. LABS attached.

ULTRASONOGRAPHIC EXAMINATION OF THE ABDOMEN

Urinary System

The urinary bladder is moderately distended with anechoic urine. The bladder wall, trigone, ureteral papillae and visible urethra (to a depth of 2.0 cm) appear normal with no evidence of wall thickening, mucosal irregularities, masses or cystic calculi.

The prostate is large, hyperechoic, and mottled, measuring 2.49 cm in height in the sagittal view.

The left kidney has a normal shape and size (4.7 cm). Overall echogenicity is normal with adequate corticomedullary distinction and a typical 1:3 cortex:medulla ratio. There is no evidence of perinephric inflammation or effusion. There is no evidence of pyelectasia, nephroliths, infarcts or hydroureter. Renal vasculature is normal.

The right kidney has a normal shape and size (4.54 cm). Overall echogenicity is normal with adequate corticomedullary distinction and a typical 1:3 cortex:medulla ratio. There is no evidence of perinephric inflammation or effusion. There is no evidence of pyelectasia, nephroliths, infarcts or hydroureter. Renal vasculature is normal.

Adrenal Glands

The left adrenal gland is normal in size measuring 0.37 cm at the cranial pole and 0.58 cm at the caudal pole. It is observed in its normal position cranial to the left renal artery. It is normal in appearance (uniformly hypoechoic) and shape with no evidence of a mass effect.

The right adrenal gland is normal in size measuring 0.5 cm at the cranial pole and 0.51 cm at the caudal pole. It is observed in its normal position between the cranial aspect of the right kidney and the caudal vena cava. It is normal in appearance (uniformly hypoechoic) and shape with no evidence of a mass effect.

Spleen

The spleen is subjectively normal in size (1.35 cm), echotexture is homogenous, and the splenic capsule is smooth with no irregularities. The blood flow through the hilus and splenic parenchyma appears normal. No focal parenchymal abnormalities are visualized.

Liver

The liver is subjectively normal in size, and echogenicity with smooth peripheral margins. The parenchyma is homogenous echotexture. The visible portions of the vasculature and biliary tract appear normal. No focal nodules or cystic lesions are observed. The gall bladder lumen is moderately

PATIENT
Jesse Knight

SPECIES
Canine

BREED
Dachshund Mix

SEX
Intact Male

AGE
5/5/23

WEIGHT
6.6 kg

INTERPRETED BY
Kathleen A. Sennello DVM, MS, DACVIM (SAIM)

IMAGING PERFORMED BY
Loetitia Saint-Jacques, LVT

HOSPITAL NAME
MountainView AH

REFERRING VET
Dr. Pablo Mendoza

INVOICE
36862

DATE
12/12/25

distended. The wall of the gall bladder is not thickened and has a smooth mucosal surface. Luminal contents are primarily anechoic. The cystic and common bile ducts are normal/not visible.

Gastrointestinal

The stomach is moderately dilated with fluid/ingesta. It measures at a normal thickness of <0.7 cm with some variability due to the presence of rugal folds. The distinction of the gastric wall layering is adequate and there is no impression of reduced peristaltic activity. No masses or focal lesions were observed.

The visualized areas of duodenum, jejunum and ileum have a relatively uniform diameter with minimal to mild fluid/chyme distention. Wall thickness is normal. Bowel loops follow a curvilinear path with distinct wall layering maintaining the typical 1:3 muscularis: mucosa layer ratio. The duodenum measured as normal (0.56 cm in wall thickness) and the jejunum measured as normal (0.27 cm) Visualized peristalsis appears appropriate. There were no focal lesions consistent with obstruction or a mass effect observed.

The ileocecal junction was visualized and exhibited normal intact wall layering and is subjectively of normal thickness. Sections of colon are visualized with formed fecal material and gas shadowing distally. There is no observed focal or generalized colon wall thickening or loss of layering.

Pancreas

The pancreas is visible/mildly mottled in the right limb compared to the surrounding isoechoic mesentery. There is no evidence of nodules or cystic lesions. There is no evidence of regional mesenteric inflammation or fluid.

Free Abdomen

Evaluation of the peritoneal cavity did not reveal any evidence of effusion. There is no significant lymphadenopathy. An isoechoic mesenteric lymph node is visualized, measuring 0.31 cm x 2.63 cm. The medial iliac nodes appear normal and there was no evidence of a caudal aortic thrombus at the bifurcation. The omentum is of normal uniform echogenicity.

Both testicles were visualized and appear within normal limits.

ULTRASONOGRAPHIC FINDINGS

- Large hyperechoic prostate- Findings are most consistent with benign prostatic hypertrophy.
- Pancreatic changes most consistent with chronic pancreatic remodeling. Mild chronic pancreatitis is possible.
- Moderate fluid/ingesta visualized within the gastric lumen- Correlate with the feeding history. If the patient was adequately fasted, this could represent delayed gastric emptying.

INTERPRETATION OF THE FINDINGS & FURTHER RECOMMENDATIONS

No focal lesions are visualized associated with the liver or the gallbladder to explain the elevation in ALT reported. Unfortunately, there are many causes for an elevation in ALT, which cannot be

PATIENT

Jesse Knight

SPECIES

Canine

BREED

Dachshund Mix

SEX

Intact Male

AGE

5/5/23

WEIGHT

6.6 kg

INTERPRETED BY

Kathleen A. Sennello DVM, MS, DACVIM (SAIM)

IMAGING PERFORMED BY

Loetitia Saint-Jacques, LVT

HOSPITAL NAME

MountainView AH

REFERRING VET

Dr. Pablo Mendoza

INVOICE

36862

DATE

12/12/25

diagnosed by ultrasound alone. Consider the following for further evaluation:

- Recommend pre- and postprandial bile acids to evaluate liver function (I believe this is already done).
- If clinically appropriate, consider screening for leptospirosis.
- You could consider empirical treatment for acute liver injury with a course of ursodiol, denamarin, and antibiotics.
- If liver function is abnormal and/or the ALT is persistently elevated, biopsies of the liver may eventually be warranted with samples for histopathology, culture, and copper levels.

The pancreas is somewhat prominent, but based on the history, there is no report of underlying gastrointestinal symptoms. If active pancreatitis is suspected, based on a significantly elevated PLI level or symptoms, then empirical treatment could be started, and a recheck ALT after treatment.

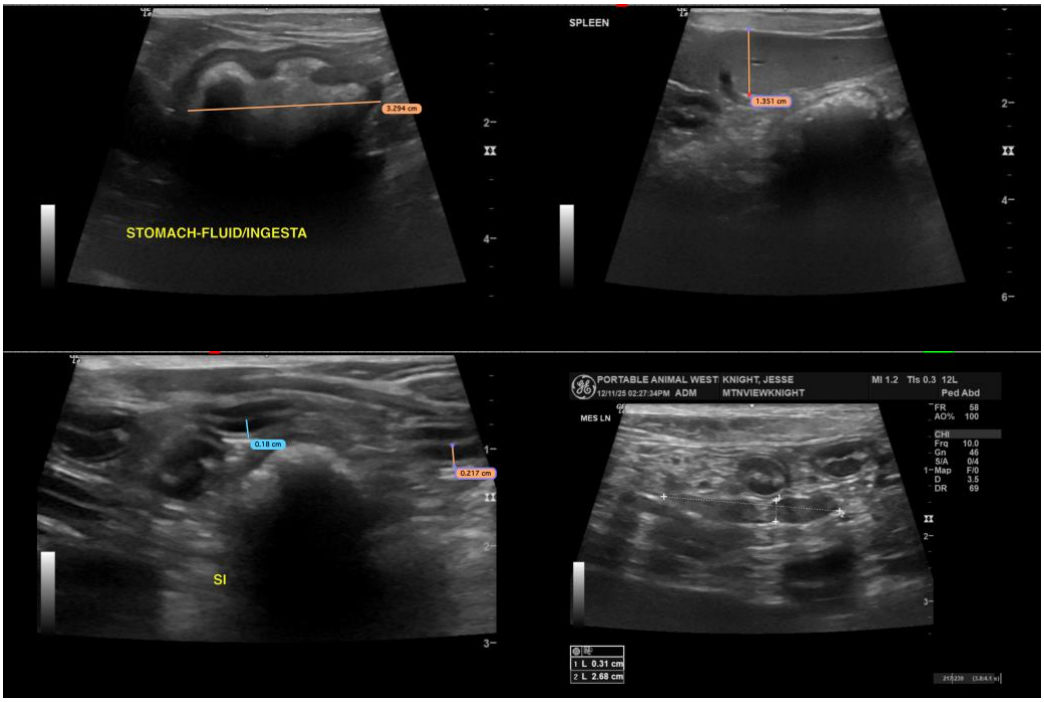

Imaging performed by
pawsonography@gmail.com
530-786-8340

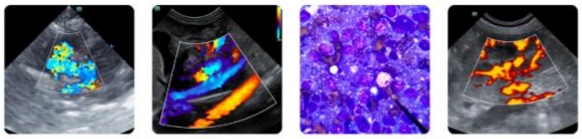

Clinical Sonography & Telecytology
Educational Teleconsultation Services™

SonoPath
FOSTERING THE ART OF VETERINARY MEDICINE™
SonoPath.com info@sonopath.com 1.800.838.4268

PATIENT

Jesse Knight

SPECIES

Canine

BREED

Dachshund Mix

SEX

Intact Male

AGE

5/5/23

WEIGHT

6.6 kg

INTERPRETED BY

Kathleen A. Sennello DVM, MS, DACVIM (SAIM)

IMAGING PERFORMED BY

Loetitia Saint-Jacques, LVT

HOSPITAL NAME

MountainView AH

REFERRING VET

Dr. Pablo Mendoza

INVOICE

36862

DATE

12/12/25

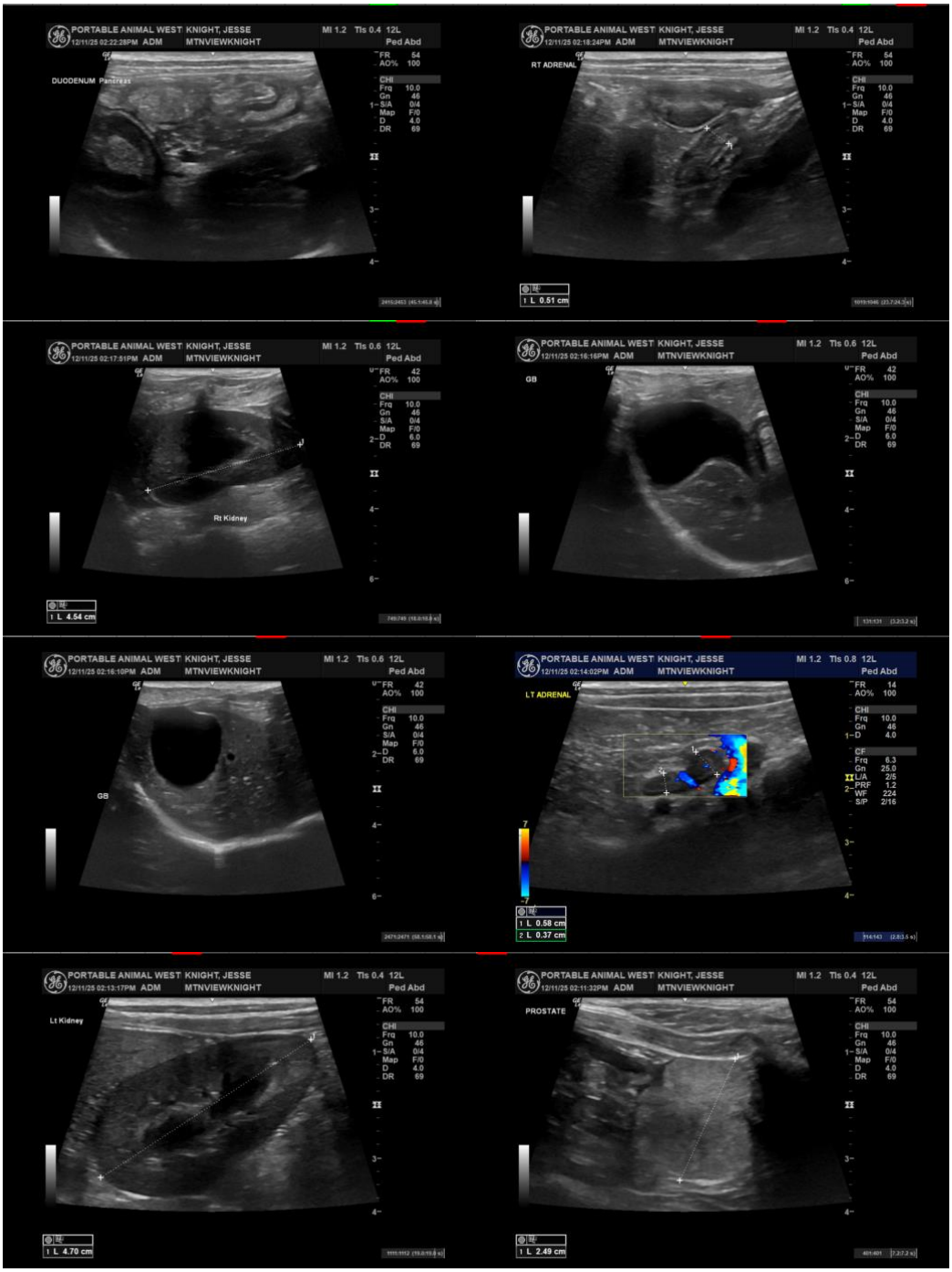

The information and recommendations provided are based on the images presented by the referring veterinarian/sonographer. No evaluation can be communicated regarding pathology that was not visible in the image/video clips provided.

Thank you for this referral. If the clinical or image interpretation does not parallel your findings or if I

PATIENT

Jesse Knight

SPECIES

Canine

BREED

Dachshund Mix

SEX

Intact Male

AGE

5/5/23

WEIGHT

6.6 kg

INTERPRETED BY

Kathleen A. Sennello DVM, MS, DACVIM (SAIM)

IMAGING PERFORMED BY

Loetitia Saint-Jacques, LVT

HOSPITAL NAME

MountainView AH

REFERRING VET

Dr. Pablo Mendoza

INVOICE

36862

DATE

12/12/25

can be of any further assistance, please contact me.

Kathleen Sennello DVM, MS, Diplomate ACVIM (Small animal Internal Medicine)

info@sonopath.com