



## PATIENT

Mila Santos

## SPECIES

Canine

## BREED

French Bulldog

## SEX

Spayed Female

## AGE

9 Months

## WEIGHT

19.6 lbs

## INTERPRETED BY

Kathleen Sennello DVM,  
MS, Diplomate ACVIM  
(Small Animal Internal  
Medicine)

## IMAGING PERFORMED BY

Gabriel Ferrer, DVM

## HOSPITAL NAME

Pulse: Pet Ultrasound

## REFERRING VET

Dr. Laura S. Solis

## INVOICE

72503

## DATE

12/11/25

## PRESENTING CLINICAL SIGNS

Pt presented as a referral for an abdominal ultrasound to evaluate history of urinary problems, straining to urinate, and urinating very dark urine. Pt first presented at rDVM with UTI symptoms before her spay and was treated accordingly. Pt later presented with UTI symptoms some time after her spay and a urine culture was then performed, pt was then treated with recommended medication and dosages. Pt started on Urinary SO diet on 11/23/2025 after she presented with straining to urinate and urinating dark urine.

Abnormal PE/Chem/CBC/UA Results: UA results: Presence of Calcium Oxalate Dehydrate crystals Proteinuria (+1) USG 1.037 pH 5.5 RBC present

## ULTRASONOGRAPHIC EXAMINATION OF THE ABDOMEN

### *Urinary System*

The urinary bladder is moderately distended with mild primarily suspended echogenic debris present. There are occasional small areas of dependent debris, an example measures 0.15 cm near the trigone. The Bladder wall, trigone, ureteral papillae and visible urethra (to a depth of 2cm) appear normal with no evidence of wall thickening, mucosal irregularities, masses or calculi. Echogenic debris of this type can be associated with small crystals, cellular debris and proteinaceous debris.

The left kidney has a normal shape and size (4.41 cm). Overall echogenicity is normal with adequate corticomedullary distinction and a typical 1:3 cortex:medulla ratio. There is no evidence of focal perinephric inflammation or effusion. There is no evidence of pyelectasia, nephroliths, infarcts or hydroureter. Renal vasculature is normal.

The right kidney has a normal shape and size (4.2 cm). Overall echogenicity is normal with adequate corticomedullary distinction and a typical 1:3 cortex:medulla ratio. There is no evidence of focal perinephric inflammation or effusion. There is no evidence of pyelectasia, nephroliths, infarcts or hydroureter. Renal vasculature is normal.

### *Adrenal Glands*

The left adrenal gland is normal in size measuring 0.38 cm at the cranial pole and 0.40 cm at the caudal pole. It is observed in its normal position cranial to the left renal artery. It is normal in appearance (uniformly hypoechoic) and shape with no evidence of a mass effect.

The right adrenal gland is normal in size measuring 0.52 cm at the cranial pole and 0.56 cm at the caudal pole. It is observed in its normal position between the cranial aspect of the right kidney and the caudal vena cava. It is normal in appearance (uniformly hypoechoic) and shape with no evidence of a mass effect.

### *Spleen*

The spleen is subjectively normal in size (1.42 cm), echotexture is homogenous, and the splenic capsule is smooth with no irregularities. The blood flow through the hilus and splenic parenchyma appears normal. No focal parenchymal abnormalities are visualized.



## PATIENT

Mila Santos

## SPECIES

Canine

## BREED

French Bulldog

## SEX

Spayed Female

## AGE

9 Months

## WEIGHT

19.6 lbs

## INTERPRETED BY

Kathleen Sennello DVM,  
MS, Diplomate ACVIM  
(Small Animal Internal  
Medicine)

## IMAGING PERFORMED BY

Gabriel Ferrer, DVM

## HOSPITAL NAME

Pulse: Pet Ultrasound

## REFERRING VET

Dr. Laura S. Solis

## INVOICE

72503

## DATE

12/11/25

## Liver

The liver is subjectively normal in size, and echogenicity with smooth peripheral margins. The parenchyma is homogenous echotexture. The visible portions of the vasculature and biliary tract appear normal. No focal nodules or cystic lesions are observed.

The gall bladder lumen is moderately distended. The wall of the gall bladder is not thickened and has a smooth mucosal surface. Luminal contents are mild and likely incidental at this time. The cystic and common bile ducts are normal/not visible.

## Gastrointestinal

The stomach contains mild/moderate fluid. It measures at a normal thickness of <0.7cm with some variability due to the presence of rugal folds. The distinction of the gastric wall layers is adequate and there is no impression of reduced peristaltic activity. No masses or focal lesions were observed.

The visualized areas of duodenum, jejunum and ileum have a relatively uniform diameter with minimal fluid distension. Wall thickness is normal. Bowel loops follow a curvilinear path with distinct wall layering maintaining the typical 1:3 muscularis:mucosa layer ratio. Duodenum wall measures 0.54 cm. Jejunum wall measures 0.49 cm. Visualized peristalsis appears appropriate. There were no focal lesions consistent with obstruction or a mass effect observed.

Sections of colon are visualized with formed fecal material and gas shadowing distally. There is no observed focal or generalized colon wall thickening or loss of layering.

## Pancreas

The pancreas is normal and isoechoic to surrounding mesentery. There is no evidence of nodules or cystic lesions. There is no evidence of regional mesenteric inflammation or fluid.

## Free Abdomen

Evaluation of the peritoneal cavity did not reveal any evidence of effusion, or subjective lymphadenomegaly. The Medial iliac nodes appear normal and there was no evidence of a caudal aortic thrombus at the bifurcation. The omentum is of normal uniform echogenicity.

## ULTRASONOGRAPHIC FINDINGS

- Mild suspended and dependent echogenic debris in the urinary bladder – The echogenic debris in the bladder lumen could be consistent with cells, crystals, and/or mucus.

## INTERPRETATION OF THE FINDINGS & FURTHER RECOMMENDATIONS

No focal lesions are visualized associated with the urinary bladder to explain the lower urinary tract symptoms described. It is unclear if these are recurrent urinary tract infections. If so, consider looking for metabolic and/or anatomic causes for recurrent urinary tract infections. If there is no evidence of immunosuppression, chronic renal disease or similar, then consider cystoscopy to evaluate the lower urogenital tract, the ureters, etc. A sterile digital vaginal exam and/or vaginoscopy could also be considered, looking for any evidence of a distal foreign body, anatomic abnormality, etc.

There is a small amount of debris in the urinary bladder. The significance of this is uncertain. No large stones or mass lesions are observed.



## PATIENT

Mila Santos

## SPECIES

Canine

## BREED

French Bulldog

## SEX

Spayed Female

## AGE

9 Months

## WEIGHT

19.6 lbs

## INTERPRETED BY

Kathleen Sennello DVM,  
MS, Diplomate ACVIM  
(Small Animal Internal  
Medicine)

## IMAGING PERFORMED BY

Gabriel Ferrer, DVM

## HOSPITAL NAME

Pulse: Pet Ultrasound

## REFERRING VET

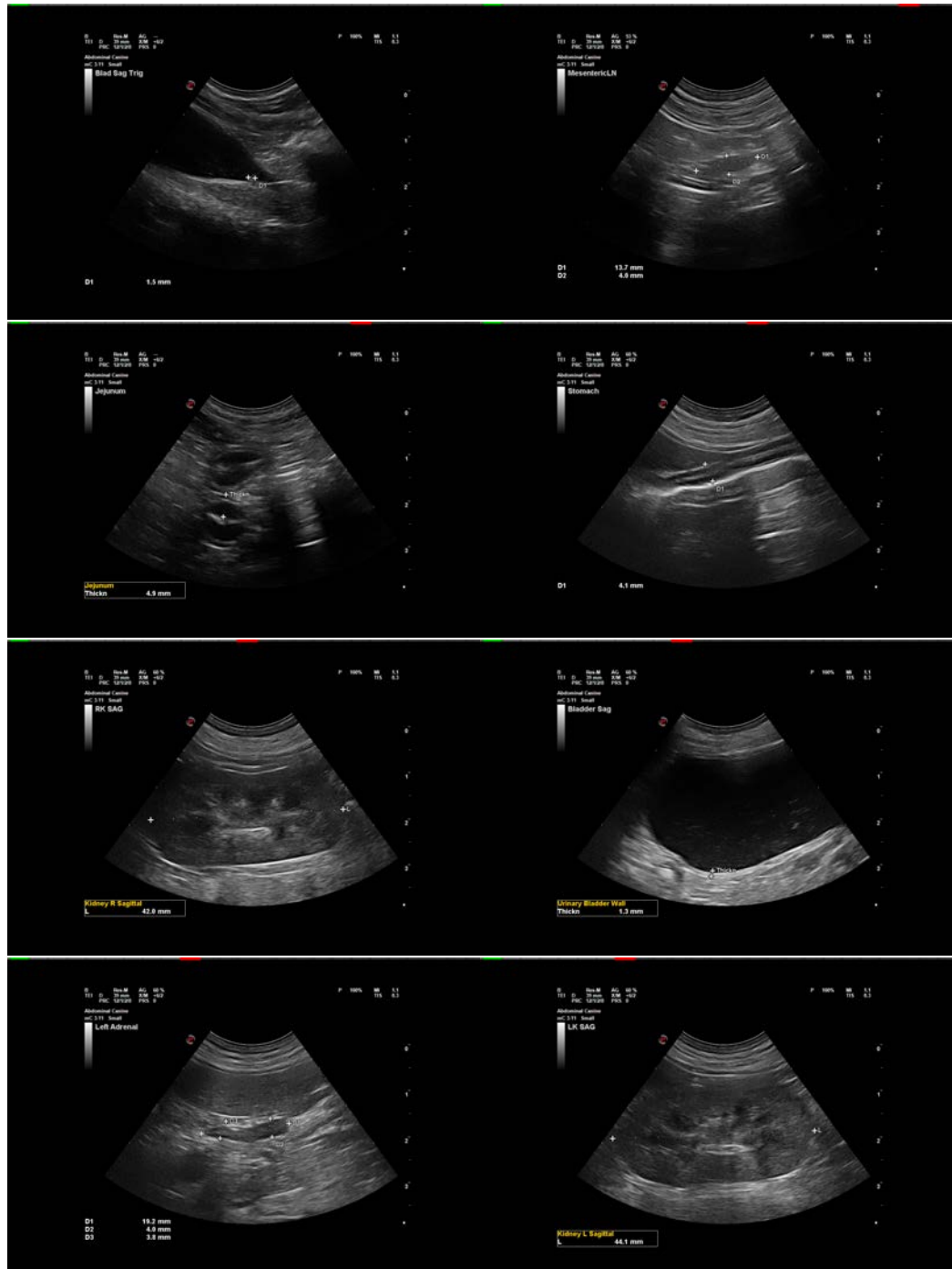
Dr. Laura S. Solis

## INVOICE

72503

## DATE

12/11/25





## PATIENT

Mila Santos

## SPECIES

Canine

## BREED

French Bulldog

## SEX

Spayed Female

## AGE

9 Months

## WEIGHT

19.6 lbs

## INTERPRETED BY

Kathleen Sennello DVM,  
MS, Diplomate ACVIM  
(Small Animal Internal  
Medicine)

## IMAGING PERFORMED BY

Gabriel Ferrer, DVM

## HOSPITAL NAME

Pulse: Pet Ultrasound

## REFERRING VET

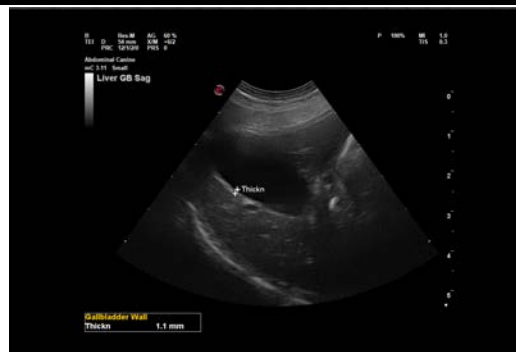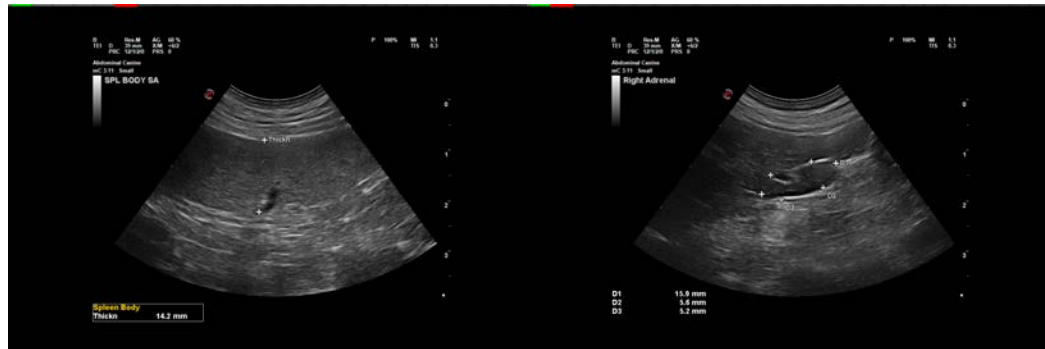
Dr. Laura S. Solis

## INVOICE

72503

## DATE

12/11/25



The information and recommendations provided are based on the images presented by the referring veterinarian/sonographer. No evaluation can be communicated regarding pathology that was not visible in the image/video clips provided.

Thank you for this referral. If the clinical or image interpretation does not parallel your findings or if I can be of any further assistance please contact me.

Kathleen Sennello DVM,MS, Diplomate ACVIM (Small animal Internal Medicine)

info@sonopath.com