



PATIENT

Bisou Anavir

SPECIES

Canine

BREED

Yorkshire Terrier x

SEX

Neutered Male

AGE

5 Years

WEIGHT

33.7 lbs

INTERPRETED BY

Kathleen Sennello DVM,
MS, Diplomate ACVIM
(Small Animal Internal
Medicine)

IMAGING PERFORMED BY

Sara Hansen

HOSPITAL NAME

West Eugene Animal
Hospital

REFERRING VET

Dr. Larsen

INVOICE

72467

DATE

12/10/25

PRESENTING CLINICAL SIGNS

Clinical Exam Findings: The liver values have continued to increase with a marked elevation in ALP and a moderate elevation in ALT. ABNORMAL Labwork Values ALT 325 ALK Phos 1209 Current Medications Fluoxetine Alprazolam Denamarin

ULTRASONOGRAPHIC EXAMINATION OF THE ABDOMEN

Urinary System

The urinary bladder is moderately distended with anechoic urine. The Bladder wall, trigone, ureteral papillae and visible urethra (to a depth of 2cm) appear normal with no evidence of wall thickening, mucosal irregularities, masses or cystic calculi.

The visualized areas of prostate and surrounding tissue appear normal. Unfortunately, the prostate is not fully visualized likely due to its intrapelvic location. Correlate with rectal exam findings.

The left kidney has a normal shape and size (5.26 cm). Overall echogenicity is normal with adequate corticomedullary distinction and a typical 1:3 cortex:medulla ratio. There is no evidence of focal perinephric inflammation or effusion. There is no evidence of pyelectasia, nephroliths, infarcts or hydroureter. Renal vasculature is normal.

The right kidney has a normal shape and size (5.32 cm). Overall echogenicity is normal with adequate corticomedullary distinction and a typical 1:3 cortex:medulla ratio. There is no evidence of focal perinephric inflammation or effusion. There is no evidence of pyelectasia, nephroliths, infarcts or hydroureter. Renal vasculature is normal.

Adrenal Glands

The left adrenal gland is normal in size measuring 0.53 cm at the cranial pole and 0.60 cm at the caudal pole. It is observed in its normal position cranial to the left renal artery. It is normal in appearance (uniformly hypoechoic) and shape with no evidence of a mass effect.

The right adrenal gland is normal in size measuring 1.19 cm at the cranial pole and 0.56 cm at the caudal pole. It is observed in its normal position between the cranial aspect of the right kidney and the caudal vena cava. It is normal in appearance (uniformly hypoechoic) and shape with no evidence of a mass effect.

Spleen

The spleen is subjectively normal in size, echotexture is homogenous, and the splenic capsule is smooth with no irregularities. The blood flow through the hilus and splenic parenchyma appears normal. There is a small hypoechoic nodule visualized in the region of the tail of the spleen measuring 0.80 cm.

Liver

The liver is large in size, and normal in echogenicity with smooth peripheral margins. The parenchyma is heterogenous in echotexture with subtle, indistinct focal mottling. The visible portions of the vasculature and biliary tract appear normal. No focal nodules or cystic lesions are observed.

The gall bladder lumen is moderately distended. The wall of the gall bladder is not thickened and has a smooth mucosal surface. Luminal contents are mild and likely incidental at this time. The cystic and common bile ducts are normal/not visible.



PATIENT

Bisou Anavir

SPECIES

Canine

BREED

Yorkshire Terrier x

SEX

Neutered Male

AGE

5 Years

WEIGHT

33.7 lbs

INTERPRETED BY

Kathleen Sennello DVM,
 MS, Diplomate ACVIM
 (Small Animal Internal
 Medicine)

IMAGING PERFORMED BY

Sara Hansen

HOSPITAL NAME

West Eugene Animal
 Hospital

REFERRING VET

Dr. Larsen

INVOICE

72467

DATE

12/10/25

Gastrointestinal

The stomach contains mild fluid and gas. It measures at a normal thickness of <0.7cm with some variability due to the presence of rugal folds. The distinction of the gastric wall layers is adequate and there is no impression of reduced peristaltic activity. No masses or focal lesions were observed.

The visualized areas of duodenum, jejunum and ileum have a relatively uniform diameter with minimal fluid distension. Wall thickness is normal. Bowel loops follow a curvilinear path with distinct wall layering maintaining the typical 1:3 muscularis:mucosa layer ratio. Duodenum wall measures 0.57 cm. Jejunum wall measures 0.31 cm. Visualized peristalsis appears appropriate. There were no focal lesions consistent with obstruction or a mass effect observed.

Sections of colon are visualized with formed fecal material and gas shadowing distally. There is no observed focal or generalized colon wall thickening or loss of layering.

Pancreas

The pancreas is normal and isoechoic to surrounding mesentery. There is no evidence of nodules or cystic lesions. There is no evidence of regional mesenteric inflammation or fluid.

Free Abdomen

Evaluation of the peritoneal cavity did not reveal any evidence of effusion, or subjective lymphadenomegaly. The Medial iliac nodes appear normal and there was no evidence of a caudal aortic thrombus at the bifurcation. The omentum is of normal uniform echogenicity.

ULTRASONOGRAPHIC FINDINGS

- Hypoechoic nodule visualized in the spleen – There is a non-cavitated, hypoechoic splenic nodule visualized. Differentials include lymphoid hyperplasia, extramedullary hematopoiesis, infiltrative neoplasia, inflammation, other. Cytology or histopathology would be necessary to get a definitive diagnosis.
- Large, heterogeneous liver – The diffuse hepatic changes are non-specific and could be consistent with vacuolar hepatopathy, nodular hyperplasia, inflammatory/immune-mediated disease, fibrosis, extramedullary hematopoiesis, toxic hepatopathy (e.g., copper), infiltrative neoplasia (less likely) or other hepatopathy.

INTERPRETATION OF THE FINDINGS & FURTHER RECOMMENDATIONS

No focal lesions are visualized associated with the liver, and the gallbladder appears normal. Findings are most consistent with a primary hepatopathy. Given the history provided, a vacuolar hepatopathy would be most likely but other hepatopathies are possible. Consider a liver function test +/- a fine needle aspirate of the liver for further evaluation. If liver function is abnormal and/or liver enzymes (particularly ALT) continue to rise, eventually a biopsy of the liver may be warranted (with samples for histopathology, culture and copper levels).

No adrenal enlargement is noted currently, but this does not definitively rule out Cushing's. If symptoms consistent with Cushing's disease are present and it is strongly suspected, you could consider adrenal function testing.



PATIENT

Bisou Anavir

SPECIES

Canine

BREED

Yorkshire Terrier x

SEX

Neutered Male

AGE

5 Years

WEIGHT

33.7 lbs

INTERPRETED BY

Kathleen Sennello DVM,
 MS, Diplomate ACVIM
 (Small Animal Internal
 Medicine)

**IMAGING
 PERFORMED BY**

Sara Hansen

HOSPITAL NAME

West Eugene Animal
 Hospital

REFERRING VET

Dr. Larsen

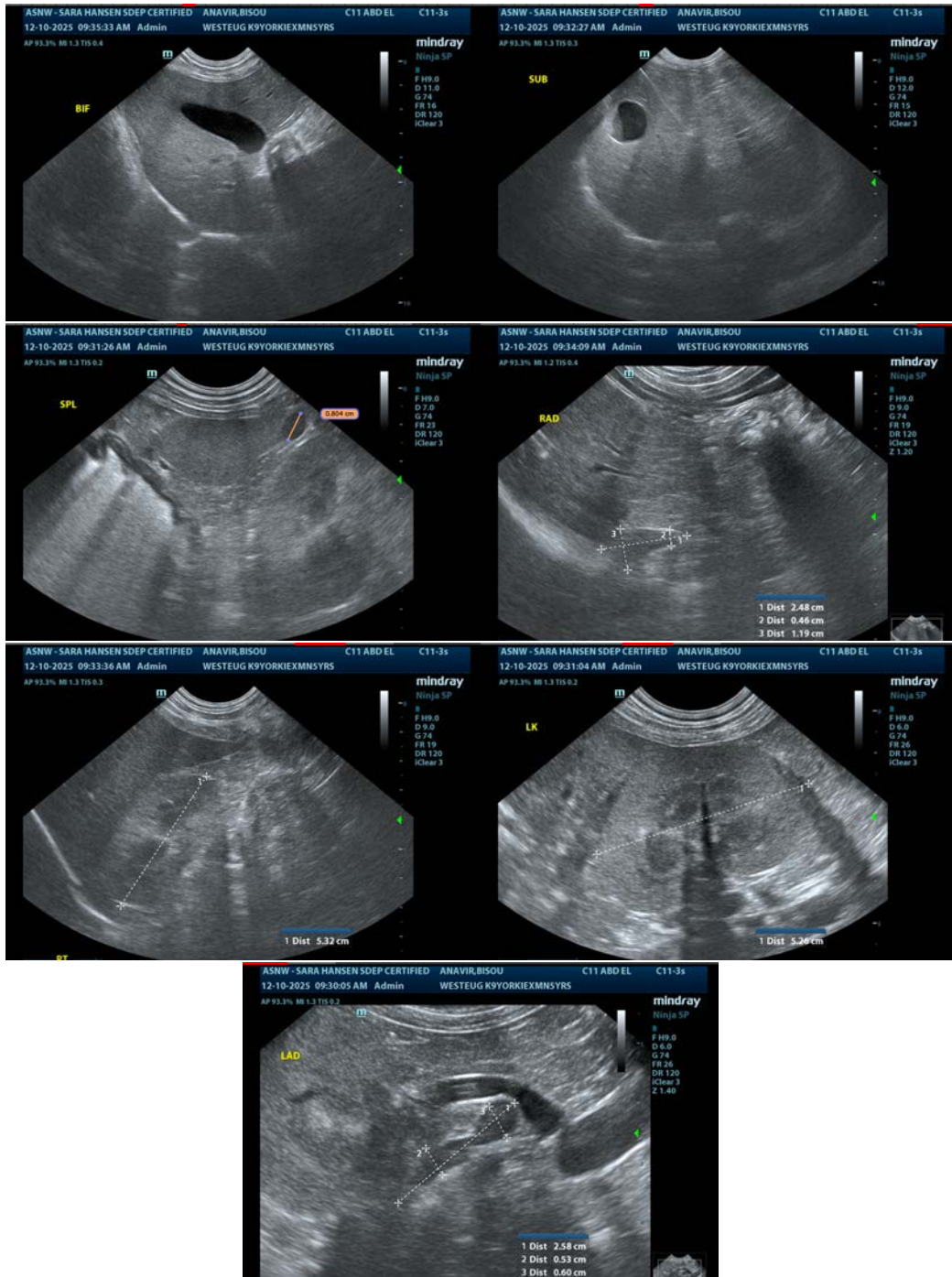
INVOICE

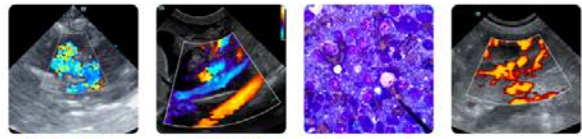
72467

DATE

12/10/25

There is a small hypochoic nodule visualized associated with the spleen. Options moving forward would include fine needle aspirate or continued monitoring with ultrasound (recheck in 2-3 months).





PATIENT

Bisou Anavir

SPECIES

Canine

BREED

Yorkshire Terrier x

SEX

Neutered Male

AGE

5 Years

WEIGHT

33.7 lbs

INTERPRETED BY

Kathleen Sennello DVM,
MS, Diplomate ACVIM
(Small Animal Internal
Medicine)

**IMAGING
PERFORMED BY**

Sara Hansen

HOSPITAL NAME

West Eugene Animal
Hospital

REFERRING VET

Dr. Larsen

INVOICE

72467

DATE

12/10/25

The information and recommendations provided are based on the images presented by the referring veterinarian/sonographer. No evaluation can be communicated regarding pathology that was not visible in the image/video clips provided.

Thank you for this referral. If the clinical or image interpretation does not parallel your findings or if I can be of any further assistance please contact me.

Kathleen Sennello DVM,MS, Diplomate ACVIM (Small animal Internal Medicine)

info@sonopath.com