



## PATIENT

Bella Hart

## SPECIES

Canine

## BREED

Bulldgo Mix

## SEX

Spayed Female

## AGE

14 years

## WEIGHT

43 lbs

## INTERPRETED BY

Kathleen Sennello DVM,  
MS, Diplomate ACVIM  
(Small Animal Internal  
Medicine)

## IMAGING PERFORMED BY

Loetitia Saint-Jacques,  
LVT

## HOSPITAL NAME

Sierra Animal Wellness  
Center

## REFERRING VET

Dr. Peggy Roberts

## INVOICE

10928

## DATE

12/10/2025

## PRESENTING CLINICAL SIGNS

14-year-old Bulldog mix BW 43# FS Vomiting, inappetence, weight loss. Blood work normal except BUN 85 crea 1.5. No diarrhea. Concern for a bleed. Fasted 12 hours. No sedation.

## ULTRASONOGRAPHIC EXAMINATION OF THE ABDOMEN

### Urinary System

The urinary bladder is moderately distended with anechoic urine. The Bladder wall appears slightly prominent and irregular measuring at 0.26 cm. The regino of the trigone, ureteral papillae and visible urethra appear free of any mass, lesions, or calculi.

The left kidney has a normal shape and size (5.86 cm). Overall echogenicity is normal with adequate corticomedullary distinction and a typical 1:3 cortex:medulla ratio. There is no evidence of focal perinephric inflammation or effusion. There is no evidence of pyelectasia, nephroliths, infarcts or hydroureter. Renal vasculature is normal.

The right kidney has a normal shape and size (6.25 cm). Overall echogenicity is normal with adequate corticomedullary distinction and a typical 1:3 cortex:medulla ratio. There is no evidence of focal perinephric inflammation or effusion. There is no evidence of pyelectasia, nephroliths, infarcts or hydroureter. Renal vasculature is normal.

### Adrenal Glands

The left adrenal gland is borderline large in size measuring 0.71 cm at the cranial pole and 0.75 cm at the caudal pole. It is observed in its normal position cranial to the left renal artery. It is normal in appearance (uniformly hypoechoic) and shape with no evidence of a mass effect.

The right adrenal gland is borderline large in size measuring 1.11 cm at the cranial pole and 0.93 cm at the caudal pole. It is observed in its normal position between the cranial aspect of the right kidney and the caudal vena cava. It is normal in appearance (uniformly hypoechoic) and shape with no evidence of a mass effect.

### Spleen

The spleen is subjectively normal in size and the echotexture is homogenous. The splenic capsule is smooth with no visible irregularities. The blood flow through the hilus and splenic parenchyma appears normal. There are numerous hypoechoic nodules in the parenchyma. A poorly defined larger nodule visualized measures 1.36 cm x 2.1 cm. A second nodule measures at 1.38 cm x 2.42 cm. A small third nodule at the periphery of the spleen measures 0.5 cm.

### Liver

The liver is subjectively normal in size, and echogenicity with smooth peripheral margins. The parenchyma is homogenous echotexture. The visible portions of the vasculature and biliary tract appear normal. No focal nodules or cystic lesions are observed.

The gall bladder lumen is moderately distended. The wall of the gall bladder is not thickened and has a smooth mucosal surface. Luminal contents are mild and likely incidental at this time. The cystic and common bile ducts are normal/not visible.

### Gastrointestinal



**PATIENT**

Bella Hart

**SPECIES**

Canine

**BREED**

Bulldog Mix

**SEX**

Spayed Female

**AGE**

14 years

**WEIGHT**

43 lbs

**INTERPRETED BY**

Kathleen Sennello DVM,  
MS, Diplomate ACVIM  
(Small Animal Internal  
Medicine)

**IMAGING  
PERFORMED BY**

Loetitia Saint-Jacques,  
LVT

**HOSPITAL NAME**

Sierra Animal Wellness  
Center

**REFERRING VET**

Dr. Peggy Roberts

**INVOICE**

10928

**DATE**

12/10/2025

The stomach is moderately dilated with fluid and irregular shadowing material most consistent with normal ingesta and gas. It measures at a normal thickness of <0.7cm with some variability due to the presence of rugal folds. The distinction of the gastric wall layering is adequate and there is no impression of reduced peristaltic activity. No masses or focal lesions were observed.

The visualized areas of duodenum (0.54 cm), jejunum (0.33 cm) and ileum have a uniform diameter with minimal to mild fluid distension. Wall appears subjectively, mildly increased. Bowel loops follow a typical curvilinear path with distinct wall layering. Visualized peristalsis appears appropriate. The duodenum appears mildly fluid distended and there is occasional segmental thickening of the small intestine with intact wall layering. An example of a thickened loop of bowel measures 0.46 cm.

The ileocecal junction was visualized and exhibited normal intact wall layering and is subjectively of normal thickness. Sections of colon are visualized with formed fecal material and gas shadowing distally. There is no observed focal or generalized colon wall thickening or loss of layering.

**Pancreas**

The pancreas is normal and isoechoic to surrounding mesentery. There is no evidence of nodules or cystic lesions. There is no evidence of regional mesenteric inflammation or fluid.

**Free Abdomen**

Evaluation of the peritoneal cavity did not reveal any evidence of effusion. There is no significant lymphadenopathy. A jejunal lymph node is visualized measuring 0.4 cm. The omentum is of normal uniform echogenicity.

**Other**

The right auricle and pericardium were visualized and were unremarkable. No obvious pathology is visualized. If cardiac function evaluation is desired a full echocardiogram is warranted.

**ULTRASONOGRAPHIC FINDINGS**

- Mildly irregular/thickened urinary bladder wall. The bladder mucosal changes could be consistent with cystitis or artifactual due to lack of adequate luminal distension. Bladder neoplasia cannot be ruled out but is considered unlikely in this patient.
- Multiple hypoechoic nodules in the spleen. There are several, non-cavitated, hypoechoic splenic nodules visualized. Differentials include lymphoid hyperplasia, extramedullary hematopoiesis, infiltrative neoplasia, inflammation, other. Cytology or histopathology would be necessary to get a definitive diagnosis
- Borderline large adrenals. Findings could be consistent with anatomic variation, mild hyperplasia, etc.
- Moderate fluid/ingesta visualized within the gastric lumen. Correlate with the feeding history. If the patient was adequately fasted, this likely represents delayed gastric emptying. No evidence of an outflow tract obstruction is visualized.
- Segmental thickening of the small intestine. The mild small intestinal wall changes may be a normal variant in this patient or could be consistent with an inflammatory process (e.g., inflammatory bowel disease).



**PATIENT**

Bella Hart

**SPECIES**

Canine

**BREED**

Bulldog Mix

**SEX**

Spayed Female

**AGE**

14 years

**WEIGHT**

43 lbs

**INTERPRETED BY**

Kathleen Sennello DVM,  
MS, Diplomate ACVIM  
(Small Animal Internal  
Medicine)

**IMAGING PERFORMED BY**

Loetitia Saint-Jacques,  
LVT

**HOSPITAL NAME**

Sierra Animal Wellness  
Center

**REFERRING VET**

Dr. Peggy Roberts

**INVOICE**

10928

**DATE**

12/10/2025

**INTERPRETATION OF THE FINDINGS & FURTHER RECOMMENDATIONS**

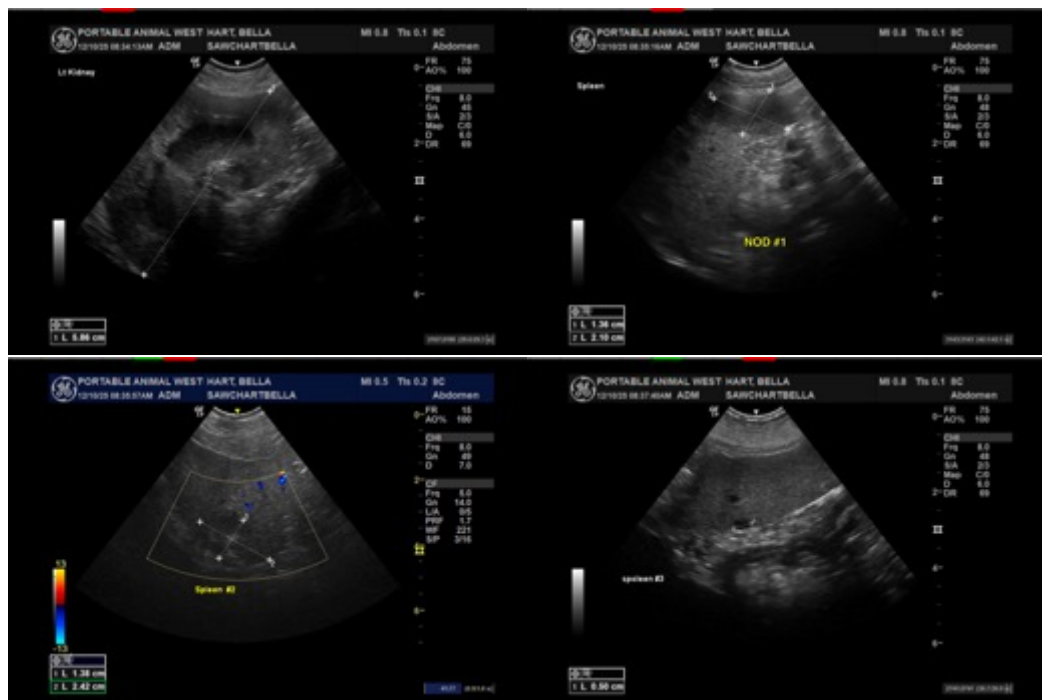
No focal lesions are visualized associated with the GI tract to explain the vomiting and anorexia reported. There is some fluid and ingesta visualized within the gastric lumen and the proximal duodenum is mildly fluid distended. This could be consistent with a non-fasted patient or potentially with ileus. Some sections of small intestine appear mildly thickened with intact wall layering. These changes could be consistent with segmental inflammation. Further evaluation could include the following:

- Consider a novel protein/hydrolyzed protein diet (exclusively at least 4-6 weeks.)
- Consider a GI panel to Texas A&M for evaluation of B12 levels, folate, PLI/TLI etc.. to further evaluate for pancreatic/small intestinal disease.
- Recommend chronic probiotic therapy.

Additionally, upper GI endoscopy could be considered to evaluate the stomach and proximal GI tract for any ulceration, thickening, etc., and to obtain biopsies. Unfortunately, this method would not target the more thickened loops of bowel but could be an intermediate step.

There are multiple hypoechoic areas in the spleen. The significance of these lesions is uncertain. Options moving forward would include a fine needle aspirate or continued monitoring with ultrasound.

The urinary bladder wall appears mildly irregular and thickened. This could be due to lack of urine distension. Correlate with a urinalysis +/- culture results.





### PATIENT

Bella Hart

### SPECIES

Canine

### BREED

Bulldog Mix

### SEX

Spayed Female

### AGE

14 years

### WEIGHT

43 lbs

### INTERPRETED BY

Kathleen Sennello DVM,  
MS, Diplomate ACVIM  
(Small Animal Internal  
Medicine)

### IMAGING PERFORMED BY

Loetitia Saint-Jacques,  
LVT

### HOSPITAL NAME

Sierra Animal Wellness  
Center

### REFERRING VET

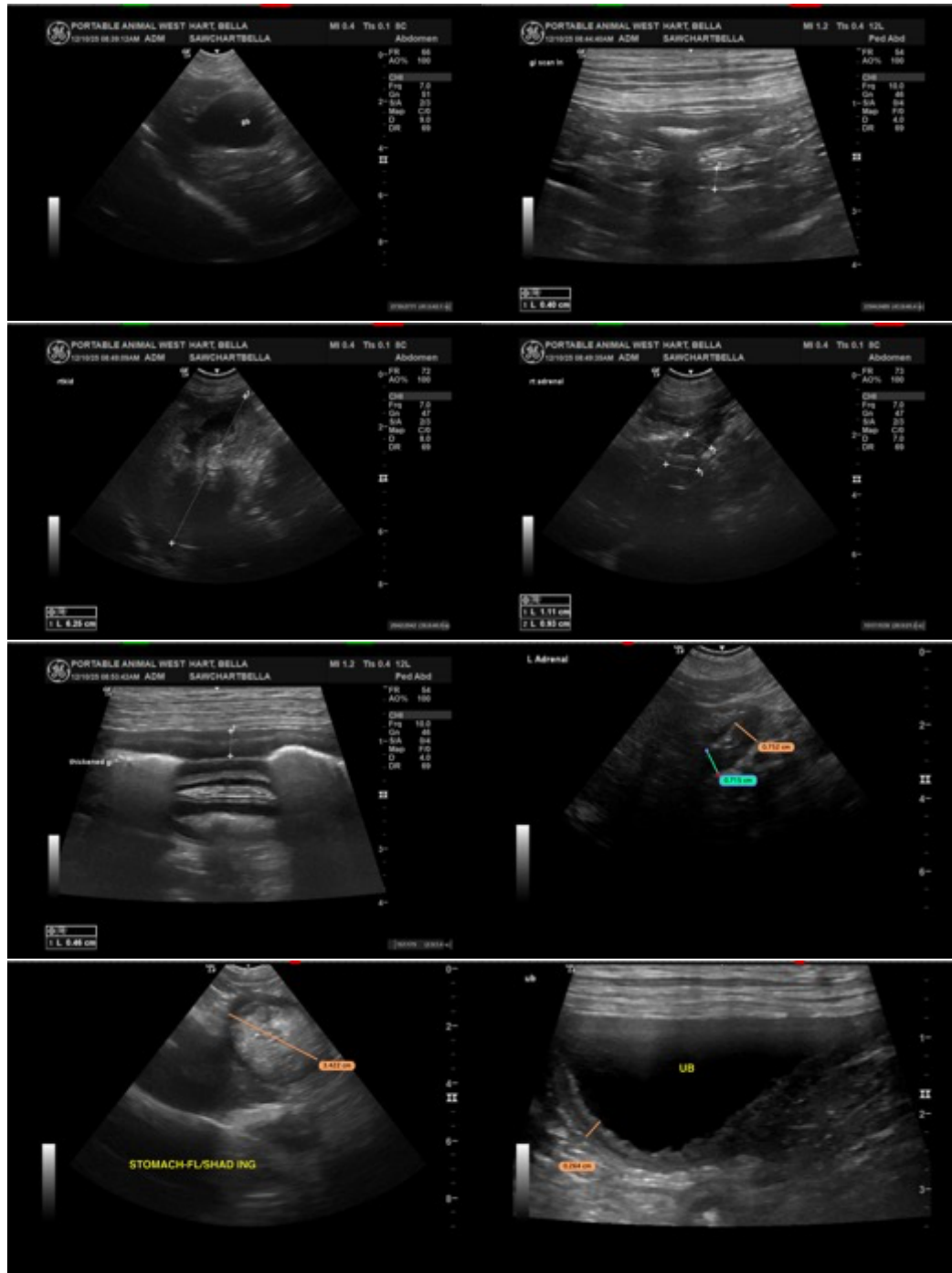
Dr. Peggy Roberts

### INVOICE

10928

### DATE

12/10/2025



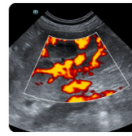
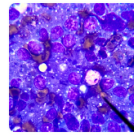
The information and recommendations provided are based on the images presented by the referring veterinarian/sonographer. No evaluation can be communicated regarding pathology that was not visible in the image/video clips provided.

Thank you for this referral. If the clinical or image interpretation does not parallel your findings or if I

Imaging  
performed by



Sierra Animal Wellness Sonography, Inc.  
pawsonography@gmail.com  
530-786-8340



**Clinical Sonography & Telectology**  
Educational Teleconsultation Services™

**SonoPath**

FOSTERING THE ART OF VETERINARY MEDICINE™

SonoPath.com  info@sonopath.com  1.800.838.4268

**PATIENT**

Bella Hart

**SPECIES**

Canine

**BREED**

Bulldgo Mix

**SEX**

Spayed Female

**AGE**

14 years

**WEIGHT**

43 lbs

**INTERPRETED BY**

Kathleen Sennello DVM,  
MS, Diplomate ACVIM  
(Small Animal Internal  
Medicine)

**IMAGING  
PERFORMED BY**

Loetitia Saint-Jacques,  
LVT

**HOSPITAL NAME**

Sierra Animal Wellness  
Center

**REFERRING VET**

Dr. Peggy Roberts

**INVOICE**

10928

**DATE**

12/10/2025

can be of any further assistance please contact me.

Kathleen Sennello DVM,MS, Diplomate ACVIM (Small animal Internal Medicine)

info@sonopath.com