



DATE PRESENTING CLINICAL SIGNS

12/10/21

History: Presenting Complaint: Vomiting. Date: 12-09-2021 Notes: Vomiting since yesterday AM - can't keep water or food down - will vomit 15 minutes after eating - owner noted that it seems more like regurgitation than vomiting, no real abdominal effort. Known to eat socks occasionally - have been found in stool. Has pond and pool that she will drink out of - apparently treatment was given by rdvm to make it safer - will have free roam to go outside when she wants, not monitored. May get occasional pizza crust but none recently - no other known dietary indiscretion. Owner gave small GI pill from last visit (omeprazole vs famotidine) last night - continued to have episodes. Known Lyme disease, was symptomatic and being treated by rdvm - not typically symptomatic, owner discontinued antibiotic after Carprofen incident - recently has seemed to have a bit of a limp. Plan: Reviewed history and physical exam. Discussed lymes disease and treatment course. Discussed ddx: gastroenteritis vs pancreatitis vs obstruction vs kidney disease vs liver disease vs other. Recommended hospitalization, full bw, abdominal rads +/- repeat, fluids, supportive care as needed.

PATIENT

Delilah Potter

SPECIES

Canine

BREED

Rottweiler

SEX

Spayed Female

AGE

8/24/15

WEIGHT

89.4 Pounds

Current Medications: Buprenex, Ampicillin, Pantoprazole.
Lab Results: Attached separately within request.
Radiographs: Circular mass like lesion in the cranial abdomen Apparently distended stomach.
Date of Previous IntraPet Ultrasound: No previous IntraPet scans.
Sedation: Not required to complete full diagnostic ultrasound.
Stat Report: STAT requested.

ULTRASONOGRAPHIC EXAMINATION OF THE ABDOMEN

Urinary System

The urinary bladder is moderately distended with anechoic urine. The Bladder wall, trigone, ureteral papillae and visible urethra (to a depth of 2cm) appear normal with no evidence of wall thickening, mucosal irregularities, masses or cystic calculi.

INTERPRETED BY

Kathleen Sennello DVM,
MS, Diplomate ACVIM
(Small Animal Internal
Medicine)

The left kidney has a normal shape and size (7.58 cm). Overall echogenicity is normal with adequate corticomedullary distinction and a typical 1:3 cortex:medulla ratio. There is no evidence of perinephric inflammation or effusion. There is no evidence of pyelectasia, nephroliths, infarcts or hydroureter. Renal vasculature is normal.

IMAGING PERFORMED BY

Rachel Brillhart RDMS

The right kidney has a normal shape and size (6.15 cm). Overall echogenicity is normal with adequate corticomedullary distinction and a typical 1:3 cortex:medulla ratio. There is no evidence of perinephric inflammation or effusion. There is no evidence of pyelectasia, nephroliths, infarcts or hydroureter. Renal vasculature is normal.

HOSPITAL NAME

Animal Emergency
Hospital

Adrenal Glands

The left adrenal gland is normal in size measuring 0.86 cm at the caudal pole. It is observed in its normal position cranial to the left renal artery. It is normal in appearance (uniformly hypoechoic) and shape with no evidence of a mass effect.

REFERRING VET

Dr. Nacke-Horney

The region of the right adrenal (between right cranial kidney and vena cava) is unremarkable, but the adrenal is not distinctly visualized. No evidence of a mass effect.

Spleen

The spleen is large in size. The spleen echotexture is mildly heterogeneous, the splenic capsule is smooth with no irregularities. The blood flow through the hilus and splenic parenchyma appears normal. There is a large, hyperechoic, solid splenic mass visualized, measuring 6.09 cm x 5.65 cm towards the tail of the spleen.

INVOICE

33381

Liver

The liver is subjectively normal in size, and echogenicity with smooth peripheral margins. The parenchyma is homogenous echotexture. The visible portions of the vasculature and biliary tract appear normal. No focal nodules or cystic lesions are observed.

The gall bladder lumen is moderately distended. The wall of the gall bladder is not thickened and has a smooth mucosal surface. There is a mild amount of non-organized echogenic debris. The cystic and common bile ducts are normal/not visible.

Gastrointestinal

The stomach is severely dilated with fluid and irregular shadowing material. Some of this material is hard shadowing and is likely consistent with foreign material. The gastric wall measures at a normal thickness of <0.7cm with some variability due to the presence of rugal folds. The distinction of the gastric wall layers is adequate and there is no impression of reduced peristaltic activity. There is the suspicion of gastric foreign material and a possible partial gastric outflow tract obstruction.

The small intestine generally appears somewhat thickened and is surrounded by inflamed mesentery. There is severe fluid distention in the stomach and this distends somewhat into the duodenum, where there is the appearance of hard shadowing material most consistent with a foreign body in the area of the mid duodenum. There are areas of more normal appearing jejunum in the more caudal abdomen, but there is additional shadowing material with bowel dilation visualized, which is estimated to be mid jejunal. These findings are very suspicious for multiple areas of foreign material with partial or complete obstruction.

The ileocecal junction was visualized and exhibited normal intact wall layering and is subjectively of normal thickness. Sections of colon are visualized with formed fecal material and gas shadowing distally. There is no observed focal or generalized colon wall thickening or loss of layering.

Pancreas

The pancreas is normal and isoechoic to surrounding mesentery. There is no evidence of nodules or cystic lesions. There is no evidence of regional mesenteric inflammation or fluid.

Free Abdomen

Evaluation of the peritoneal cavity did not reveal any evidence of effusion, or subjective lymphadenomegaly. The Medial iliac nodes appear normal and there was no evidence of a caudal aortic thrombus at the bifurcation. The omentum is of increased echogenicity around the inflamed bowel loops.

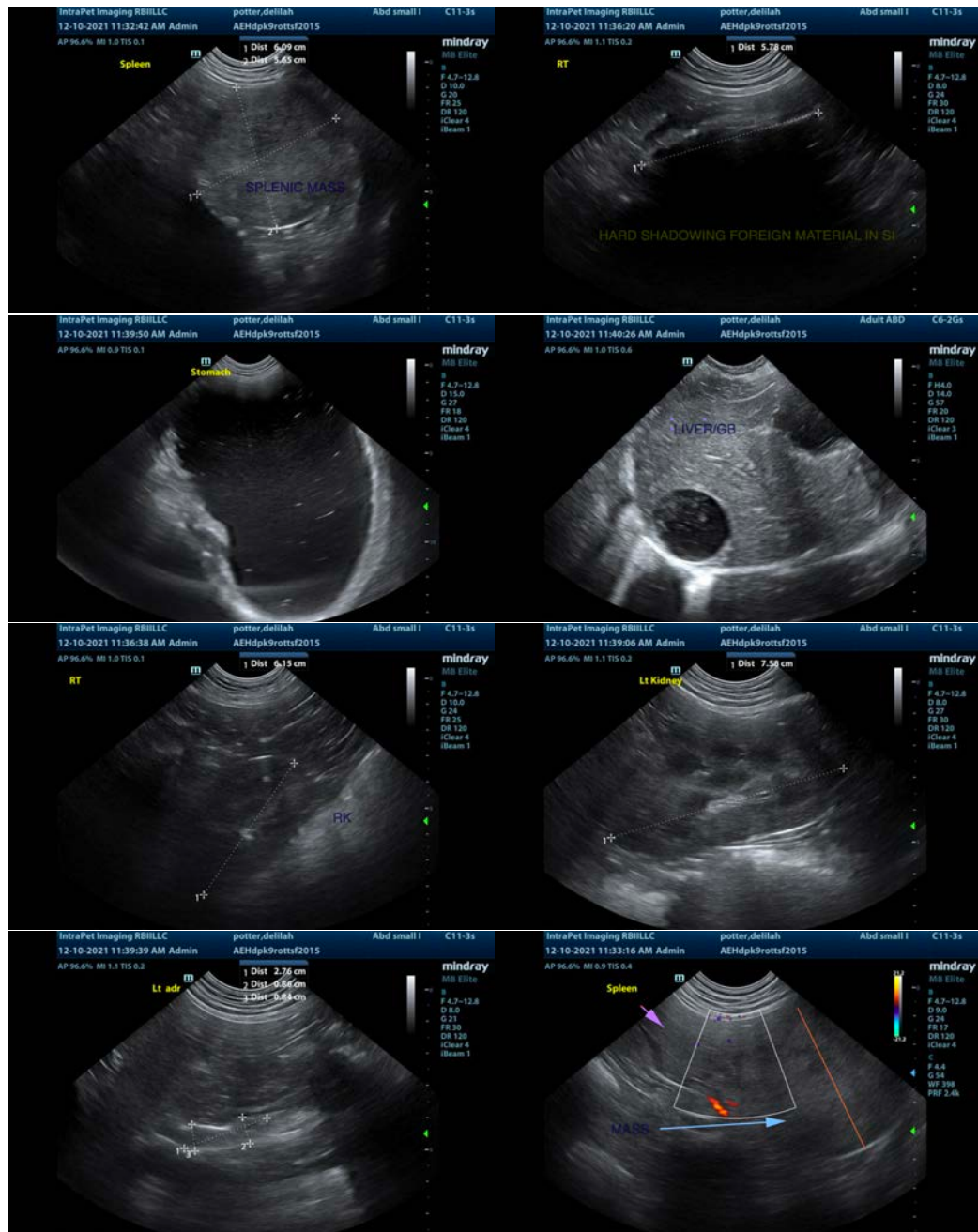
ULTRASONOGRAPHIC FINDINGS

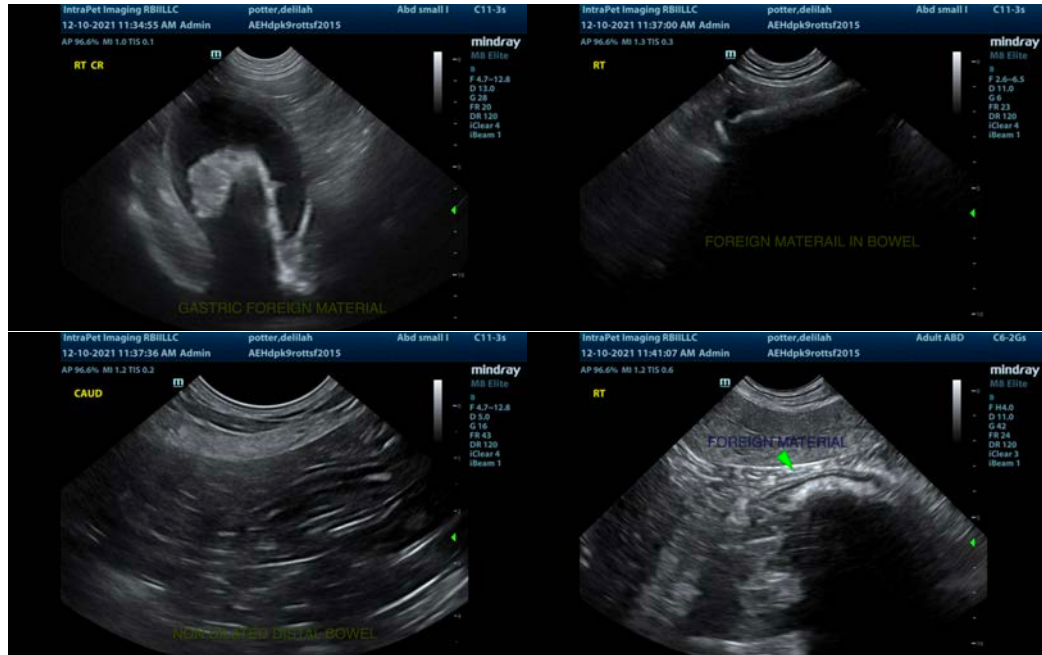
- Severe gastric fluid distention with foreign material visualized in the stomach – There is concern for a partial or complete outflow tract obstruction.
- Areas of shadowing material visualized within dilated loops of small intestine – There is concern for multiple sites of foreign material and possible obstruction.
- Large, solid, hyperechoic splenic mass – A focal, solid, mixed echogenic mass is present within the splenic parenchyma. This mass distorts the splenic capsule. Differentials include benign lesions such as lymphoid hyperplasia, hemangioma, etc., or neoplastic lesions such as hemangiosarcoma, lymphoma, histiocytic sarcoma, etc.

INTERPRETATION OF THE FINDINGS & FURTHER RECOMMENDATIONS

The combination of severe gastric dilation and shadowing material within the stomach and small intestine is highly suspicious for ingesta and foreign material. It is unknown if this material can eventually pass on its

own, but I'm concerned that some of these areas appear to be in the upper GI tract, and it is likely that surgical exploration would be the diagnostic and treatment of choice. Additionally, recommend splenectomy at the time of surgery. Recommend 3-view thoracic radiographs at the time of surgery.





The information and recommendations provided are based on the images presented by the referring veterinarian. No evaluation can be communicated regarding pathology that was not visible in the image/video clips provided.

Thank you for this referral. If the clinical or image interpretation does not parallel your findings or if I can be of any further assistance please contact me.

Kathleen Sennello DVM,MS, Diplomate ACVIM (Small animal Internal Medicine)
kathleen.sennello@sonopath.com