

**DATE PRESENTING CLINICAL SIGNS**

12/1/22 Hx of HW + and treatment this year. On BW for dental for fractured carnassial extraction elevated ALKP/ALT noted and mild weight loss. Opt to postpone dental, do round of abx and recheck liver values in 2 weeks. Recheck BW shows worsening of liver values and additional 1.5lbs of weight loss. U/s recommended

PATIENT

Fenway Tanner Current Medications: Metronidazole, Amoxicillin.

Lab Results: See attached.

SPECIES

Date of Previous IntraPet Ultrasound: No previous.

Canine

Sedation: Not required to complete full diagnostic ultrasound.

Stat Report: Not requested.

BREED

Catahoula

ULTRASONOGRAPHIC EXAMINATION OF THE ABDOMEN**Urinary System**

The urinary bladder is moderately distended with anechoic urine. The Bladder wall, trigone, ureteral papillae and visible urethra (to a depth of 2cm) appear normal with no evidence of wall thickening, mucosal irregularities, masses or cystic calculi.

SEX

Spayed Female

The left kidney has a normal shape and size (6.58 cm). Overall echogenicity is normal with adequate corticomedullary distinction and a typical 1:3 cortex:medulla ratio. There is no evidence of focal perinephric inflammation or effusion. There is no evidence of pyelectasia, nephroliths, infarcts or hydroureter. Renal vasculature is normal.

AGE

7/19/14

WEIGHT

65 Pounds

The right kidney has a normal shape and size (6.29 cm). Overall echogenicity is normal with adequate corticomedullary distinction and a typical 1:3 cortex:medulla ratio. There is no evidence of focal perinephric inflammation or effusion. There is no evidence of pyelectasia, nephroliths, infarcts or hydroureter. Renal vasculature is normal.

INTERPRETED BY

Kathleen Sennello DVM,
MS, Diplomate ACVIM
(Small Animal Internal
Medicine)

Adrenal Glands

The left adrenal gland is normal in size measuring 0.79 cm at the caudal pole. It is observed in its normal position cranial to the left renal artery. It is normal in appearance (uniformly hypoechoic) and shape with no evidence of a mass effect.

IMAGING PERFORMED BY

Rachel Brilhart RDMS

The right adrenal gland is normal in size measuring 0.66 cm at the caudal pole. It is observed in its normal position between the cranial aspect of the right kidney and the caudal vena cava. It is normal in appearance (uniformly hypoechoic) and shape with no evidence of a mass effect.

HOSPITAL NAME

Bayside AMC

Spleen

The spleen is subjectively normal in size. The spleen echotexture is heterogenous and mottled, the splenic capsule is smooth with no irregularities. The blood flow through the hilus and splenic parenchyma appears normal. No focal parenchymal abnormalities are visualized.

REFERRING VET

Dr. Buchanan

Liver

The liver is large in size, and hypoechoic with smooth peripheral margins. The parenchyma is heterogenous in echotexture with subtle, indistinct focal mottling. The visible portions of the vasculature and biliary tract appear normal. No focal nodules or cystic lesions are observed.

INVOICE

43110

The gallbladder lumen is moderately distended. The wall of the gall bladder is not thickened and has a smooth mucosal surface. Luminal contents are mild and primarily anechoic. The cystic and common bile ducts are normal/not visible.

Gastrointestinal

The stomach is moderately dilated with fluid and irregular shadowing material most consistent with normal ingesta and gas. It measures at a normal thickness of <0.7cm with some variability due to the presence of rugal folds. The distinction of the gastric wall layering is adequate and there is no impression of reduced peristaltic activity. No masses or focal lesions were observed.

The visualized areas of duodenum, jejunum and ileum have a relatively uniform diameter with minimal fluid distension. Wall thickness is normal. Bowel loops follow a curvilinear path with distinct wall layering maintaining the typical 1:3 muscularis:mucosa layer ratio. Jejunum wall measures 0.27 cm. Visualized peristalsis appears appropriate. There were no focal lesions consistent with obstruction or a mass effect observed.

The ileocecal junction was visualized and exhibited normal intact wall layering and is subjectively of normal thickness. Sections of colon are visualized with formed fecal material and gas shadowing distally. There is no observed focal or generalized colon wall thickening or loss of layering.

Pancreas

The pancreas is prominent, large, irregular, and mottled compared to the surrounding isoechoic mesentery. There is no evidence of nodules or cystic lesions. There is very mild regional mesenteric inflammation. No fluid noted.

Free Abdomen

Evaluation of the peritoneal cavity did not reveal any evidence of effusion, or subjective lymphadenomegaly. The Medial iliac nodes appear normal and there was no evidence of a caudal aortic thrombus at the bifurcation. The mesentery appears hyperechoic in the cranial abdomen, around the pancreas and liver.

Other

A brief view of the heart was submitted. No significant pericardial effusion was seen.

ULTRASONOGRAPHIC FINDINGS

- Mildly mottled spleen – The diffuse splenic changes are non-specific and could be consistent with lymphoid hyperplasia, extramedullary hematopoiesis, infiltrative neoplasia, inflammation, other. Cytology or histopathology would be necessary to get a definitive diagnosis.
- Large, irregular, mottled pancreas – The changes observed in the pancreas could be consistent with mild inflammation, previous episodes of inflammation, or less likely neoplastic change.
- Large, hypoechoic, heterogeneous liver – The diffuse hepatic changes are non-specific and could be consistent with vacuolar hepatopathy, nodular hyperplasia, inflammatory/immune-mediated disease, fibrosis, extramedullary hematopoiesis, toxic hepatopathy (e.g., copper), infiltrative neoplasia (less likely) or other hepatopathy.

INTERPRETATION OF THE FINDINGS & FURTHER RECOMMENDATIONS

The liver appears large and heterogeneous with surrounding hyperechoic mesentery. Additionally, the pancreas is large, prominent, and mottled, so it is difficult to tell if the surrounding inflammation is secondary to the liver or pancreas, although the changes in the pancreas do not look like typical acute pancreatitis. No focal lesions were visualized within the liver or the biliary tract. Recommend further evaluation.

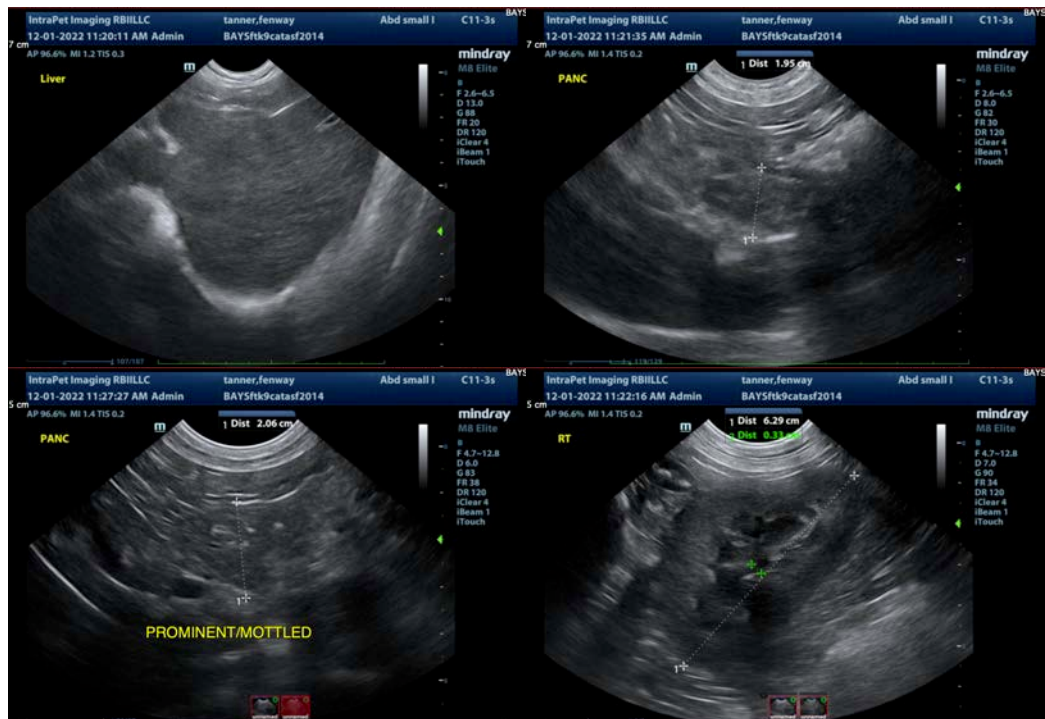
- Consider close evaluation of history for possible toxic changes examine medications, diet, dietary indiscretion etc...

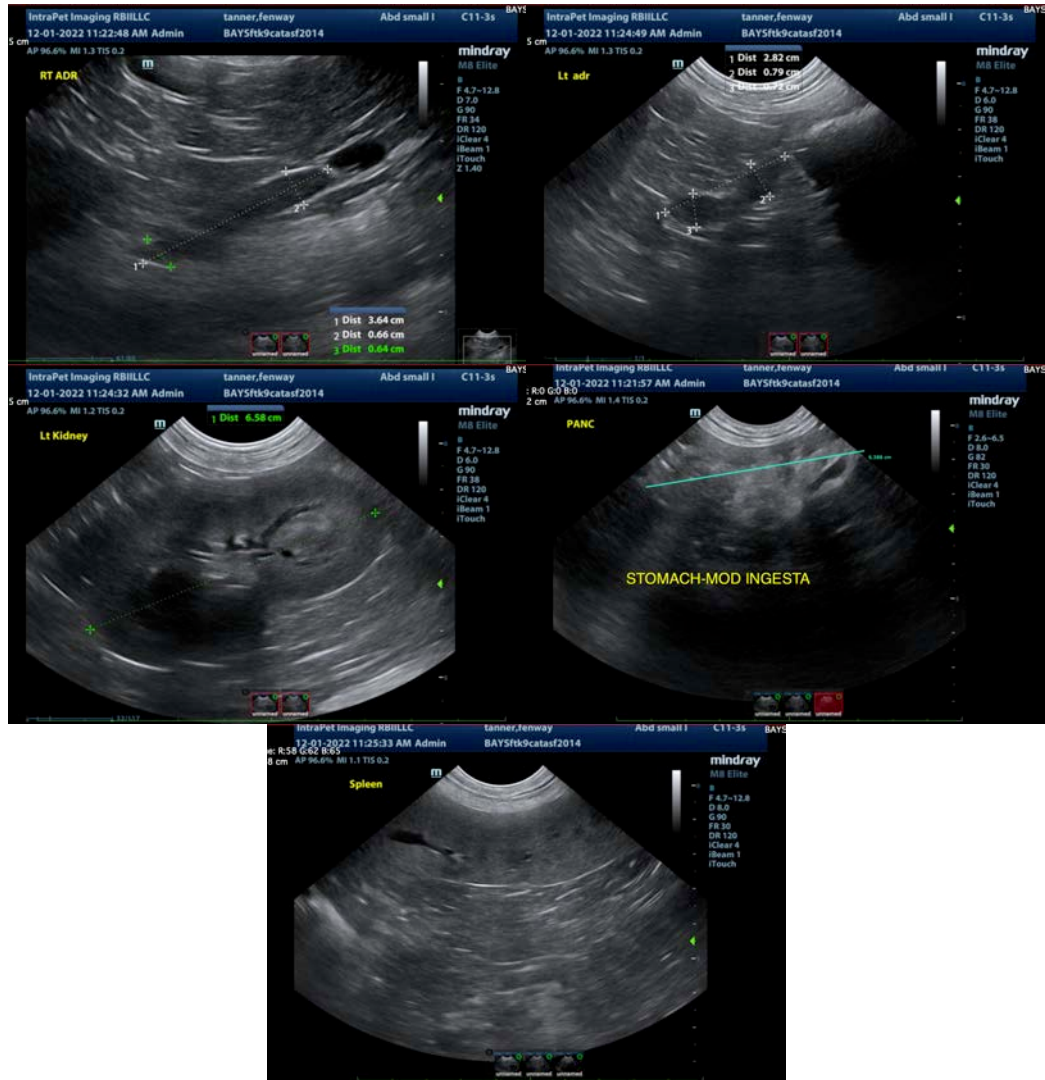
- Consider PCR on urine/serum for leptospirosis (if not on antibiotics)/serology if recent antibiotic history
- If not already done, consider pre and post prandial bile acids to evaluate liver function
- Consider Fine needle aspirate if round cell neoplasia is on your differential list (25 g needle, normal coags)
- If no response to supportive care (Denamarin, fluids, antibiotics, +/- ursodiol etc.) Consider liver biopsy with samples obtained for histopathology, culture, and copper levels.

Additionally, consider quantitative PLI level and symptomatic treatment for chronic pancreatitis. If symptoms are persisting, you could consider a fine needle aspirate of the pancreas.

The changes in the spleen are somewhat subtle, but it does appear subjectively mottled. A fine needle aspirate of the spleen could be considered.

Recommend three view thoracic radiographs to evaluate for possible concurrent thoracic disease/involvement.





The information and recommendations provided are based on the images presented by the referring veterinarian/sonographer. No evaluation can be communicated regarding pathology that was not visible in the image/video clips provided.

Thank you for this referral. If the clinical or image interpretation does not parallel your findings or if I can be of any further assistance please contact me.

Kathleen Sennello DVM,MS, Diplomate ACVIM (Small animal Internal Medicine)
 kathleen.sennello@sonopath.com