



PATIENT

Bella Hirstius

SPECIES

Canine

BREED

Basset Hound X

SEX

Spayed Female

AGE

10 Years

WEIGHT

47 Pounds

INTERPRETED BY

Kathleen Sennello DVM,
MS, Diplomate ACVIM
(Small Animal Internal
Medicine)

**IMAGING
PERFORMED BY**

Kelly Vazquez

HOSPITAL NAME

Ramapo Valley AH

REFERRING VET

Dr. Katara

INVOICE

43101

DATE

12/1/22

PRESENTING CLINICAL SIGNS

Patient presents for rapid weight loss, was 66 lbs, current weight is 47 lbs. Decreased appetite, liquid diarrhea, very unusual appearance to abdomen on radiographs; concern for possible neoplasia. Current med: mirtazapine.

ULTRASONOGRAPHIC EXAMINATION OF THE ABDOMEN

Urinary System

The urinary bladder is moderately distended with anechoic urine. The Bladder wall, trigone, ureteral papillae and visible urethra (to a depth of 2cm) appear normal with no evidence of wall thickening, mucosal irregularities, masses or cystic calculi.

The left kidney is large and irregular in shape, measuring 7.29 cm. Overall echogenicity is normal with adequate corticomedullary distinction and a typical 1:3 cortex:medulla ratio. There is no evidence of focal perinephric inflammation or effusion. There is no evidence of pyelectasia, nephroliths, infarcts or hydroureter. There is a large, solid, hypoechoic, irregular mass effect visualized in the caudal pole of the left kidney measuring 3.79 cm x 2.81 cm.

The right kidney has a normal shape and size (7.31 cm). Overall echogenicity is normal with adequate corticomedullary distinction and a typical 1:3 cortex:medulla ratio. There is no evidence of focal perinephric inflammation or effusion. There is no evidence of pyelectasia, nephroliths, infarcts or hydroureter. Renal vasculature is normal.

Adrenal Glands

The left adrenal gland is normal in size measuring 0.73 cm at the caudal pole. It is observed in its normal position cranial to the left renal artery. It is normal in appearance (uniformly hypoechoic) and shape with no evidence of a mass effect.

The right adrenal gland is normal in size measuring 0.77 cm at the caudal pole. It is observed in its normal position between the cranial aspect of the right kidney and the caudal vena cava. It is normal in appearance (uniformly hypoechoic) and shape with no evidence of a mass effect.

Spleen

The spleen is subjectively normal in size, echotexture is homogenous, and the splenic capsule is smooth with no irregularities. The blood flow through the hilus and splenic parenchyma appears normal. There is a small hypoechoic lesion visualized within the parenchyma measuring 0.60 cm x 0.36 cm.

Liver

The liver is subjectively normal in size, and echogenicity with smooth peripheral margins. The parenchyma is homogenous echotexture. The visible portions of the vasculature and biliary tract appear normal. There is a large, solid, mixed echogenic, irregular mass effect visualized on the left side of the liver, measuring 4.06 cm x 2.63 cm. Additionally, there is a similar appearing, somewhat target-like lesion visualized in the mid to left liver, measuring 1.66 cm x 1.71 cm, and a hypoechoic lesion most consistent with a benign cystic lesion measuring 1.17 cm x 0.78 cm.

The gallbladder lumen is moderately distended. The wall of the gall bladder is not thickened and has a smooth mucosal surface. Luminal contents are mild and primarily anechoic. The cystic and common bile ducts are normal/not visible.



PATIENT

Gastrointestinal

Bella Hirstius

The stomach contains moderate fluid. It measures at a normal thickness of <0.7cm with some variability due to the presence of rugal folds. The distinction of the gastric wall layers is adequate and there is no impression of reduced peristaltic activity. No masses or focal lesions were observed.

SPECIES

Canine

The visualized areas of duodenum, jejunum and ileum have a relatively uniform diameter with minimal fluid distension. Wall thickness is normal. Bowel loops follow a curvilinear path with distinct wall layering maintaining the typical 1:3 muscularis:mucosa layer ratio. The duodenum measured as normal (between 0.3-0.5cm in wall thickness) and the jejunum measured as normal (between 0.2-0.47cm.)

BREED

Basset Hound X

Visualized peristalsis appears appropriate. There were no focal lesions consistent with obstruction or a mass effect observed.

SEX

Spayed Female

The ileocecal junction was visualized and exhibited normal intact wall layering and is subjectively of normal thickness. Sections of colon are visualized with formed fecal material and gas shadowing distally. There is no observed focal or generalized colon wall thickening or loss of layering.

Pancreas

AGE

10 Years

The pancreas is normal and isoechoic to surrounding mesentery. There is no evidence of nodules or cystic lesions. There is no evidence of regional mesenteric inflammation or fluid.

Free Abdomen

WEIGHT

47 Pounds

Evaluation of the peritoneal cavity did not reveal any evidence of effusion. There is a large iliac lymph node visualized measuring 3.23 cm x 1.23 cm. The omentum is slightly hyperechoic around the lymph node.

ULTRASONOGRAPHIC FINDINGS

INTERPRETED BY

Kathleen Sennello DVM,
MS, Diplomate ACVIM
(Small Animal Internal
Medicine)

- Solid, hypoechoic, irregular mass effect in the caudal pole of the left kidney – Findings are concerning for a mass effect. Differentials include a carcinoma, adenoma, hemangiosarcoma, other.
- Small, hypoechoic splenic nodule – There is a non-cavitated, hypoechoic splenic nodule visualized. Differentials include lymphoid hyperplasia, extramedullary hematopoiesis, infiltrative neoplasia, inflammation, other. Cytology or histopathology would be necessary to get a definitive diagnosis.
- Multiple expansile hypoechoic, mixed echogenic masses within the liver – Findings are concerning for possible metastatic lesions, but other differentials exist.
- Large iliac lymph node – This could represent an inflammatory, reactive, infectious, or neoplastic process.

IMAGING PERFORMED BY

Kelly Vazquez

HOSPITAL NAME

Ramapo Valley AH

REFERRING VET

Dr. Katara

INTERPRETATION OF THE FINDINGS & FURTHER RECOMMENDATIONS

There is a mass visualized on the caudal pole of the left kidney. Additionally, there are similar appearing mass lesions in the liver and an enlarged lymph node. These findings are concerning for possible metastatic neoplasia, although other differentials are possible. Recommend a fine needle aspirate of the caudal pole of the left kidney and a hepatic mass (provided coagulation parameters and blood pressure are normal). Additionally, recommend 3-view thoracic radiographs. If not already done, recommend a rectal exam to evaluate the anal glands and any other locations for a possible primary mass lesion. If a cytologic diagnosis cannot be obtained, consider obtaining surgical biopsies.

INVOICE

43101

DATE

12/1/22



PATIENT

Bella Hirstius

SPECIES

Canine

BREED

Basset Hound X

SEX

Spayed Female

AGE

10 Years

WEIGHT

47 Pounds

INTERPRETED BY

Kathleen Sennello DVM,
MS, Diplomate ACVIM
(Small Animal Internal
Medicine)

**IMAGING
PERFORMED BY**

Kelly Vazquez

HOSPITAL NAME

Ramapo Valley AH

REFERRING VET

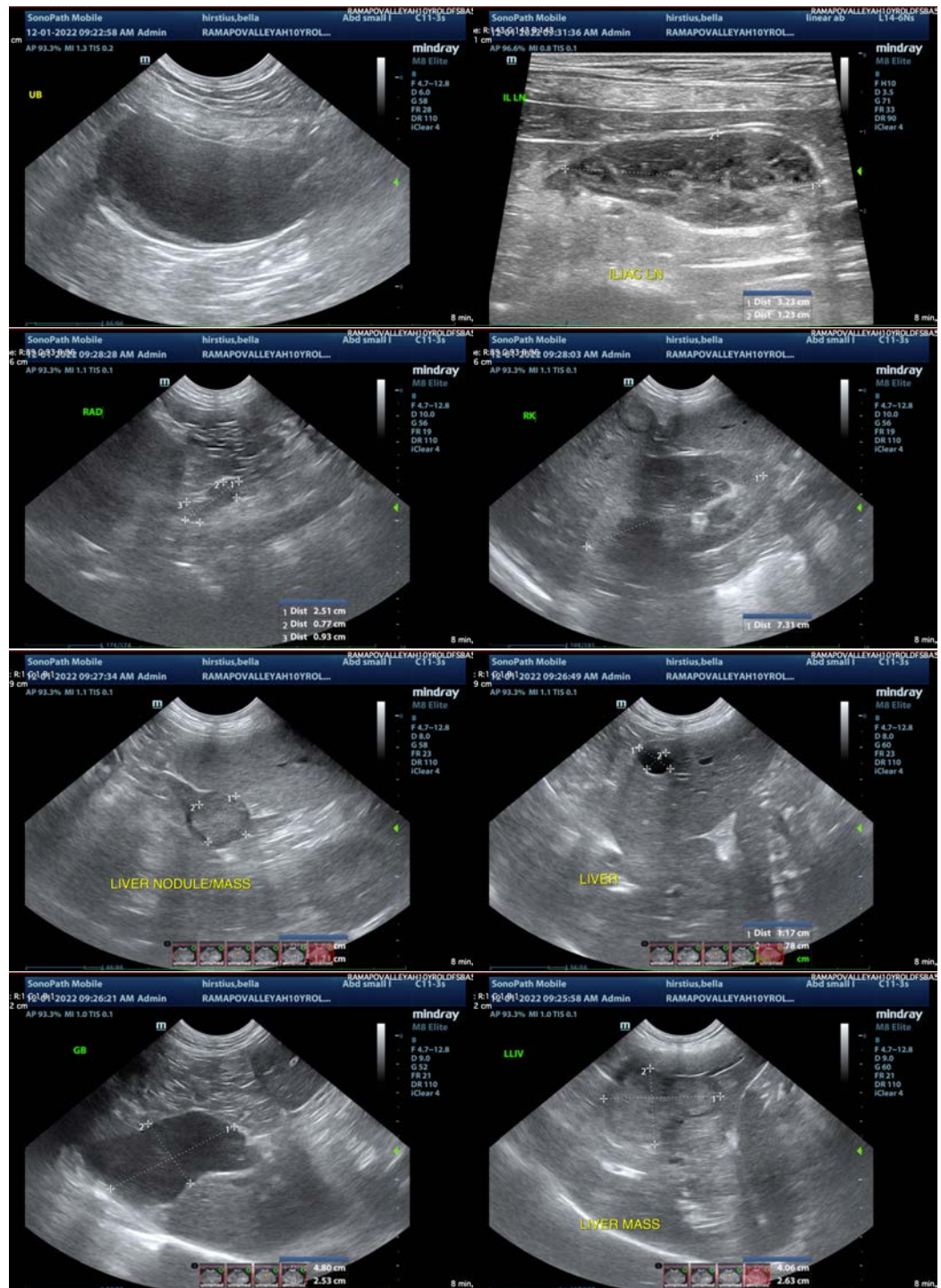
Dr. Katara

INVOICE

43101

DATE

12/1/22





PATIENT

Bella Hirstius

SPECIES

Canine

BREED

Basset Hound X

SEX

Spayed Female

AGE

10 Years

WEIGHT

47 Pounds

INTERPRETED BY

Kathleen Sennello DVM,
MS, Diplomate ACVIM
(Small Animal Internal
Medicine)

**IMAGING
PERFORMED BY**

Kelly Vazquez

HOSPITAL NAME

Ramapo Valley AH

REFERRING VET

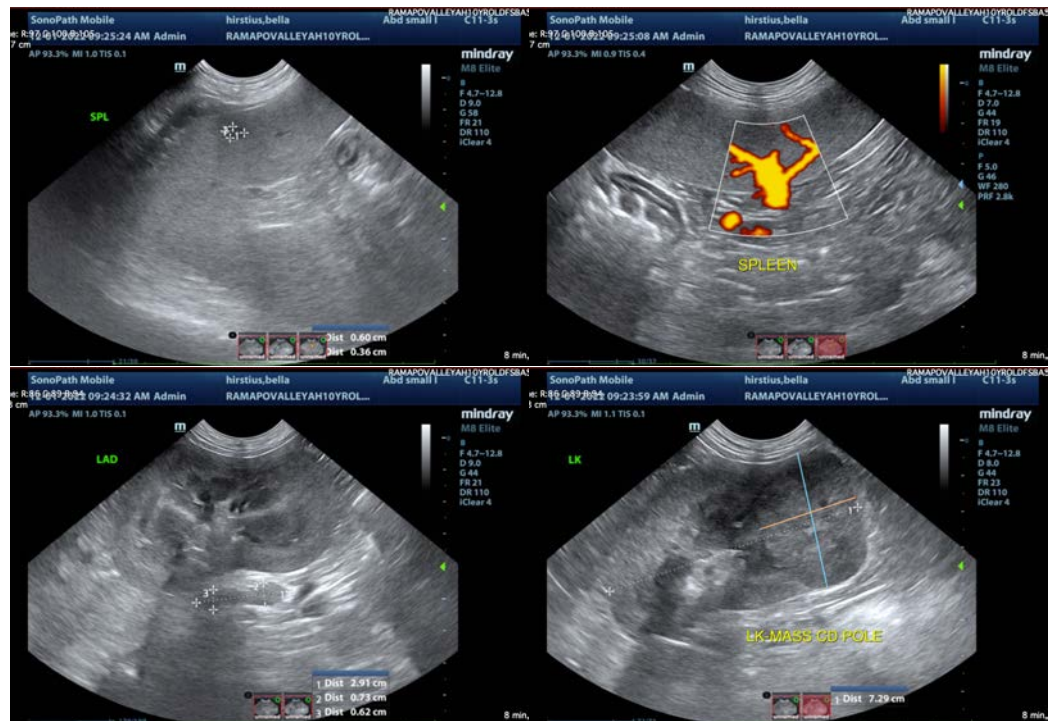
Dr. Katara

INVOICE

43101

DATE

12/1/22



The information and recommendations provided are based on the images presented by the referring veterinarian/sonographer. No evaluation can be communicated regarding pathology that was not visible in the image/video clips provided.

Thank you for this referral. If the clinical or image interpretation does not parallel your findings or if I can be of any further assistance please contact me.

Kathleen Sennello DVM,MS, Diplomate ACVIM (Small animal Internal Medicine)

kathleen.sennello@sonopath.com