



PATIENT

Zara Crivon

SPECIES

Canine

BREED

King Charles Cavalier

SEX

Spayed Female

AGE

10 ½ years

WEIGHT

24.4 lbs

INTERPRETED BY

Kathleen Sennello
DVM, MS, Diplomate
ACVIM (Small Animal
Internal Medicine)

IMAGING PERFORMED BY

Dr. Sorbo

HOSPITAL NAME

Back Bay VC

REFERRING VET

Dr. Sager-Gellerman

INVOICE

94253

DATE

12/1/21

PRESENTING CLINICAL SIGNS

History: Historically elevated ALP. No clinical signs of liver disease. Has mildly progressed over past year. No PU/PD, no vomiting, no lethargy, no abdominal pain. UC:CR WNL. ALP has trended up from 140 U/L in March 2019 --> 394 U/L as of 11/2021

ULTRASONOGRAPHIC EXAMINATION OF THE ABDOMEN

Urinary System

The urinary bladder is moderately distended with anechoic urine. The bladder wall, trigone, ureteral papillae and visible urethra (to a depth of 2cm) appear normal with no evidence of wall thickening, masses or cystic calculi. In some images there is mild, diffuse, mucosal irregularity to the urinary bladder wall. This could be consistent with cystitis or lack of significant urine distension.

The left kidney has a normal shape and size (4.75 cm). Overall echogenicity is normal with adequate corticomedullary distinction and a typical 1:3 cortex:medulla ratio. There is no evidence of perinephric inflammation or effusion. There is no evidence of pyelectasia, nephroliths, infarcts or hydroureter. Renal vasculature is normal.

The right kidney has a normal shape and size (4.0 cm). Overall echogenicity is normal with adequate corticomedullary distinction and a typical 1:3 cortex:medulla ratio. There is no evidence of perinephric inflammation or effusion. There is no evidence of pyelectasia, nephroliths, infarcts or hydroureter. Renal vasculature is normal.

Adrenal Glands

The left adrenal gland is normal in size measuring 0.67 cm at the caudal pole It is observed in its normal position cranial to the left renal artery. It is normal in appearance (uniformly hypoechoic) and shape with no evidence of a mass effect.

The right adrenal gland is normal in size measuring 0.5 cm at the caudal pole It is observed in its normal position between the cranial aspect of the right kidney and the caudal vena cava. It is normal in appearance (uniformly hypoechoic) and shape with no evidence of a mass effect.

Spleen

The spleen is subjectively normal in size, echotexture is homogenous, and the splenic capsule is smooth with no irregularities. The blood flow through the hilus and splenic parenchyma appears normal. No focal parenchymal abnormalities are visualized.

Liver

The liver is subjectively normal in size, and echogenicity with smooth peripheral margins. The parenchyma is heterogenous in echotexture with subtle, indistinct focal mottling. The visible portions of the vasculature and biliary tract appear normal. No focal nodules or cystic lesions are observed. The



PATIENT

Zara Crivon

gallbladder lumen is moderately distended. The wall of the gallbladder is not thickened and has a smooth mucosal surface. Luminal contents are primarily anechoic. The cystic and common bile ducts are normal/not visible.

SPECIES

Canine

Gastrointestinal

The stomach contains minimal luminal contents. It measures at a normal thickness of <0.7cm with some variability due to the presence of rugal folds. The distinction of the gastric wall layers is adequate and there is no impression of reduced peristaltic activity. No masses or focal lesions were observed.

BREED

King Charles Cavalier

The visualized areas of duodenum, jejunum and ileum have a relatively uniform diameter with minimal fluid distension. Wall thickness is normal. Bowel loops follow a curvilinear path with distinct wall layering maintaining the typical 1:3 muscularis:mucosa layer ratio. The duodenum measured as normal (0.38 cm) and the jejunum measured as normal (0.33 cm). Visualized peristalsis appears appropriate. There were no focal lesions consistent with obstruction or a mass effect observed.

SEX

Spayed Female

AGE

10 ½ years

The ileocecal junction was visualized and exhibited normal intact wall layering and is subjectively of normal thickness. Sections of colon are visualized with formed fecal material and gas shadowing distally. There is no observed focal or generalized colon wall thickening or loss of layering.

WEIGHT

24.4 lbs

Pancreas

The pancreas is normal and isoechoic to surrounding mesentery. There is no evidence of nodules or cystic lesions. There is no evidence of regional mesenteric inflammation or fluid.

INTERPRETED BY

Kathleen Sennello
DVM, MS, Diplomate
ACVIM (Small Animal
Internal Medicine)

Free Abdomen

Evaluation of the peritoneal cavity did not reveal any evidence of effusion, or subjective lymphadenomegaly. The Medial iliac nodes appear normal and there was no evidence of a caudal aortic thrombus at the bifurcation. The omentum is of normal uniform echogenicity.

IMAGING PERFORMED BY

Dr. Sorbo

ULTRASONOGRAPHIC FINDINGS

PRIMARY FINDINGS:

Large heterogenous liver. The diffuse hepatic changes are non-specific and could be consistent with vacuolar hepatopathy, nodular hyperplasia, inflammatory/immune-mediated disease, fibrosis, extramedullary hematopoiesis, toxic hepatopathy (e.g., copper), infiltrative neoplasia (less likely) or other hepatopathy.

HOSPITAL NAME

Back Bay VC

REFERRING VET

Dr. Sager-Gellerman

SECONDARY FINDINGS:

INVOICE

94253

Mild mucosal irregularity to the urinary bladder wall.

Irregular bladder mucosa/not full bladder.

DATE

12/1/21



PATIENT

Zara Crivon

SPECIES

Canine

BREED

King Charles Cavalier

SEX

Spayed Female

AGE

10 ½ years

WEIGHT

24.4 lbs

INTERPRETED BY

Kathleen Sennello
DVM, MS, Diplomate
ACVIM (Small Animal
Internal Medicine)

IMAGING PERFORMED BY

Dr. Sorbo

HOSPITAL NAME

Back Bay VC

REFERRING VET

Dr. Sager-Gellerman

INVOICE

94253

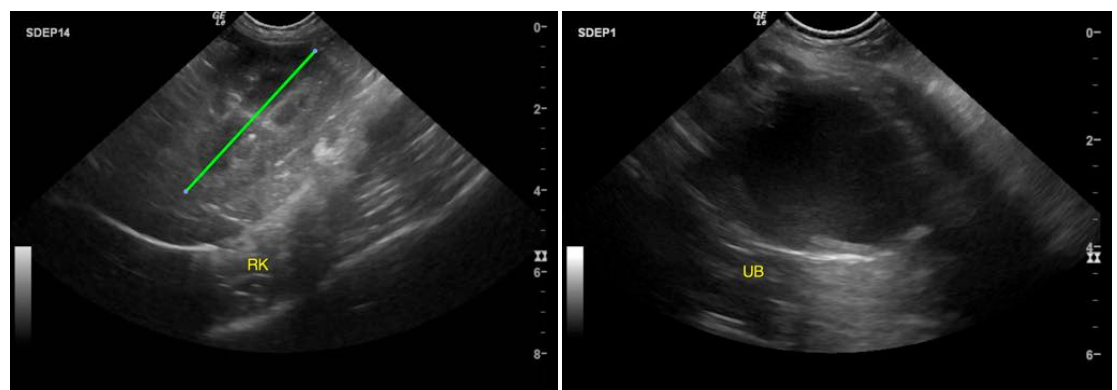
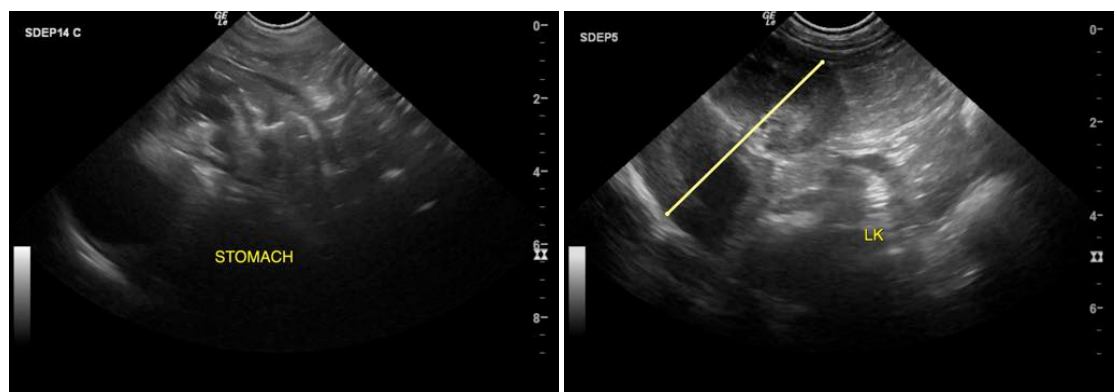
DATE

12/1/21

INTERPRETATION OF THE FINDINGS & FURTHER RECOMMENDATIONS

No focal lesions are observed associated with the liver or gallbladder. The liver itself is somewhat large and rounded. This is a non-specific findings. These are my recommendations for a dog with no focal lesions and an elevation in ALP:

- Induction phenomena are the most common causes for an elevation in ALP. These are systemic illnesses that 'turn on' the liver enzyme. Causes of this include Cushing's disease, dental disease, arthritis, and numerous others. In many cases the exact cause is unclear but as long as ultrasound and bile acids tests are normal most patients do not have progressive changes in their liver. While liver biopsy is not routinely performed, vacuolar hepatopathy, is noted on most biopsies. This is often non-progressive but in rare cases can be more severe and lead to liver failure.
- If signs of Cushing's disease are present recommend endocrine function testing to evaluate for Cushing's disease.
- Consider fine needle aspirate to rule out round cell neoplasia -if this is a concern.
- If a cause for the ALP elevation is not identified: I recommend recheck general blood work every 6 months, ultrasound once per year, and bile acids test every 1-2 years based on other results. If the ALP continues to climb a biopsy could be considered.
- Consider long term use of Denamarin, and monitoring for the signs of Cushing's developing.
- A primary vacuolar hepatopathy can be breed related and is seen in Scottish Terriers, Schnauzers, Cocker spaniels etc..





PATIENT

Zara Crivon

SPECIES

Canine

BREED

King Charles Cavalier

SEX

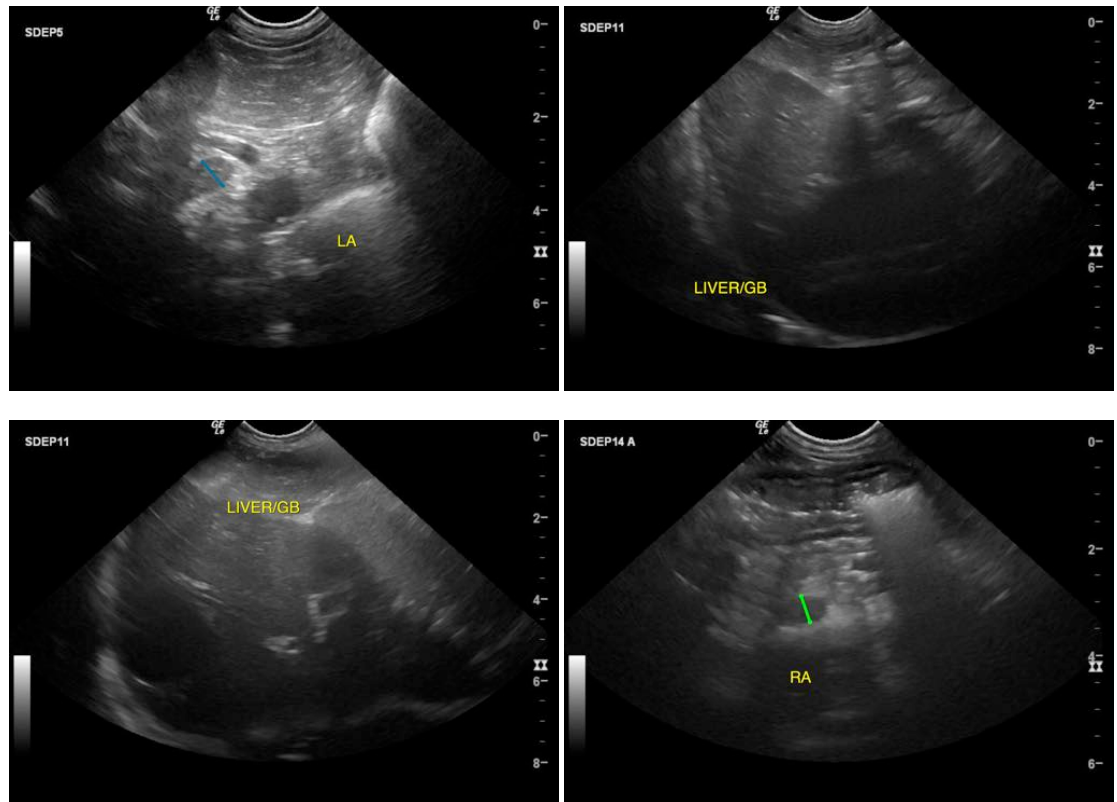
Spayed Female

AGE

10 ½ years

WEIGHT

24.4 lbs



INTERPRETED BY

Kathleen Sennello
DVM, MS, Diplomate
ACVIM (Small Animal
Internal Medicine)

**IMAGING
PERFORMED BY**

Dr. Sorbo

HOSPITAL NAME

Back Bay VC

REFERRING VET

Dr. Sager-Gellerman

INVOICE

94253

DATE

12/1/21

The information and recommendations provided are based on the images presented by the referring veterinarian. No evaluation can be communicated regarding pathology that was not visible in the image/video clips provided.

Thank you for this referral. If the clinical or image interpretation does not parallel your findings or if I can be of any further assistance please contact me.

Kathleen Sennello DVM,MS, Diplomate ACVIM (Small animal Internal Medicine)
kathleen.sennello@sonopath.com