


**PATIENT**

Gatsby Miller

**PRESENTING CLINICAL SIGNS**

Intra-abdominal mass palpated, mass effect in xrays. History of anorexia, diarrhea, vomiting about 5 times daily. Has had a few recent diet changes. Sq Fluids and Buprenorphine.

**SPECIES**

Feline

**ULTRASONOGRAPHIC EXAMINATION OF THE ABDOMEN**
**Urinary System**
**BREED**

DSH

The urinary bladder is moderately distended with mild primarily suspended echogenic debris present. The Bladder wall, trigone, ureteral papillae and visible urethra (to a depth of 2cm) appear normal with no evidence of wall thickening, mucosal irregularities, masses or calculi. Echogenic debris of this type can be associated with small crystals, cellular debris and proteinaceous debris.

**SEX**

Neutered Male

The left kidney is large, measuring 4.55 cm. Overall echogenicity is slightly hyperechoic with poor corticomedullary distinction and a typical 1:3 cortex:medulla ratio. There is no evidence of perinephric inflammation or effusion. There is no evidence of pyelectasia, nephroliths, infarcts or hydroureter. Renal vasculature is normal.

**AGE**

6 Years

The right kidney is small and irregular shape, measuring 2.37 cm. It has a complete loss of corticomedullary distinction with very abnormal architecture. There is no evidence of perinephric inflammation or effusion. There is no distinct pyelectasia or nephroliths. The kidney appears shrunken and fibrotic. Renal vasculature is normal, but blood flow appears diminished.

**WEIGHT**

3.5 kg

**Adrenal Glands**

The left adrenal gland is normal in size measuring 0.27 cm at the caudal pole. It is observed in its normal position cranial to the left renal artery. It is normal in appearance (uniformly hypoechoic) and shape with no evidence of a mass effect.

**INTERPRETED BY**

Kathleen Sennello  
 DVM, MS, Diplomate  
 ACVIM (Small Animal  
 Internal Medicine)

The right adrenal gland is normal in size measuring 0.23 cm at the caudal pole. It is observed in its normal position between the cranial aspect of the right kidney and the caudal vena cava. It is normal in appearance (uniformly hypoechoic) and shape with no evidence of a mass effect.

**Spleen**
**IMAGING PERFORMED BY**

Crystal Hill

The spleen is subjectively normal in size, echotexture is homogenous, and the splenic capsule is smooth with no irregularities. The blood flow through the hilus and splenic parenchyma appears normal. No focal parenchymal abnormalities are visualized.

**HOSPITAL NAME**

Simcoe Animal Hospital

**Liver**

The liver is subjectively normal in size, and echogenicity with smooth peripheral margins. The parenchyma is homogenous echotexture. The visible portions of the vasculature and biliary tract appear normal. No focal nodules or cystic lesions are observed.

**REFERRING VET**

Dr. Aliaga-Leyton

The gallbladder lumen is moderately distended. The wall of the gall bladder is not thickened and has a smooth mucosal surface. Luminal contents are primarily anechoic. The cystic and common bile ducts are normal/not visible.

**INVOICE**

33158

**Gastrointestinal**

The stomach contains minimal luminal contents. It measures at a normal thickness of <0.36cm with some variability due to the presence of rugal folds. The distinction of the gastric wall layers is adequate and there is no impression of reduced peristaltic activity. No masses or focal lesions were observed.

**DATE**

12/1/21



**PATIENT**

Gatsby Miller

Some of the visualized areas of duodenum, jejunum and ileum have a uniform diameter with minimal fluid distension. Other areas appear somewhat thickened with a prominent muscularis layer, verging on loss of detail of the wall layering. The more normal areas of jejunum measure 0.3 cm. In the mid/caudal abdomen, there is a large, ill-defined, hypoechoic mass lesion measuring 1.59 cm x 3.47 cm. This appears to be involving the bowel but is also in the area of the pancreas. This mass lesion is most consistent with a hypoechoic ill-defined bowel mass.

**SPECIES**

Feline

The ileocecal junction was visualized and exhibited normal intact wall layering and is subjectively of normal thickness. Sections of colon are visualized with formed fecal material and gas shadowing distally. There is no observed focal or generalized colon wall thickening or loss of layering.

**BREED**

DSH

**Pancreas**

The pancreas is prominent and hypoechoic as compared to the surrounding isoechoic mesentery. There is an ill-defined mass effect in the area of the pancreas, which I suspect to be of bowel origin, but pancreatic involvement cannot be excluded as a possibility. Dilated pancreatic duct noted at 0.43 cm.

**SEX**

Neutered Male

**Free Abdomen**

No free fluid. There is a moderate mesenteric lymphadenopathy present with diffuse mesenteric lymph node enlargement in addition to some large focal lymph nodes. There is a cluster of lymph nodes measuring 0.61, 0.66, 0.58, and 0.48 cm. There are isolated lymph nodes measuring 1.26 cm x 1.83 cm. The omentum is of increased echogenicity around the mass effect, pancreas and lymph nodes.

**AGE**

6 Years

**WEIGHT**

3.5 kg

**PRIMARY FINDINGS**

- Large, ill-defined, hypoechoic mass lesion in the mid caudal abdomen – most likely bowel in origin.
- Large left kidney and small, shrunken right kidney – most consistent with previous damage to the right kidney and compensatory enlargement of the left kidney. This could represent the palpated mass effect as well.
- Hypoechoic, prominent pancreas with dilated pancreatic duct – The pancreatic changes are most consistent with mild/moderate pancreatitis/pancreatic inflammation. Recommend fPLI testing and continued monitoring for improvement or possible development of a pancreatic abscess. Consider fine needle aspirate if not improving.
- Moderate mesenteric lymphadenopathy – The moderate mesenteric lymphadenopathy is most concerning for a neoplastic process, although you can see significant lymphadenopathy in some cases of autoimmune/inflammatory disease, infectious disease (tick born disease-such as bartonella, fungal infections, FIP (cats)) etc. A fine needle aspirate with cytology is recommended for further evaluation.

**INTERPRETED BY**

Kathleen Sennello  
DVM, MS, Diplomate  
ACVIM (Small Animal  
Internal Medicine)

**IMAGING PERFORMED BY**

Crystal Hill

**HOSPITAL NAME**

Simcoe Animal Hospital

**REFERRING VET**

Dr. Aliaga-Leyton

**SECONDARY FINDINGS**

- Echogenic urine in the urinary bladder – The echogenic debris in the bladder lumen could be consistent with cells, crystals, and/or mucus.

**INTERPRETATION OF THE FINDINGS & FURTHER RECOMMENDATIONS**

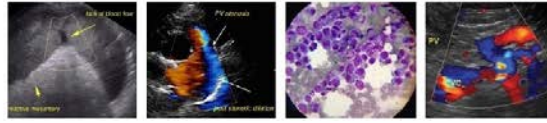
There is a large, ill-defined, hypoechoic mass effect in the abdomen that appears to be associated with the bowel, but is also in the region of the pancreas. Additionally, there is a significant lymphadenopathy present. Consider a fine needle aspirate of the abnormal tissue and one of the larger mesenteric lymph nodes to try to obtain more information, as there is high concern for a possible underlying neoplastic

**INVOICE**

33158

**DATE**

12/1/21



**PATIENT**

Gatsby Miller

process.

The left kidney is enlarged, and the right kidney is small. This is likely due to previous damage to the right kidney. It is possible that the mass effect you are palpating is either the enlarged left kidney, or the ill-defined mass effect reported.

**SPECIES**

Feline

You could consider a GI panel to Texas A&M for a quantitative fPLI, TLI, cobalamin and folate to further evaluate the pancreatic changes and to look for evidence of a chronic B12 deficiency, etc.

**BREED**

DSH

If aspirates are not successful in obtaining a diagnosis, recommend 3-view thoracic radiographs and referral to a veterinary surgeon for exploratory surgery, biopsies, and resection of a mass effect if possible.

**SEX**

Neutered Male

**AGE**

6 Years

**WEIGHT**

3.5 kg

**INTERPRETED BY**

Kathleen Sennello  
DVM, MS, Diplomate  
ACVIM (Small Animal  
Internal Medicine)

**IMAGING PERFORMED BY**

Crystal Hill

**HOSPITAL NAME**

Simcoe Animal Hospital

**REFERRING VET**

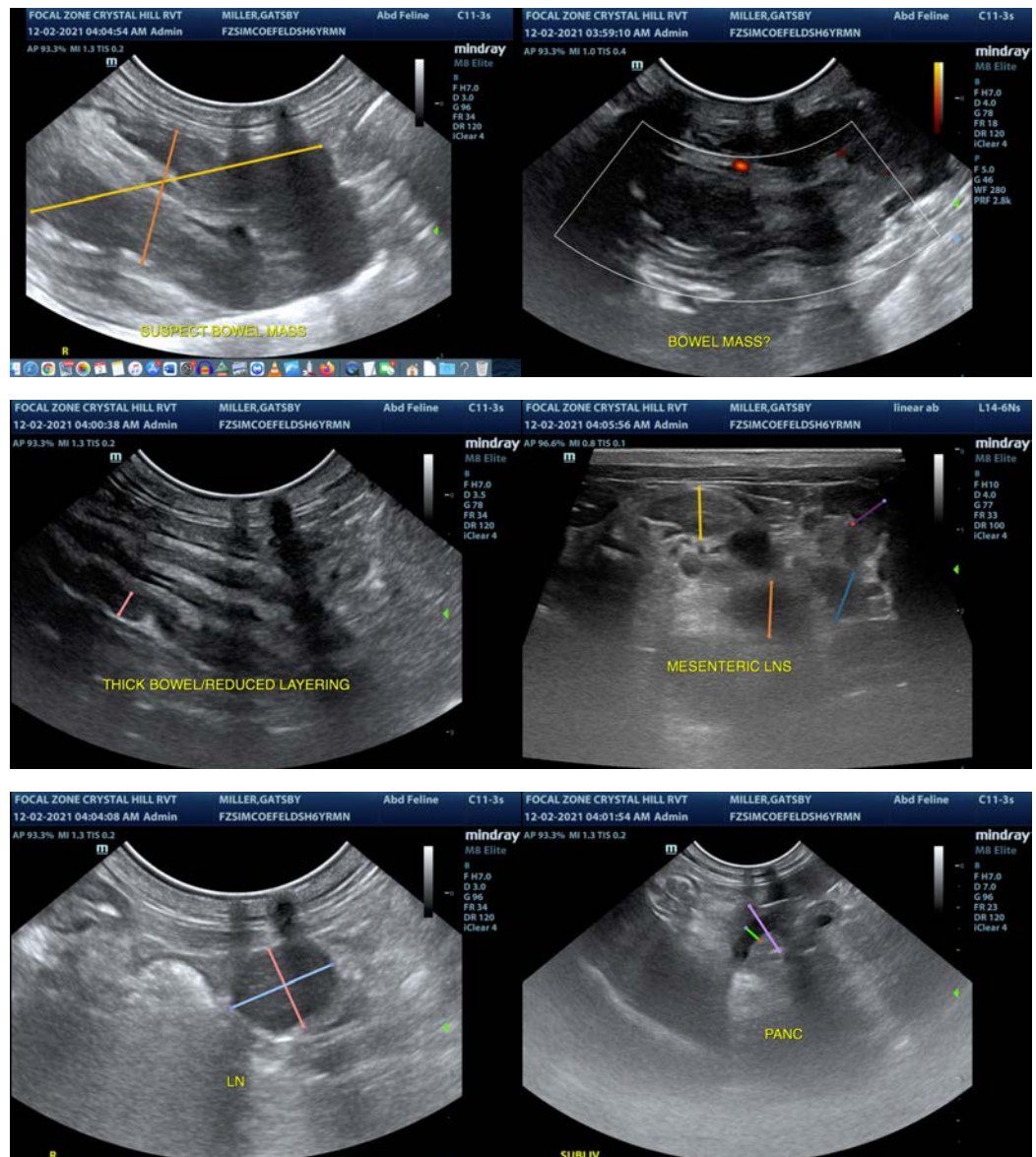
Dr. Aliaga-Leyton

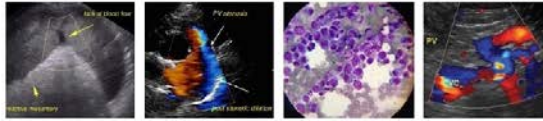
**INVOICE**

33158

**DATE**

12/1/21





**PATIENT**

Gatsby Miller

**SPECIES**

Feline

**BREED**

DSH

**SEX**

Neutered Male

**AGE**

6 Years

**WEIGHT**

3.5 kg

**INTERPRETED BY**

Kathleen Sennello  
DVM, MS, Diplomate  
ACVIM (Small Animal  
Internal Medicine)

**IMAGING  
PERFORMED BY**

Crystal Hill

**HOSPITAL NAME**

Simcoe Animal Hospital

**REFERRING VET**

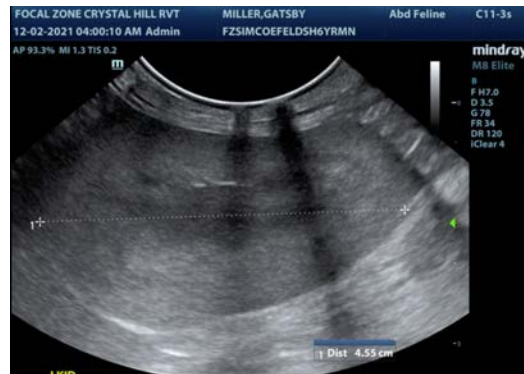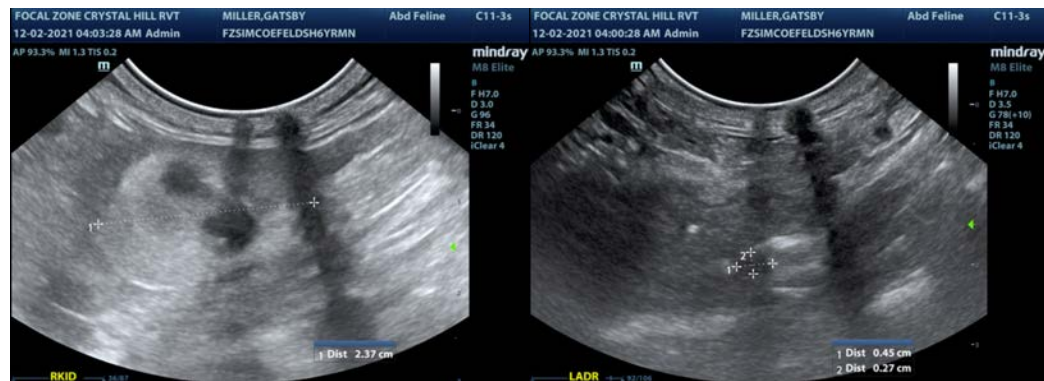
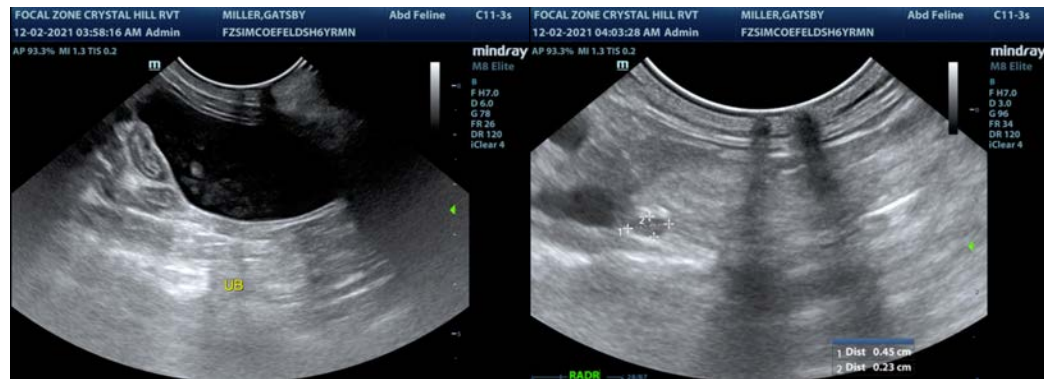
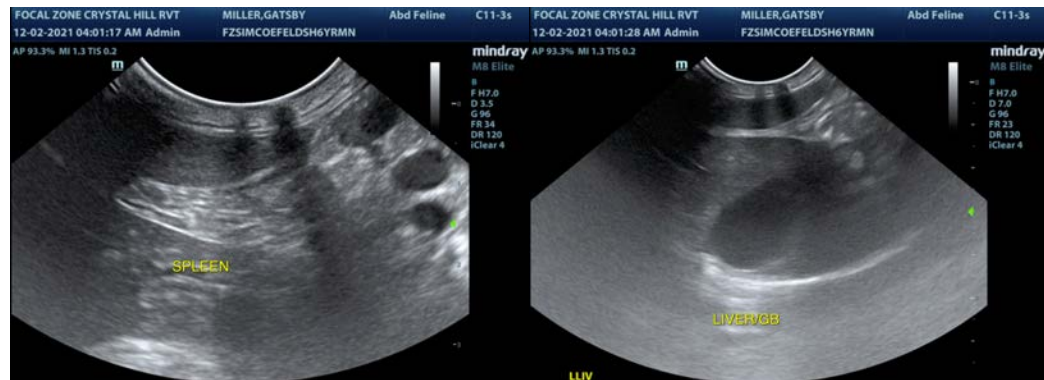
Dr. Aliaga-Leyton

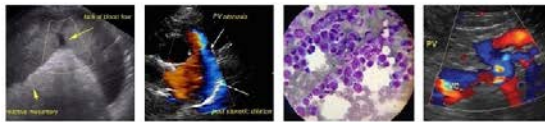
**INVOICE**

33158

**DATE**

12/1/21





**PATIENT**

Gatsby Miller

The information and recommendations provided are based on the images presented by the referring veterinarian. No evaluation can be communicated regarding pathology that was not visible in the image/video clips provided.

**SPECIES**

Feline

Thank you for this referral. If the clinical or image interpretation does not parallel your findings or if I can be of any further assistance please contact me.

Kathleen Sennello DVM,MS, Diplomate ACVIM (Small animal Internal Medicine)

kathleen.sennello@sonopath.com

**BREED**

DSH

**SEX**

Neutered Male

**AGE**

6 Years

**WEIGHT**

3.5 kg

**INTERPRETED BY**

Kathleen Sennello  
DVM, MS, Diplomate  
ACVIM (Small Animal  
Internal Medicine)

**IMAGING  
PERFORMED BY**

Crystal Hill

**HOSPITAL NAME**

Simcoe Animal Hospital

**REFERRING VET**

Dr. Aliaga-Leyton

**INVOICE**

33158

**DATE**

12/1/21