

**DATE PRESENTING CLINICAL SIGNS**

11/8/22

Was here this last weekend. Previous visit: About 1 month ago started with diarrhea then vomits then starts bland diet then better. Not eating anything for the last 2 days. Drank a lot last night then vomited right away. No frequent urination. Diarrhea yesterday with some mucous. Vetsulin bid, 11units. No insulin for 2 days since not eating. Checked BG last night and was 271. Not eaten since she's been home. No vomiting.

PATIENT

Bindi Barron

SPECIES

Canine

BREED

Miniature Schnauzer

SEX

Spayed Female

AGE

11/6/16

WEIGHT

22.5 Pounds

INTERPRETED BY

Kathleen Sennello DVM,
MS, Diplomate ACVIM
(Small Animal Internal
Medicine)

IMAGING PERFORMED BY

Rachel Brilhart RDMS

HOSPITAL NAME

Animal Emergency
Hospital

REFERRING VET

Dr. Ruby

INVOICE

42627

Current Medications: Buprenorphine, Insulin, Unasyn, Protonix, Cerenia.

Lab Results: See attached.

Radiographs: Diffuse loss of detail, no obvious fb.

Date of Previous IntraPet Ultrasound: No previous.

Sedation: Not required to complete full diagnostic ultrasound.

Stat Report: Not requested.

ULTRASONOGRAPHIC EXAMINATION OF THE ABDOMEN**Urinary System**

The urinary bladder is moderately distended with anechoic urine. The Bladder wall, trigone, ureteral papillae and visible urethra (to a depth of 2cm) appear normal with no evidence of wall thickening, mucosal irregularities, masses or cystic calculi.

The left kidney has a normal shape and size (6.25 cm) with mild pyelectasia at 0.22 cm. Overall echogenicity is normal with adequate corticomedullary distinction and a typical 1:3 cortex:medulla ratio. There is no evidence of focal perinephric inflammation or effusion. There is no evidence of nephroliths, infarcts or hydroureter. Renal vasculature is normal.

The right kidney has a normal shape and size (6.13 cm) with mild pyelectasia at 0.17 cm. Overall echogenicity is normal with adequate corticomedullary distinction and a typical 1:3 cortex:medulla ratio. There is no evidence of focal perinephric inflammation or effusion. There is no evidence of nephroliths, infarcts or hydroureter. Renal vasculature is normal.

Adrenal Glands

The left adrenal gland is normal in size measuring 0.62 cxm at the caudal pole. It is observed in its normal position cranial to the left renal artery. It is normal in appearance (uniformly hypoechoic) and shape with no evidence of a mass effect.

The right adrenal gland is normal in size measuring 0.47 cm at the caudal pole. It is observed in its normal position between the cranial aspect of the right kidney and the caudal vena cava. It is normal in appearance (uniformly hypoechoic) and shape with no evidence of a mass effect.

Spleen

The spleen is subjectively normal in size, echotexture is homogenous, and the splenic capsule is smooth with no irregularities. The blood flow through the hilus and splenic parenchyma appears normal. No focal parenchymal abnormalities are visualized.

Liver

The liver is large in size, and normal in echogenicity with smooth peripheral margins. The parenchyma is heterogenous in echotexture with subtle, indistinct focal mottling. The visible portions of the vasculature and biliary tract appear normal. No focal nodules or cystic lesions are observed.

The gall bladder lumen is moderately distended. The wall of the gall bladder is not thickened and has a smooth mucosal surface. There is a mild amount of non-organized echogenic debris. The cystic and common bile ducts are normal/not visible.

Gastrointestinal

The stomach contains minimal luminal contents. It measures at a normal thickness of <0.7cm with some variability due to the presence of rugal folds. The distinction of the gastric wall layers is adequate and there is no impression of reduced peristaltic activity. No masses or focal lesions were observed.

The visualized areas of duodenum, jejunum and ileum have a relatively uniform diameter with minimal fluid distension. Wall thickness is normal. Bowel loops follow a curvilinear path with distinct wall layering maintaining the typical 1:3 muscularis:mucosa layer ratio. Jejunum wall measures 0.30 cm. Visualized peristalsis appears appropriate. There were no focal lesions consistent with obstruction or a mass effect observed.

The ileocecal junction was visualized and exhibited normal intact wall layering and is subjectively of normal thickness. Sections of colon are visualized with formed fecal material and gas shadowing distally. There is no observed focal or generalized colon wall thickening or loss of layering.

Pancreas

The pancreas is large and hypoechoic to surrounding mesentery. There is no evidence of nodules or cystic lesions. There is evidence of regional mesenteric inflammation. Consistent with severe pancreatitis.

Free Abdomen

There is a small amount of free abdominal fluid. No lymphadenopathy. The omentum is hyperechoic, particularly around the abnormal pancreas.

ULTRASONOGRAPHIC FINDINGS

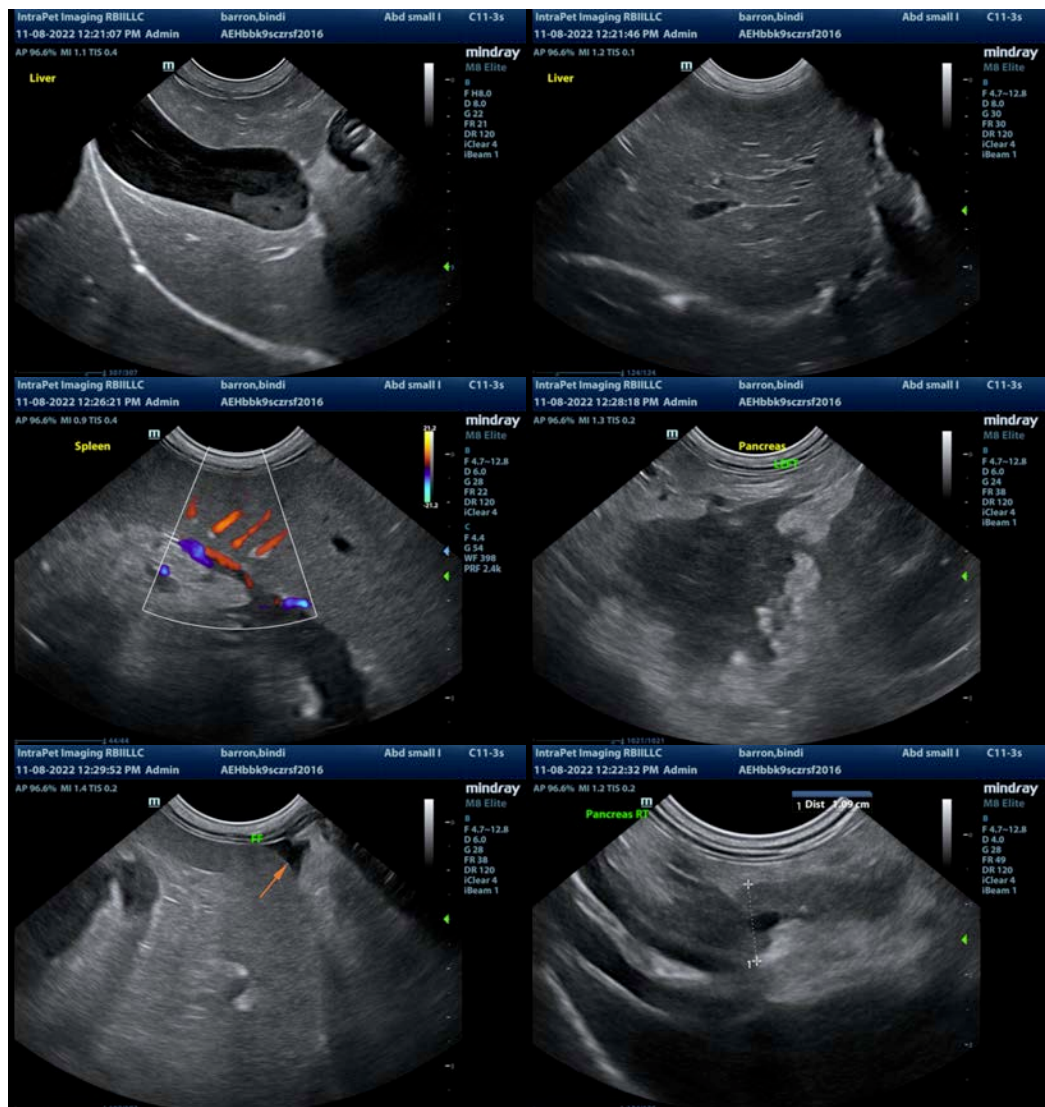
- Large, hypoechoic, irregular pancreas surrounded by hyperechoic mesentery and a small amount of fluid – The pancreatic changes are most consistent with severe pancreatitis/pancreatic inflammation. Recommend fPLI testing and continued monitoring for improvement or possible development of a pancreatic abscess. Consider fine needle aspirate if not improving.
- Mild bilateral renal pyelectasia – Pyelectasia of the kidney(s) could be consistent with pyelonephritis, chronic renal disease, secondary to PU/PD or fluid therapy (if applicable), other.
- Large, heterogeneous liver – The diffuse hepatic changes are non-specific and could be consistent with vacuolar hepatopathy, nodular hyperplasia, inflammatory/immune-mediated disease, fibrosis, extramedullary hematopoiesis, toxic hepatopathy (e.g., copper), infiltrative neoplasia (less likely) or other hepatopathy. This is likely consistent with a diabetic hepatopathy.
- Mild gallbladder debris – The significance of the aggregated gallbladder debris is unclear. This could represent an early mucocele, cholestasis, or may be secondary to fasting but seems unlikely to be causing a current issue. Recommend continued monitoring.
- Small volume abdominal effusion and severely hyperechoic mesentery surrounding the pancreas. Findings are most consistent with a focal sterile peritonitis.

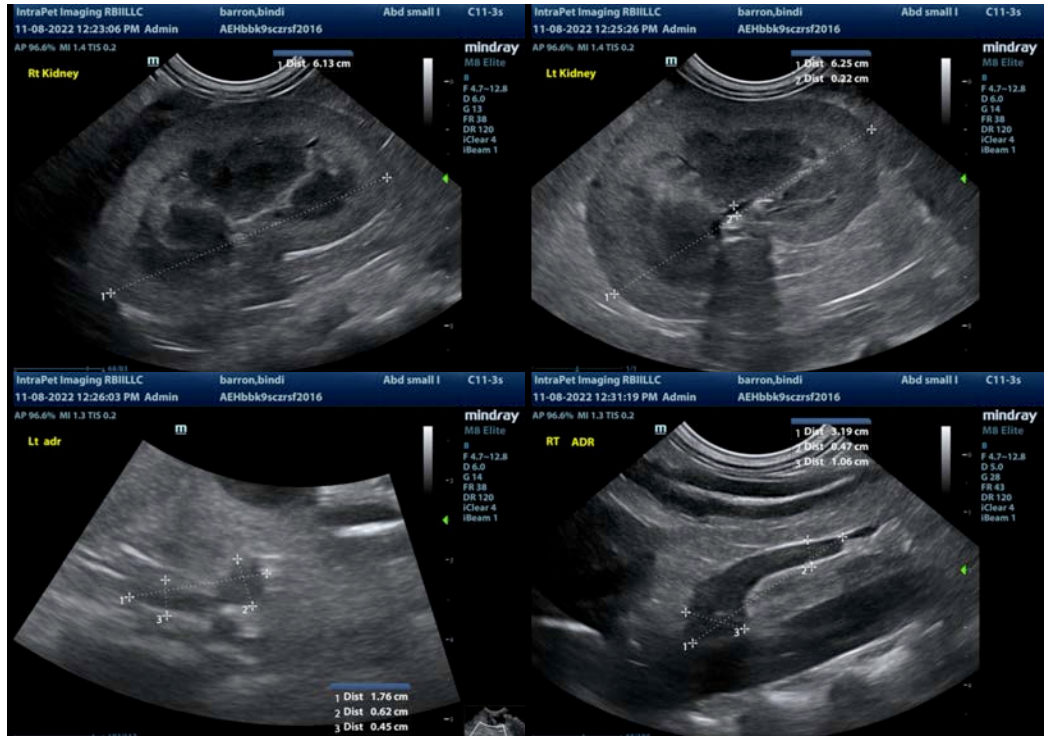
INTERPRETATION OF THE FINDINGS & FURTHER RECOMMENDATIONS

The pancreas appears severely inflamed and there is a small amount of free abdominal fluid. Findings are most consistent with pancreatitis and focal sterile peritonitis. Recommend aggressive therapy for pancreatitis while supporting the diabetes with injectable insulin. Recommend urinalysis and culture and checking for ketones.

The bilirubin is elevated in the lab work provided. The gallbladder does not appear overtly obstructed, but continued monitoring is warranted. If the patient is not starting to improve in 2-3 days, recommend repeat ultrasound to look for development of a pancreatic abscess, etc.

Recommend three view thoracic radiographs to evaluate for possible concurrent thoracic disease/involvement.





The information and recommendations provided are based on the images presented by the referring veterinarian/sonographer. No evaluation can be communicated regarding pathology that was not visible in the image/video clips provided.

Thank you for this referral. If the clinical or image interpretation does not parallel your findings or if I can be of any further assistance please contact me.

Kathleen Sennello DVM,MS, Diplomate ACVIM (Small animal Internal Medicine)
 kathleen.sennello@sonopath.com