

**DATE PRESENTING CLINICAL SIGNS**

11/8/22

Mild anemia, elevated liver enzymes, weight loss. Normal labs documented as recently as May 2022. Had episode of GI upset 10/9, seen at AAVEC, treated supportively and signs resolved. At that visit had elevated liver enzymes and mild non or pre-regenerative anemia. Recheck 10/22 at rDVM doing clinically well, liver enzymes static to progressive, elevated BUN w/normal creat, improved anemia. Also, history of generalized demodex treated w/topical therapy.

**PATIENT**

Billy Yates

**SPECIES**

Canine

**BREED**

Beagle

**SEX**

Neutered Male

**AGE**

6/14/09

**WEIGHT**

10.8 kg

**INTERPRETED BY**

Kathleen Sennello DVM,  
MS, Diplomate ACVIM  
(Small Animal Internal  
Medicine)

**IMAGING PERFORMED BY**

Andi Parkinson RDMS

**HOSPITAL NAME**

Nexus Vet Specialists

**REFERRING VET**

Dr. Steele

**INVOICE**

42612

Current Medications: Prednisone 1.5mg daily, DOCP 0.9mL once monthly, Advantage multi weekly, Weekly baths Biohex shampoo

Anti-itch supplement (started a couple of months ago), Fortiflora once daily, Cosequin w/MSM

Lab Results: 10/9--ALT 330, ALP 261, GGT 12. HCT 31% (norm/norm/non or pre-regen). 10/22--PCV/TS 35% and 7.5, HCT 36% (norm/norm, no retic count but retics later returned normal reportedly), ALP 398, ALT 295, BUN 28 w/normal creat and SDMA, GGT 18.

Date of Previous IntraPet Ultrasound: No previous.

Sedation: Not required to complete full diagnostic ultrasound.

Stat Report: Not requested.

**ULTRASONOGRAPHIC EXAMINATION OF THE ABDOMEN****Urinary System**

The urinary bladder is moderately distended with anechoic urine. The Bladder wall, trigone, ureteral papillae and visible urethra (to a depth of 2cm) appear normal with no evidence of wall thickening, mucosal irregularities, masses or cystic calculi.

The visualized areas of prostate and surrounding tissue appear normal. Unfortunately, the prostate is not fully visualized likely due to its intrapelvic location. Correlate with rectal exam findings.

The left kidney has a normal shape and size (5.87 cm). Overall echogenicity is normal with adequate corticomedullary distinction and a typical 1:3 cortex:medulla ratio. There is no evidence of focal perinephric inflammation or effusion. There is no evidence of pyelectasia, nephroliths, infarcts or hydroureter. Renal vasculature is normal.

The right kidney has a normal shape and size (5.69 cm). Overall echogenicity is normal with adequate corticomedullary distinction and a typical 1:3 cortex:medulla ratio. There is no evidence of focal perinephric inflammation or effusion. There is no evidence of pyelectasia, nephroliths, infarcts or hydroureter. Renal vasculature is normal.

**Adrenal Glands**

The left adrenal gland is small in size measuring 0.30 cm at the caudal pole. It is observed in its normal position cranial to the left renal artery. It is normal in appearance (uniformly hypoechoic) and shape with no evidence of a mass effect.

The right adrenal gland is normal/borderline small in size measuring 0.43 cm at the caudal pole. It is observed in its normal position between the cranial aspect of the right kidney and the caudal vena cava. It is normal in appearance (uniformly hypoechoic) and shape with no evidence of a mass effect.

**Spleen**

The spleen is subjectively normal in size, echotexture is homogenous, and the splenic capsule is smooth with no irregularities. The blood flow through the hilus and splenic parenchyma appears normal. No focal parenchymal abnormalities are visualized.

### ***Liver***

The liver is large and irregular. The parenchyma is heterogenous in echotexture with subtle, indistinct focal mottling. The visible portions of the vasculature and biliary tract appear normal. There is a large, solid, hyperechoic, somewhat lobulated mass effect visualized in the liver measuring approximately 7.26 cm x 6.39 cm.

The gall bladder lumen is moderately distended. The wall of the gall bladder is not thickened and has a smooth mucosal surface. There is a moderate amount of non-organized echogenic debris. The cystic and common bile ducts are normal/not visible.

### ***Gastrointestinal***

The stomach contains minimal luminal contents. It measures at a normal thickness of <0.7cm with some variability due to the presence of rugal folds. The distinction of the gastric wall layers is adequate and there is no impression of reduced peristaltic activity. No masses or focal lesions were observed.

The visualized areas of duodenum, jejunum and ileum have a relatively uniform diameter with minimal fluid distension. Wall thickness is normal. Bowel loops follow a curvilinear path with distinct wall layering maintaining the typical 1:3 muscularis:mucosa layer ratio. The duodenum measured as normal (between 0.3-0.5cm in wall thickness) and the jejunum measured as normal (between 0.2-0.47cm.) Visualized peristalsis appears appropriate. There were no focal lesions consistent with obstruction or a mass effect observed.

The ileocecal junction was visualized and exhibited normal intact wall layering and is subjectively of normal thickness. Sections of colon are visualized with formed fecal material and gas shadowing distally. There is no observed focal or generalized colon wall thickening or loss of layering.

### ***Pancreas***

The pancreas is normal and isoechoic to surrounding mesentery. There is no evidence of nodules or cystic lesions. There is no evidence of regional mesenteric inflammation or fluid.

### ***Free Abdomen***

Evaluation of the peritoneal cavity did not reveal any evidence of effusion, or subjective lymphadenomegaly. The Medial iliac nodes appear normal and there was no evidence of a caudal aortic thrombus at the bifurcation. The omentum is of normal uniform echogenicity.

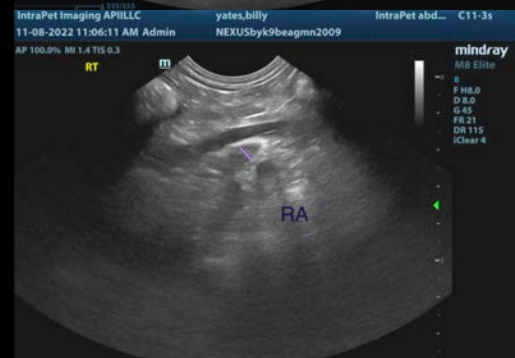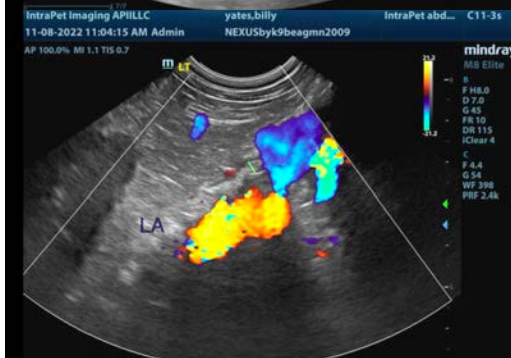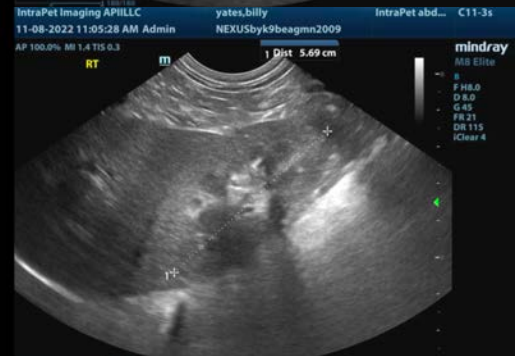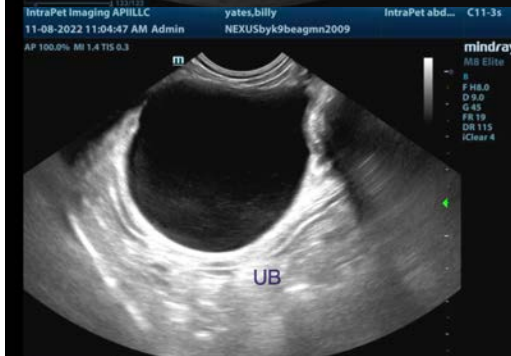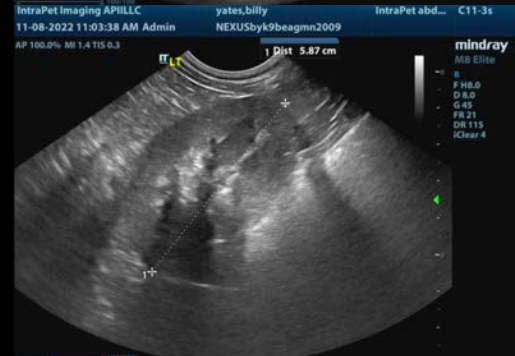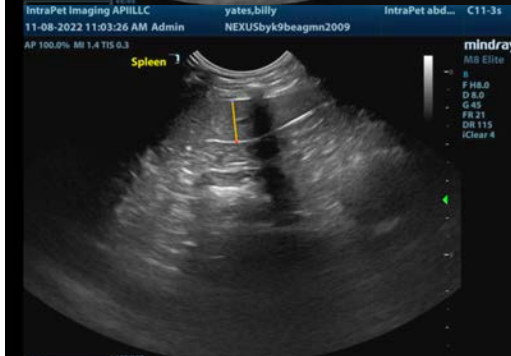
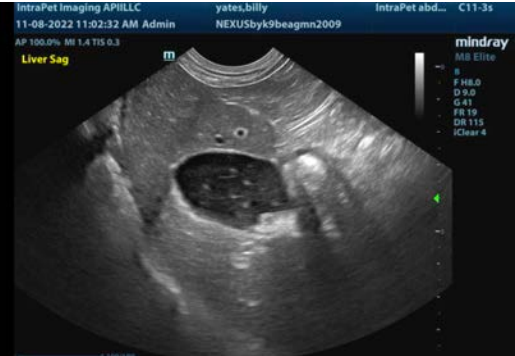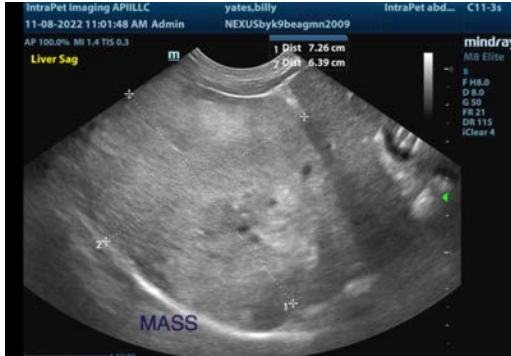
## **ULTRASONOGRAPHIC FINDINGS**

- Heterogeneous liver with large, hyperechoic, irregular, solid mass effect – Findings are most consistent with a primary hepatic mass (carcinoma, adenoma, etc.), although other differentials are possible.
- Moderate gallbladder debris – The significance of the aggregated gallbladder debris is unclear. This could represent an early mucocele, cholestasis, or may be secondary to fasting but seems unlikely to be causing a current issue. Recommend continued monitoring.

## **INTERPRETATION OF THE FINDINGS & FURTHER RECOMMENDATIONS**

Significant ultrasonographic findings include a large hepatic mass and small adrenals.

Further diagnostic and therapeutic recommendations regarding this exam to be made by Dr. Cara Steele.



**The information and recommendations provided are based on the images presented by the referring veterinarian/sonographer. No evaluation can be communicated regarding pathology that was not visible in the image/video clips provided.**

Thank you for this referral. If the clinical or image interpretation does not parallel your findings or if I can be of any further assistance please contact me.

Kathleen Sennello DVM,MS, Diplomate ACVIM (Small animal Internal Medicine)  
kathleen.sennello@sonopath.com