



PATIENT

Tucker Gelhar

SPECIES

Canine

BREED

Poodle x

SEX

Neutered Male

AGE

6 Years

WEIGHT

90.8 lbs

INTERPRETED BY

Kathleen Sennello DVM,
MS, Diplomate ACVIM
(Small Animal Internal
Medicine)

IMAGING PERFORMED BY

Christina, CVT

HOSPITAL NAME

Animal Health
Veterinary Clinic

REFERRING VET

Dr. Readdy

INVOICE

71619

DATE

11/6/25

PRESENTING CLINICAL SIGNS

Abdominal ultrasound for P that had a large SQ Hemangiosarcoma removed 2 months ago (completely excised) - P is going to Blue Pearl for Oncology consult, 3 view chest rads done today (one area to monitor on chest rads) - E/D normal, No V/D/C/S - Full Bloodwork on 10/31/25 all WNL -

Abnormal PE/Chem/CBC/UA Results: Superchem, CBC, T4, UA all WNL on 10/31/25

ULTRASONOGRAPHIC EXAMINATION OF THE ABDOMEN

Urinary System

The urinary bladder is moderately distended with anechoic urine. The Bladder wall, trigone, ureteral papillae and visible urethra (to a depth of 2cm) appear normal with no evidence of wall thickening, mucosal irregularities, masses or cystic calculi.

The visualized areas of prostate and surrounding tissue appear normal. Unfortunately, the prostate is not fully visualized likely due to its intrapelvic location. Correlate with rectal exam findings.

The left kidney has a normal shape and size (6.64 cm). Overall echogenicity is normal with adequate corticomedullary distinction and a typical 1:3 cortex:medulla ratio. There is no evidence of focal perinephric inflammation or effusion. There is no evidence of pyelectasia, nephroliths, infarcts or hydroureter. Renal vasculature is normal.

The right kidney has a normal shape and size (7.12 cm). Overall echogenicity is normal with adequate corticomedullary distinction and a typical 1:3 cortex:medulla ratio. There is no evidence of focal perinephric inflammation or effusion. There is no evidence of pyelectasia, nephroliths, infarcts or hydroureter. Renal vasculature is normal.

Adrenal Glands

The region of left adrenal (Cranial to left renal artery) is unremarkable but the adrenal is not distinctly visualized. No evidence of a mass effect is visualized.

The region of the right adrenal (between right cranial kidney and vena cava) is unremarkable, but the adrenal is not distinctly visualized. No evidence of a mass effect is visualized.

Spleen

The spleen is subjectively normal in size (1.67 cm in width at the level of the hilus). The spleen echotexture is heterogenous and mottled, the splenic capsule is smooth with no irregularities. The blood flow through the hilus and splenic parenchyma appears normal. There is a poorly defined hypoechoic nodule in the mid caudal region of the spleen measuring 0.77 cm x 0.69 cm. There is a 2nd hypoechoic nodule visualized in the cranial aspect of the spleen measuring 0.96 cm. Other occasional ill-defined hypoechoic nodules are observed.

Liver

The liver is subjectively normal in size, and echogenicity with smooth peripheral margins. The parenchyma is mildly heterogenous in echotexture with subtle, indistinct focal mottling. The visible portions of the vasculature and biliary tract appear normal. No focal nodules or cystic lesions are observed.



PATIENT

Tucker Gelhar

The gall bladder lumen is moderately distended. The wall of the gall bladder is not thickened and has a smooth mucosal surface. Luminal contents are mild and likely incidental at this time. The cystic and common bile ducts are normal/not visible.

SPECIES

Canine

Gastrointestinal

The stomach contains moderate shadowing ingesta. It measures at a normal thickness of <0.7cm with some variability due to the presence of rugal folds. The distinction of the gastric wall layers is adequate and there is no impression of reduced peristaltic activity. Shadowing ingesta interferes with full evaluation of the stomach and some areas of the cranial abdomen.

BREED

Poodle x

The visualized areas of duodenum, jejunum and ileum have a relatively uniform diameter with minimal fluid distension. Wall thickness is normal. Bowel loops follow a curvilinear path with distinct wall layering maintaining the typical 1:3 muscularis:mucosa layer ratio. The duodenum measured as normal (between 0.3-0.5cm in wall thickness) and the jejunum measured as normal (between 0.2-0.47cm.) Visualized peristalsis appears appropriate. There were no focal lesions consistent with obstruction or a mass effect observed.

SEX

Neutered Male

AGE

6 Years

Sections of colon are visualized with formed fecal material and gas shadowing distally. There is no observed focal or generalized colon wall thickening or loss of layering.

WEIGHT

90.8 lbs

Pancreas

The area of the pancreas is normal and isoechoic to surrounding mesentery. There is no evidence of nodules or cystic lesions. There is no evidence of regional mesenteric inflammation or fluid.

INTERPRETED BY

Kathleen Sennello DVM,
MS, Diplomate ACVIM
(Small Animal Internal
Medicine)

Free Abdomen

Evaluation of the peritoneal cavity did not reveal any evidence of effusion. There is no evidence of a diffuse lymphadenopathy. Dorsal to the stomach there is a poorly visualized hypoechoic structure measuring 2.0 cm x 3.5 cm, possibly consistent with a portal lymph node.

IMAGING PERFORMED BY

Christina, CVT

Other

There is a hypoechoic ventral cranial mass effect visualized measuring 3.53 cm x 6.68 cm, suggestive of a lipoma or falciform fat.

HOSPITAL NAME

Animal Health
Veterinary Clinic

ULTRASONOGRAPHIC FINDINGS

- Mottled spleen with occasional ill-defined hypoechoic nodules – There are several, non-cavitated, hypoechoic splenic nodules visualized. Differentials include lymphoid hyperplasia, extramedullary hematopoiesis, infiltrative neoplasia, inflammation, other. Cytology or histopathology would be necessary to get a definitive diagnosis.
- Mildly heterogeneous liver – The diffuse hepatic changes are non-specific and could be consistent with vacuolar hepatopathy, nodular hyperplasia, inflammatory/immune-mediated disease, fibrosis, extramedullary hematopoiesis, toxic hepatopathy (e.g., copper), infiltrative neoplasia (less likely) or other hepatopathy.
- Cranial ventral mass effect suggestive of a lipoma – Recommend a fine needle aspirate to confirm.

REFERRING VET

Dr. Readdy

INVOICE

71619

DATE

11/6/25



PATIENT

Tucker Gelhar

SPECIES

Canine

BREED

Poodle x

SEX

Neutered Male

AGE

6 Years

WEIGHT

90.8 lbs

INTERPRETED BY

Kathleen Sennello DVM,
MS, Diplomate ACVIM
(Small Animal Internal
Medicine)

**IMAGING
PERFORMED BY**

Christina, CVT

HOSPITAL NAME

Animal Health
Veterinary Clinic

REFERRING VET

Dr. Readdy

INVOICE

71619

DATE

11/6/25

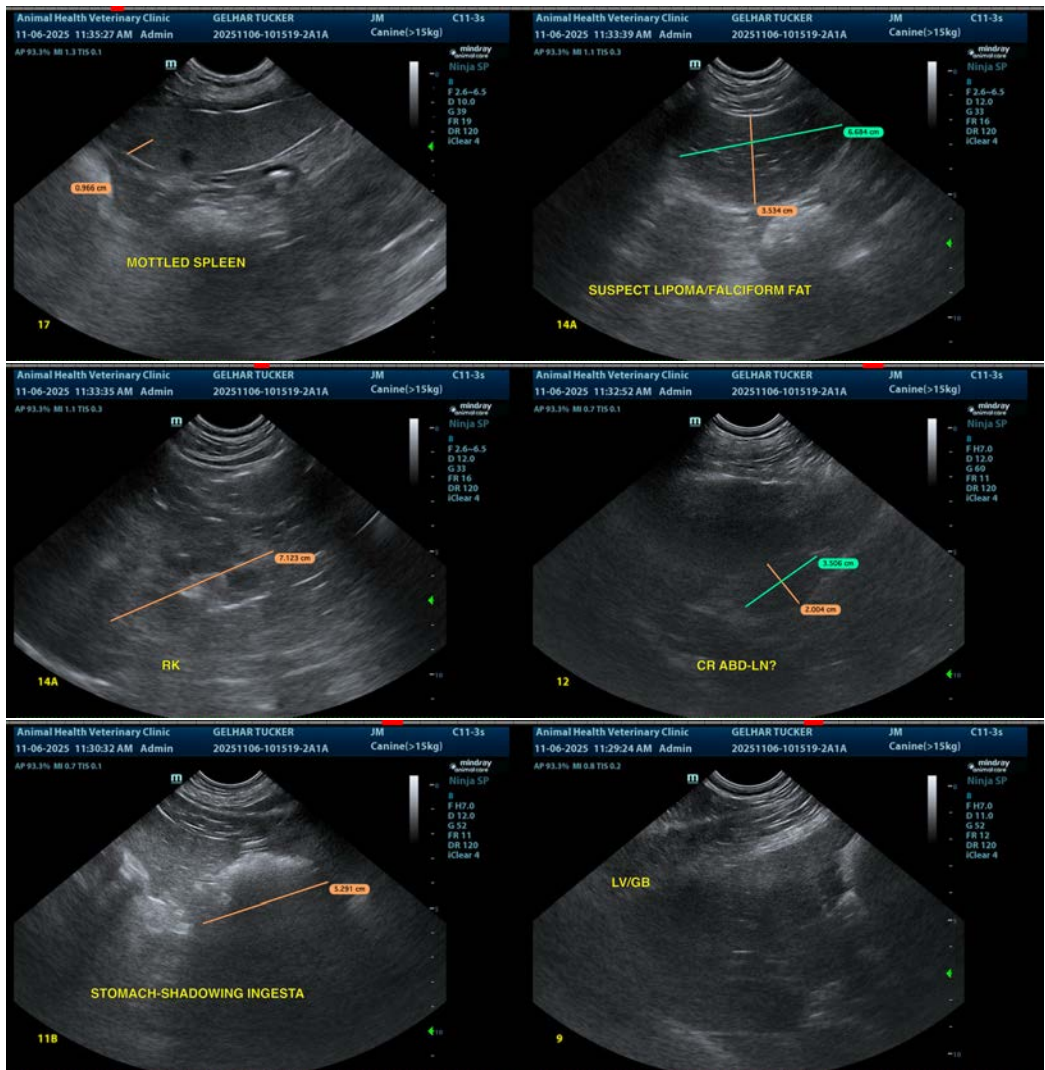
- Hypochoic cranial abdominal structure – Findings could be consistent with a highly reactive or metastatic lymph nodes.

INTERPRETATION OF THE FINDINGS & FURTHER RECOMMENDATIONS

The spleen appears diffusely mottled with occasional ill-defined hypochoic nodules. This could represent a benign lesion, but given the history of hemangiosarcoma, metastatic disease is a significant concern. Recommend a fine needle aspirate of the spleen/splenic nodules.

There is a hypochoic, homogeneous mass effect in the cranioventral abdomen with the appearance most consistent with fat/a lipoma. Recommend a fine needle aspirate of this lesion to confirm.

There is a poorly visualized hypochoic structure visualized dorsal to the stomach. This could be consistent with a portal lymph node. This is likely too deep to easily sample. Recommend continued monitoring.





PATIENT

Tucker Gelhar

SPECIES

Canine

BREED

Poodle x

SEX

Neutered Male

AGE

6 Years

WEIGHT

90.8 lbs

INTERPRETED BY

Kathleen Sennello DVM,
MS, Diplomate ACVIM
(Small Animal Internal
Medicine)

**IMAGING
PERFORMED BY**

Christina, CVT

HOSPITAL NAME

Animal Health
Veterinary Clinic

REFERRING VET

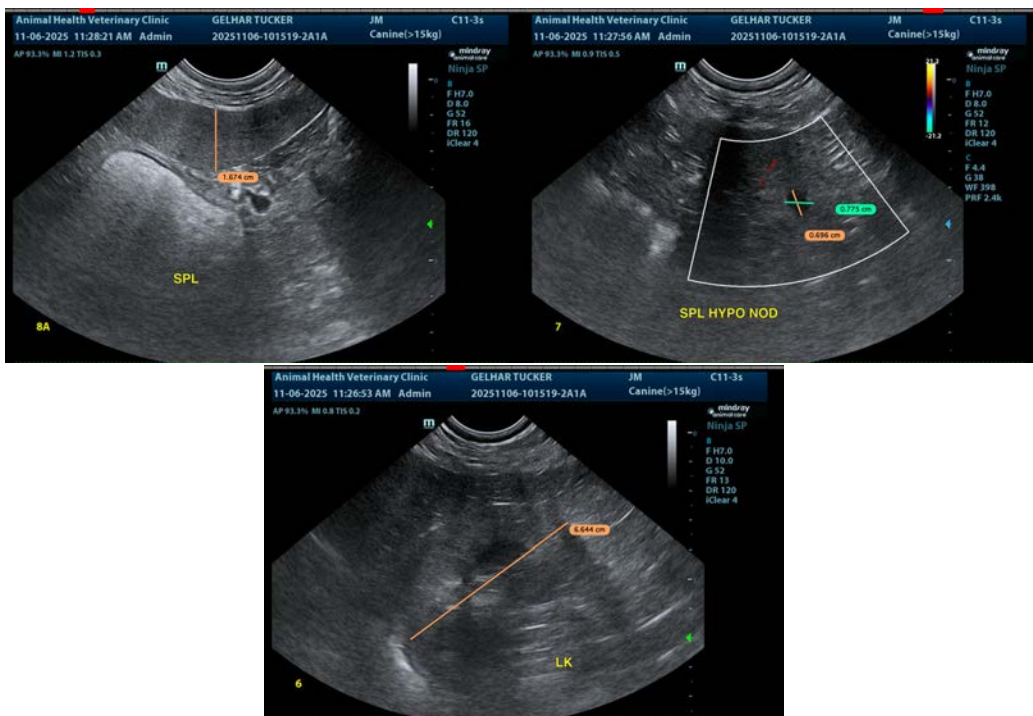
Dr. Readdy

INVOICE

71619

DATE

11/6/25



The information and recommendations provided are based on the images presented by the referring veterinarian/sonographer. No evaluation can be communicated regarding pathology that was not visible in the image/video clips provided.

Thank you for this referral. If the clinical or image interpretation does not parallel your findings or if I can be of any further assistance please contact me.

Kathleen Sennello DVM,MS, Diplomate ACVIM (Small animal Internal Medicine)

info@sonopath.com