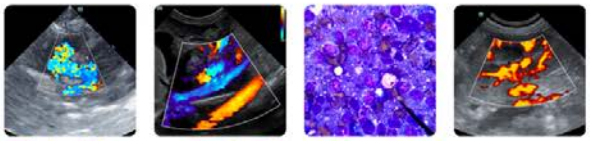

PATIENT
Coco Lye

SPECIES
Canine

BREED
Mixed

SEX
Spayed Female

AGE
16 Years

WEIGHT
22 lbs

INTERPRETED BY
Kathleen Sennello DVM, MS, Diplomate ACVIM (Small Animal Internal Medicine)

IMAGING PERFORMED BY
Julia Bakker, DVM

HOSPITAL NAME
Orange Blossom VI

REFERRING VET
Kristen Hillard, DVM

INVOICE
71641

DATE
11/6/25

PRESENTING CLINICAL SIGNS

Elevated ALT and ALP, anorexia, vomiting, diarrhea (which has resolved), mild lethargy Rads (abd): hepatomegaly, splenomegaly, liver has areas with rounded edges and possible mass, spondylosis in multiple areas of back, arthritis in stifles and elbows FNA of cranial abdominal lymph nodes taken today, cytology pending

ULTRASONOGRAPHIC EXAMINATION OF THE ABDOMEN

Urinary System

The urinary bladder is moderately distended with anechoic urine. The Bladder wall, trigone, ureteral papillae and visible urethra (to a depth of 2cm) appear normal with no evidence of wall thickening, mucosal irregularities, masses or cystic calculi.

The left kidney has a normal shape and size (4.72 cm) with irregular margins. Overall echogenicity is slightly hyperechoic with poor corticomedullary distinction and a typical 1:3 cortex:medulla ratio. There is no evidence of focal perinephric inflammation or effusion. There is no evidence of pyelectasia, nephroliths, infarcts or hydroureter. Renal vasculature is normal.

The right kidney has a normal shape and size (4.45 cm) with irregular margins. Overall echogenicity is slightly hyperechoic with poor corticomedullary distinction and a typical 1:3 cortex:medulla ratio. There is no evidence of focal perinephric inflammation or effusion. There is no evidence of pyelectasia, nephroliths, infarcts or hydroureter. Renal vasculature is normal.

Adrenal Glands

The left adrenal gland is borderline “plump”, measuring 0.58 cm at the cranial pole and 0.64 cm at the caudal pole. It is observed in its normal position cranial to the left renal artery. It is normal in appearance (uniformly hypoechoic) and shape with no evidence of a mass effect.

The right adrenal gland is borderline “plump”, measuring 0.87 cm at the cranial pole and 0.73 cm at the caudal pole. It is observed in its normal position between the cranial aspect of the right kidney and the caudal vena cava. It is normal in appearance (uniformly hypoechoic) and shape with no evidence of a mass effect.

Spleen

The spleen is subjectively large in size (2.09 cm in width at the level of the hilus), rounded, and mottled. The blood flow through the hilus and splenic parenchyma appears normal. There is a subtle hypoechoic nodule visualized near the hilus measuring 1.1 cm x 0.82 cm.

Liver

The liver is large in size, and normal in echogenicity with rounded margins. The parenchyma is heterogenous in echotexture with subtle, indistinct focal mottling. The visible portions of the vasculature and biliary tract appear normal. No focal nodules or cystic lesions are observed.

The gall bladder lumen is moderately distended. The wall of the gall bladder is not thickened and has a smooth mucosal surface. There is a moderate amount of non-organized echogenic debris. The cystic and common bile ducts are normal/not visible.



PATIENT
Coco Lye

SPECIES
Canine

BREED
Mixed

SEX
Spayed Female

AGE
16 Years

WEIGHT
22 lbs

INTERPRETED BY
Kathleen Sennello DVM, MS, Diplomate ACVIM (Small Animal Internal Medicine)

IMAGING PERFORMED BY
Julia Bakker, DVM

HOSPITAL NAME
Orange Blossom VI

REFERRING VET
Kristen Hillard, DVM

INVOICE
71641

DATE
11/6/25

Gastrointestinal

The stomach contains moderate/large fluid. It measures at a normal thickness of <0.7cm with some variability due to the presence of rugal folds. The distinction of the gastric wall layers is adequate and there is no impression of reduced peristaltic activity. No masses or focal lesions were observed.

The visualized areas of duodenum, jejunum and ileum have a relatively uniform diameter with minimal fluid distension. Wall thickness is normal. Bowel loops follow a curvilinear path with distinct wall layering maintaining the typical 1:3 muscularis:mucosa layer ratio. Jejunum wall measures 0.31 cm. Visualized peristalsis appears appropriate. There were no focal lesions consistent with obstruction or a mass effect observed.

Sections of colon are visualized with formed fecal material and gas shadowing distally. There is no observed focal or generalized colon wall thickening or loss of layering.

Pancreas

The pancreas is large, prominent and mottled in both limbs. In the right limb there is an isoechoic, slightly cystic mass effect visualized measuring 1.82 cm x 1.54 cm. This could represent a pancreatic mass lesion or an enlarged lymph node in the region. There is no evidence of regional mesenteric inflammation or fluid.

Free Abdomen

Evaluation of the peritoneal cavity did not reveal any evidence of effusion. There is a diffuse mesenteric lymphadenopathy with large, hypoechoic, rounded lymph nodes. Medial to the spleen there is a cluster with lymph nodes measuring 0.79 cm x 3.02 cm and 1.44 cm x 1.47 cm. In the right abdomen there are hypoechoic rounded lymph nodes measuring 1.54 cm x 1.54 cm and 1.44 cm x 1.34 cm. The omentum is diffusely hyperechoic.

PRIMARY FINDINGS

- Borderline “plump” adrenal glands – Findings could represent anatomic variation or early hyperplasia.
- Subjectively large, mottled spleen with an ill-defined hypoechoic nodule – The diffuse splenic changes are non-specific and could be consistent with lymphoid hyperplasia, extramedullary hematopoiesis, infiltrative neoplasia, inflammation, other. Cytology or histopathology would be necessary to get a definitive diagnosis.
- Pancreatic changes most consistent with chronic pancreatic remodeling +/- mild chronic pancreatitis. There is a questionable isoechoic mass effect in the right cranial aspect of the pancreas.
- Large, heterogeneous liver – The diffuse hepatic changes are non-specific and could be consistent with vacuolar hepatopathy, nodular hyperplasia, inflammatory/immune-mediated disease, fibrosis, extramedullary hematopoiesis, toxic hepatopathy (e.g., copper), infiltrative neoplasia (less likely) or other hepatopathy.

PATIENT
Coco Lye

SPECIES
Canine

BREED
Mixed

SEX
Spayed Female

AGE
16 Years

WEIGHT
22 lbs

INTERPRETED BY
Kathleen Sennello DVM, MS, Diplomate ACVIM (Small Animal Internal Medicine)

IMAGING PERFORMED BY
Julia Bakker, DVM

HOSPITAL NAME
Orange Blossom VI

REFERRING VET
Kristen Hillard, DVM

INVOICE
71641

DATE
11/6/25

- Moderate diffuse mesenteric lymphadenopathy – The moderate mesenteric lymphadenopathy could be concerning for a neoplastic process, although you can see significant lymphadenopathy in some cases of autoimmune/inflammatory disease, infectious disease(tick born disease-such as bartonella, fungal infections, etc. A fine needle aspirate with cytology is recommended for further evaluation.

SECONDARY FINDINGS

- Age related changes visualized associated with both kidneys.
- Moderate gallbladder debris – The significance of the aggregated gallbladder debris is unclear. This could represent an early mucocele, cholestasis, or may be secondary to fasting but seems unlikely to be causing a current issue. Recommend continued monitoring.
- Large, fluid distended stomach – Correlate with feeding history. If the patient was adequately fasted, this could represent delayed gastric emptying/less likely a pyloric outflow tract obstruction (none clearly visualized).

INTERPRETATION OF THE FINDINGS & FURTHER RECOMMENDATIONS

There is enlargement of the liver, spleen and pancreas on today's exam. These findings could be secondary to congestion, neoplastic infiltration, a primary hepatopathy (possibly vacuolar). Recommend a fine needle aspirate of both the liver and spleen.

Additionally, there is a significant lymphadenopathy present. The lymph nodes are moderately enlarged, but rounded and hypoechoic. Recommend a fine needle aspirate of an enlarged mesenteric lymph node as well.

The pancreas appears large and somewhat mottled but not overtly inflamed. In the cranial abdomen there is a more isoechoic appearing mass effect visualized in the cranial abdomen adjacent to the pancreas, which is concerning for possible pancreatic mass lesion, but an overlapping lymph node cannot be ruled out. If a safe window for sampling is available, consider a fine needle aspirate. Otherwise, consider continued monitoring/reevaluation in 6-8 weeks to see if this lesion is changing.

There is a moderate amount of debris visualized in the gallbladder, and some of the debris is adhered to the gallbladder wall. Consider chronic Ursodiol therapy and continued monitoring of the gallbladder for progression to a mucocele.

Recommend three view thoracic radiographs to evaluate for possible concurrent thoracic disease/involvement (disregard if this has already been done).

SonoPath

FOSTERING THE ART OF VETERINARY MEDICINE™

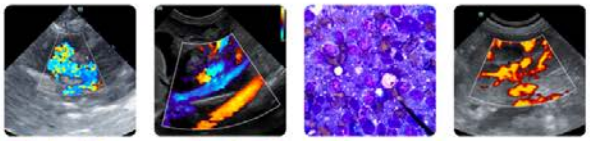

Clinical Sonography & Telecytology

Educational Teleconsultation Services™

SonoPath.com info@sonopath.com 1.800.838.4268

PATIENT

Coco Lye

SPECIES

Canine

BREED

Mixed

SEX

Spayed Female

AGE

16 Years

WEIGHT

22 lbs

INTERPRETED BY

Kathleen Sennello DVM, MS, Diplomate ACVIM (Small Animal Internal Medicine)

IMAGING PERFORMED BY

Julia Bakker, DVM

HOSPITAL NAME

Orange Blossom VI

REFERRING VET

Kristen Hillard, DVM

INVOICE

71641

DATE

11/6/25

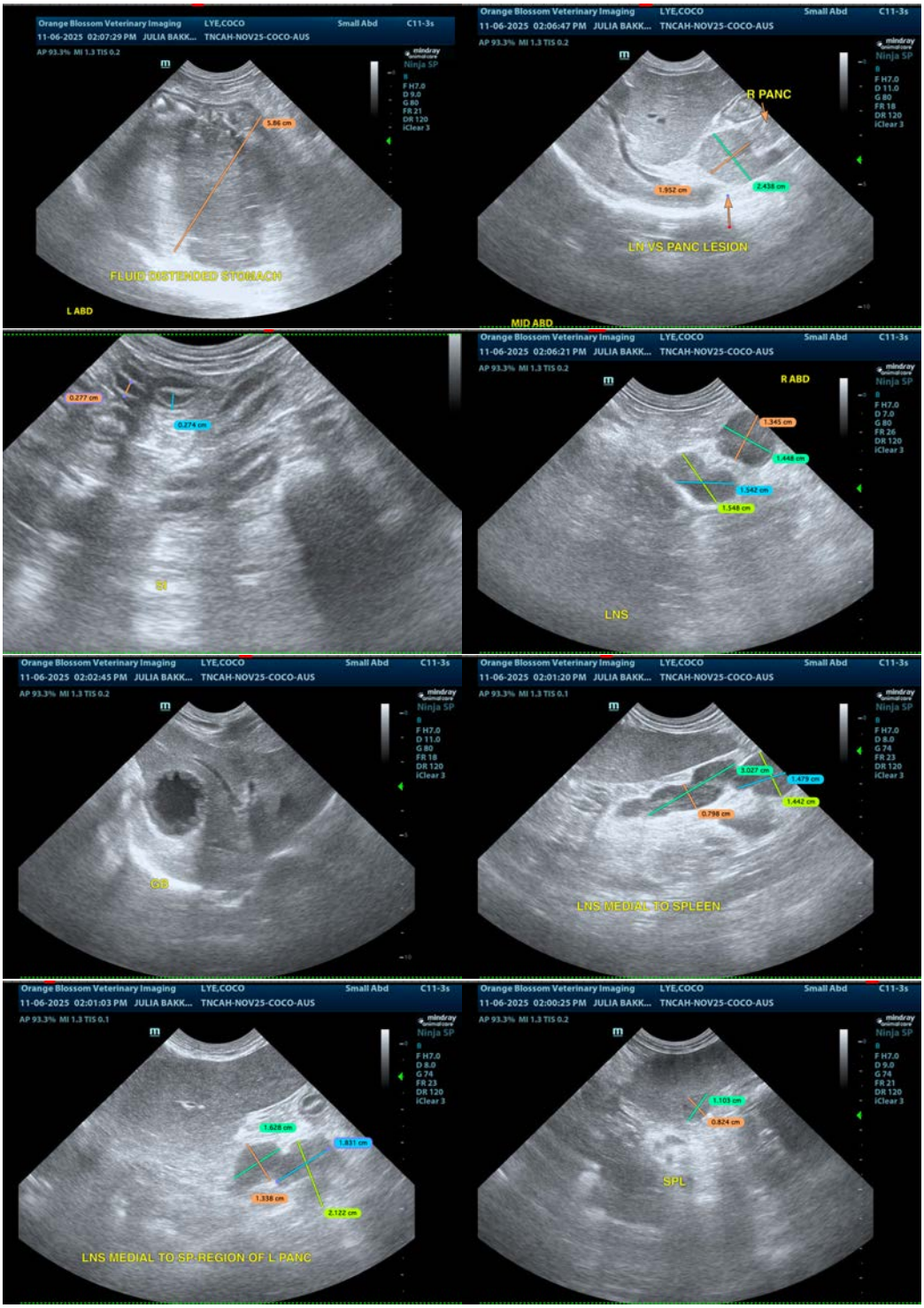

SonoPath

FOSTERING THE ART OF VETERINARY MEDICINE™

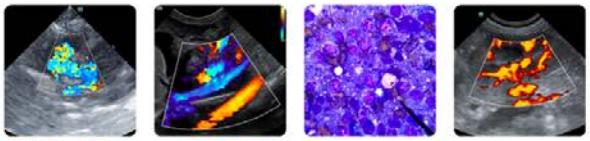

Clinical Sonography & Telecytology

Educational Teleconsultation Services™

SonoPath.com info@sonopath.com 1.800.838.4268

PATIENT

Coco Lye

SPECIES

Canine

BREED

Mixed

SEX

Spayed Female

AGE

16 Years

WEIGHT

22 lbs

INTERPRETED BY

Kathleen Sennello DVM, MS, Diplomate ACVIM (Small Animal Internal Medicine)

IMAGING PERFORMED BY

Julia Bakker, DVM

HOSPITAL NAME

Orange Blossom VI

REFERRING VET

Kristen Hillard, DVM

INVOICE

71641

DATE

11/6/25

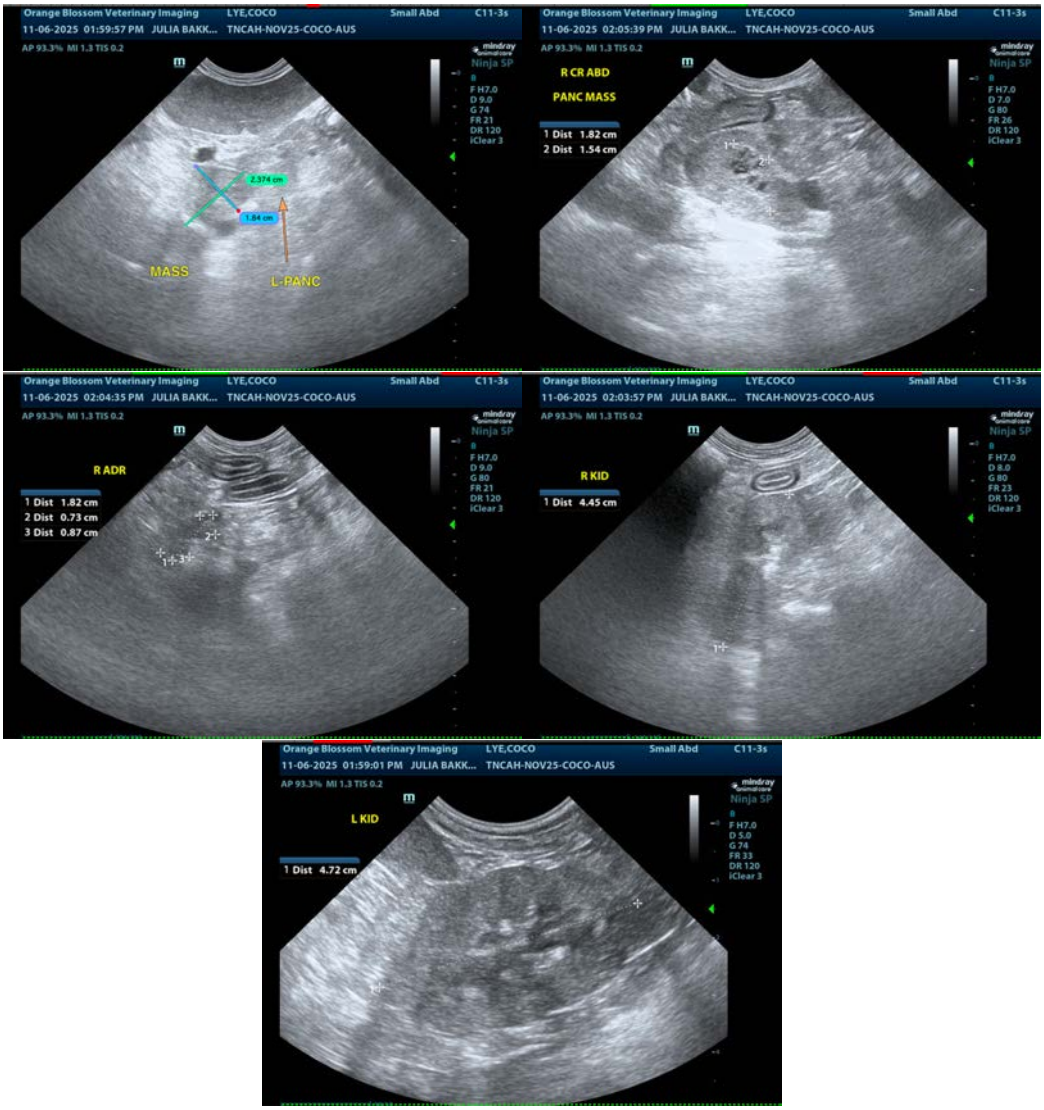

The information and recommendations provided are based on the images presented by the referring veterinarian/sonographer. No evaluation can be communicated regarding pathology that was not visible in the image/video clips provided.

Thank you for this referral. If the clinical or image interpretation does not parallel your findings or if I can be of any further assistance please contact me.

Kathleen Sennello DVM,MS, Diplomate ACVIM (Small animal Internal Medicine)

info@sonopath.com