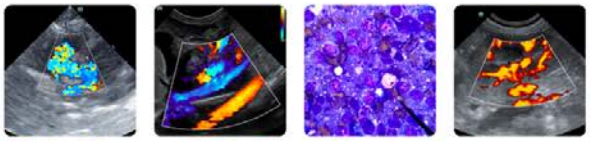

PATIENT
Bitsy Juarez

SPECIES
Canine

BREED
Chihuahua x

SEX
Spayed Female

AGE
8 Years

WEIGHT
5.0 kg

INTERPRETED BY
Kathleen Sennello DVM, MS, Diplomate ACVIM (Small Animal Internal Medicine)

IMAGING PERFORMED BY
Karin Hinkle, DVM

HOSPITAL NAME
Yellow Dog Imaging

REFERRING VET
Karin Hinkle, DVM

INVOICE
71643

DATE
11/6/25

PRESENTING CLINICAL SIGNS

Patient presented 11/6 as a transfer for newly diagnosed diabetes. The patient has had intermittent vomiting and anorexia in the last week. There's a history of a distended belly, and the patient has been tested for Cushing's twice with inconclusive results.

Abnormal PE/Chem/CBC/UA Results: rDVM X-rays of the abdomen showed hepatomegaly. Blood work showed markedly elevated blood sugar (>500), elevated CPLI, Renal values today: BUN>100 Creat 3.4 HCT 32% UA sg 1.016 suspected cocci; prior bloodwork from 11/5 attached. Working Diagnosis: diabetic ketoacidosis (DKA), potential for pancreatitis, and hepatopathy open diagnosis

ULTRASONOGRAPHIC EXAMINATION OF THE ABDOMEN

Urinary System

The urinary bladder is moderately distended with anechoic urine. The Bladder wall, trigone, ureteral papillae and visible urethra (to a depth of 2cm) appear normal with no evidence of wall thickening, mucosal irregularities, masses or cystic calculi.

The left kidney has a normal shape and size (5.31 cm) with pyelectasia at 0.22 cm. Overall echogenicity is slightly hyperechoic with mildly reduced corticomedullary distinction and a typical 1:3 cortex:medulla ratio. There is no evidence of focal perinephric inflammation or effusion. There is no evidence of nephroliths, infarcts or hydroureter. Renal vasculature is normal.

The right kidney has a normal shape and size (5.14 cm) with pyelectasia at 0.19 cm. Overall echogenicity is slightly hyperechoic with mildly reduced corticomedullary distinction and a typical 1:3 cortex:medulla ratio. There is no evidence of focal perinephric inflammation or effusion. There is no evidence of nephroliths, infarcts or hydroureter. Renal vasculature is normal.

Adrenal Glands

The left adrenal gland is “plump” measuring 0.52 cm at the cranial pole and 0.63 cm at the caudal pole. It is observed in its normal position cranial to the left renal artery. It is normal in appearance (uniformly hypoechoic) and shape with no evidence of a mass effect.

The right adrenal gland is normal in size measuring 0.92 cm at the cranial pole and 0.49 cm at the caudal pole. It is observed in its normal position between the cranial aspect of the right kidney and the caudal vena cava. It is normal in appearance (uniformly hypoechoic) and shape with no evidence of a mass effect.

Spleen

The spleen is subjectively normal in size (1.35 cm), The spleen echotexture is heterogenous and mottled, the splenic capsule is smooth with no irregularities. The blood flow through the hilus and splenic parenchyma appears normal. There is a small hypoechoic nodule towards the caudal aspect of the spleen measuring 0.31 cm.

Liver

The liver is large in size, and hyperechoic with rounded margins. The parenchyma is heterogenous in echotexture with subtle, indistinct focal mottling. The visible portions of the vasculature and biliary tract appear normal. No focal nodules or cystic lesions are observed.

PATIENT
Bitsy Juarez

SPECIES
Canine

BREED
Chihuahua x

SEX
Spayed Female

AGE
8 Years

WEIGHT
5.0 kg

INTERPRETED BY
Kathleen Sennello DVM, MS, Diplomate ACVIM (Small Animal Internal Medicine)

IMAGING PERFORMED BY
Karin Hinkle, DVM

HOSPITAL NAME
Yellow Dog Imaging

REFERRING VET
Karin Hinkle, DVM

INVOICE
71643

DATE
11/6/25

The gall bladder lumen is moderately distended. The gallbladder wall measures 0.20 cm. Luminal contents are mild and likely incidental at this time. The cystic and common bile ducts are normal/not visible.

Gastrointestinal

The stomach contains moderate fluid. It measures at a normal thickness of 0.47 cm with some variability due to the presence of rugal folds. The distinction of the gastric wall layers is adequate and there is no impression of reduced peristaltic activity. No masses or focal lesions were observed.

The visualized areas of duodenum, jejunum and ileum have a relatively uniform diameter with minimal fluid distension. Wall thickness is normal. Bowel loops follow a curvilinear path with distinct wall layering maintaining the typical 1:3 muscularis:mucosa layer ratio. Duodenum wall measures 0.37 cm. Jejunum wall measures 0.26 cm. Visualized peristalsis appears appropriate. There were no focal lesions consistent with obstruction or a mass effect observed.

Sections of colon are visualized with formed fecal material and gas shadowing distally. There is no observed focal or generalized colon wall thickening or loss of layering.

Pancreas

The pancreas is prominent, hypoechoic and mottled, particularly in the right limb. There is no evidence of nodules or cystic lesions. There is mild mesenteric inflammation in the right cranial abdomen.

Free Abdomen

Evaluation of the peritoneal cavity did not reveal any evidence of effusion. There is no evidence of a significant diffuse lymphadenopathy. The left iliac lymph node is prominent measuring 0.72 cm. The omentum is mildly hyperechoic in the right cranial abdomen around the right limb of the pancreas.

ULTRASONOGRAPHIC FINDINGS

- Age related changes visualized associated with both kidneys as well as mild pyelectasia – Pyelectasia of the kidney(s)could be consistent with pyelonephritis, chronic renal disease, secondary to PU/PD or fluid therapy (if applicable), other.
- Prominent, mottled spleen with a small hypoechoic nodule – The diffuse splenic changes are non-specific and could be consistent with lymphoid hyperplasia, extramedullary hematopoiesis, infiltrative neoplasia, inflammation, other. Cytology or histopathology would be necessary to get a definitive diagnosis.
- Pancreatic changes in the right limb most consistent with mild chronic pancreatitis.
- Large, hyperechoic, heterogeneous liver – Findings could be consistent with a significant vacuolar/diabetic hepatopathy. Infiltrative neoplasia cannot be excluded as a differential.
- Moderate fluid distended stomach – Findings are most consistent with gastric ileus secondary to pancreatitis. Continued monitoring is warranted.

PATIENT

Bitsy Juarez

SPECIES

Canine

BREED

Chihuahua x

SEX

Spayed Female

AGE

8 Years

WEIGHT

5.0 kg

INTERPRETED BY

Kathleen Sennello DVM, MS, Diplomate ACVIM (Small Animal Internal Medicine)

IMAGING PERFORMED BY

Karin Hinkle, DVM

HOSPITAL NAME

Yellow Dog Imaging

REFERRING VET

Karin Hinkle, DVM

INVOICE

71643

DATE

11/6/25

INTERPRETATION OF THE FINDINGS & FURTHER RECOMMENDATIONS

Both kidneys have mild changes and mild pyelectasia. Correlate with urinalysis, culture and blood pressure.

The spleen appears mildly mottled with a small, hypoechoic nodule. Consider a fine needle aspirate to further evaluate.

The cranial aspect of the right limb of the pancreas is prominent with some mild surrounding inflammation, most consistent with mild chronic pancreatitis.

The liver is very large and very hyperechoic and mottled. These changes could be consistent with a significant vacuolar hepatopathy/diabetic hepatopathy. If clinical suspicion for round cell neoplasia is high, a fine needle aspirate could be considered to rule this out.

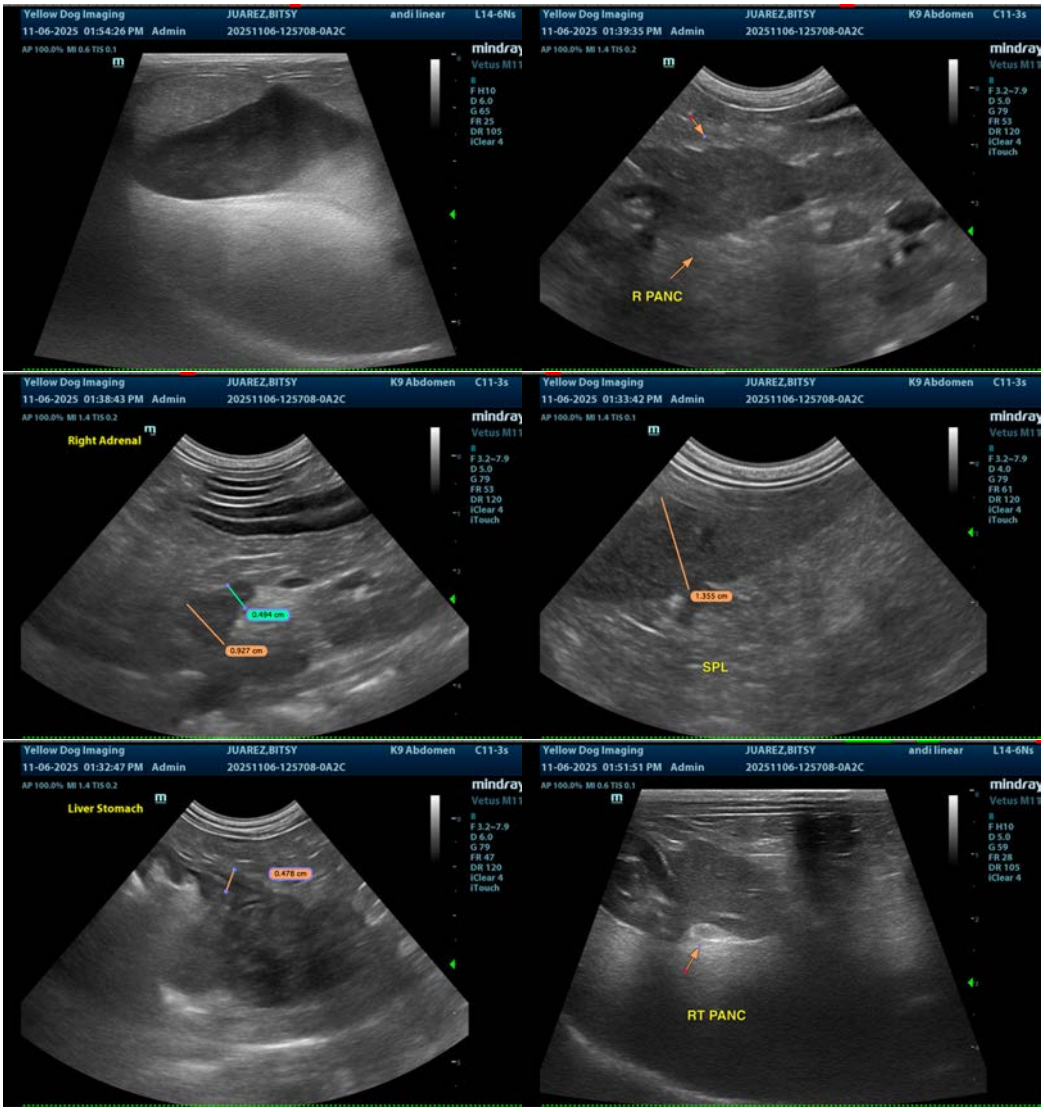

SonoPath

FOSTERING THE ART OF VETERINARY MEDICINE™

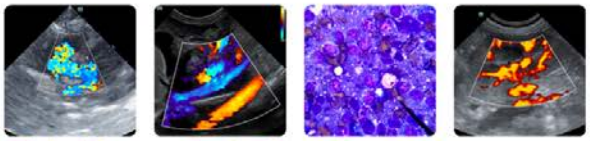

Clinical Sonography & Telecytology

Educational Teleconsultation Services™

SonoPath.com info@sonopath.com 1.800.838.4268

PATIENT

Bitsy Juarez

SPECIES

Canine

BREED

Chihuahua x

SEX

Spayed Female

AGE

8 Years

WEIGHT

5.0 kg

INTERPRETED BY

Kathleen Sennello DVM, MS, Diplomate ACVIM (Small Animal Internal Medicine)

IMAGING PERFORMED BY

Karin Hinkle, DVM

HOSPITAL NAME

Yellow Dog Imaging

REFERRING VET

Karin Hinkle, DVM

INVOICE

71643

DATE

11/6/25

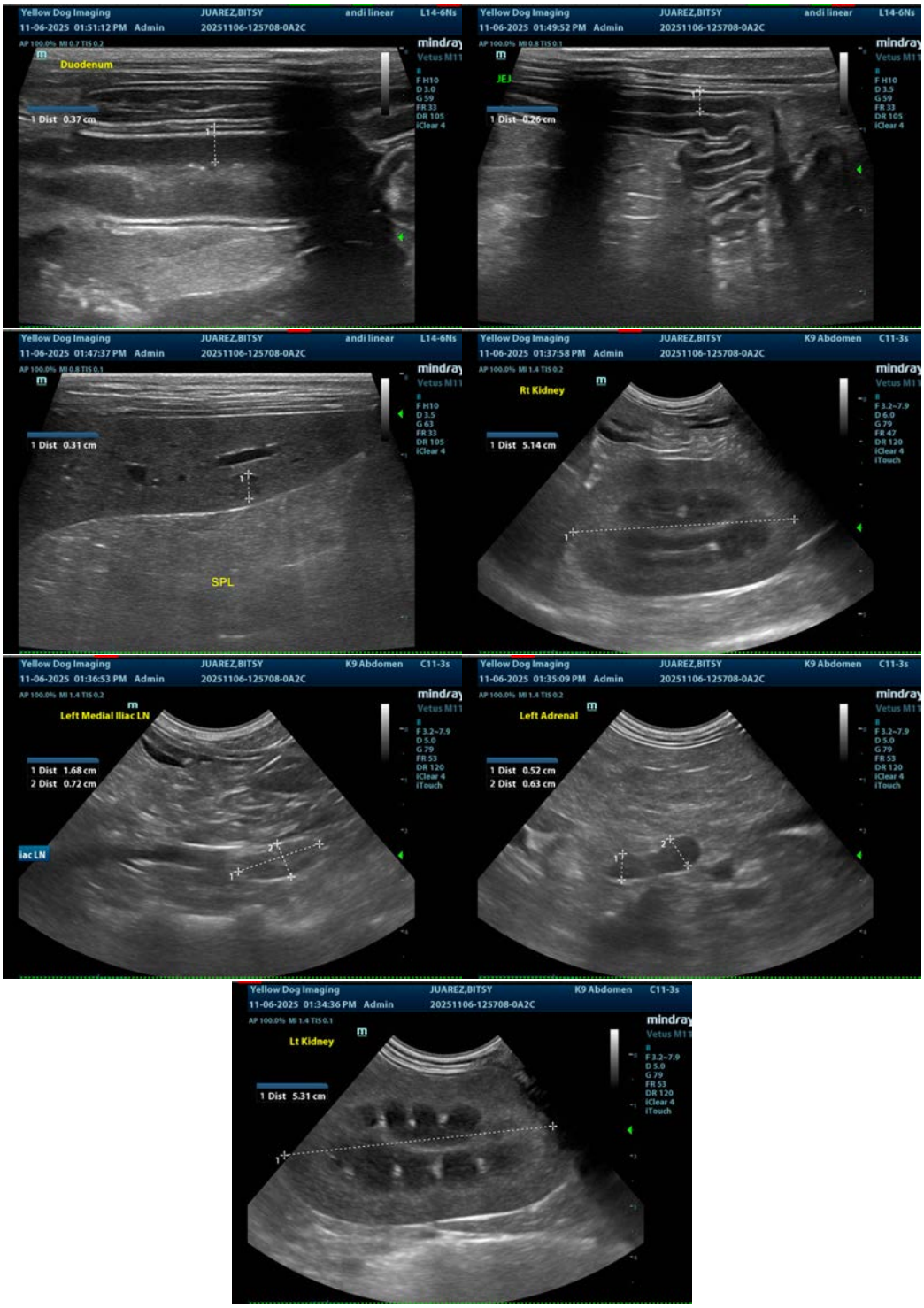

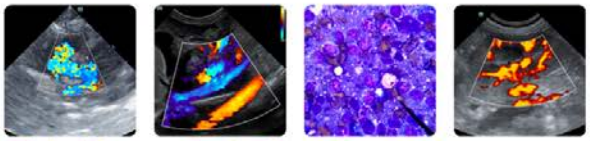

PATIENT

Bitsy Juarez

SPECIES

Canine

BREED

Chihuahua x

SEX

Spayed Female

AGE

8 Years

WEIGHT

5.0 kg

INTERPRETED BY

Kathleen Sennello DVM, MS, Diplomate ACVIM (Small Animal Internal Medicine)

IMAGING PERFORMED BY

Karin Hinkle, DVM

HOSPITAL NAME

Yellow Dog Imaging

REFERRING VET

Karin Hinkle, DVM

INVOICE

71643

DATE

11/6/25

The information and recommendations provided are based on the images presented by the referring veterinarian/sonographer. No evaluation can be communicated regarding pathology that was not visible in the image/video clips provided.

Thank you for this referral. If the clinical or image interpretation does not parallel your findings or if I can be of any further assistance please contact me.

Kathleen Sennello DVM,MS, Diplomate ACVIM (Small animal Internal Medicine)

info@sonopath.com