

**DATE PRESENTING CLINICAL SIGNS**

11/5/21

History: Referral

Date: 11-05-2021 Notes: Referral from rDVM - Diabetic, azotemia, possible splenic mass? RDVM phone call - rDVM is Dr. Racz- owner is the mother in law Roxy- 10 yr FS maltese- family dog, mother in law PC: ADR, pale gums, waxing and waning appetite, vomiting water PC: pale mucous membranes, tachycardic X rays- possible splenic tumor, no FF.

PATIENT

Roxy Ernst

Lab Results: HCT = 34, WBC = 27k, neutrophilia, Thrombocytosis, ALKP = 1500, BUN = off scale high, Crea = 3.8, glucose severely elevated, and hyperphosphatemia.

Current Medications: None

SPECIES

Canine

Date of Previous IntraPet Ultrasound: No previous

Sedation: Not required for scan.

Stat Report: Not requested.

BREED

Maltese

ULTRASONOGRAPHIC EXAMINATION OF THE ABDOMEN**Urinary System**

The urinary bladder is moderately distended with anechoic urine. The Bladder wall, trigone, ureteral papillae and visible urethra (to a depth of 2cm) appear normal with no evidence of wall thickening, mucosal irregularities, masses or cystic calculi.

AGE

2010

The left kidney has a normal shape and size (4.59 cm). Overall echogenicity is normal with adequate corticomedullary distinction and a typical 1:3 cortex:medulla ratio. There is no evidence of perinephric inflammation or effusion. A 0.29 cm cortical cyst was noted. There is no evidence of pyelectasia, nephroliths, infarcts or hydroureter. Renal vasculature is normal.

WEIGHT

9.03 lbs

The right kidney has a normal shape and size (4.55 cm). Overall echogenicity is normal with adequate corticomedullary distinction and a typical 1:3 cortex:medulla ratio. There is no evidence of perinephric inflammation or effusion. There is no evidence of pyelectasia, nephroliths, infarcts or hydroureter. Renal vasculature is normal.

INTERPRETED BY

Kathleen Sennello
DVM, MS, Diplomate
ACVIM (Small Animal
Internal Medicine)

Adrenal Glands

The left adrenal gland is normal in size measuring 0.61 cm at the caudal pole. It is observed in its normal position cranial to the left renal artery. It is normal in appearance (uniformly hypoechoic) and shape with no evidence of a mass effect.

IMAGING PERFORMED BY

Rachel Brillhart RDMS

The right adrenal gland is normal in size measuring 0.53 cm at the caudal pole. It is observed in its normal position between the cranial aspect of the right kidney and the caudal vena cava. It is normal in appearance (uniformly hypoechoic) and shape with no evidence of a mass effect.

HOSPITAL NAME

Animal Emergency
Hospital

Spleen

The spleen is subjectively (normal or large) in size. The spleen echotexture is heterogenous and mottled, the splenic capsule is smooth with no irregularities. The blood flow through the hilus and splenic parenchyma appears normal. No focal parenchymal abnormalities are visualized. There is a small 0.57 cm hypoechoic nodule visualized in the periphery of the spleen.

REFERRING VET

Dr. Kalwa

Liver

The liver is subjectively normal in size, and echogenicity with smooth peripheral margins. The parenchyma is heterogenous in echotexture with subtle, indistinct focal mottling. The visible portions of the vasculature and biliary tract appear normal. No focal nodules or cystic lesions are observed. The gallbladder lumen is moderately distended. The wall of the gallbladder is not thickened and has a smooth mucosal surface. There

INVOICE

92914

is a moderate amount of non-organized echogenic debris. The cystic and common bile ducts are normal/not visible.

Gastrointestinal

The stomach contains minimal luminal contents. It measures at a normal thickness of <0.7cm with some variability due to the presence of rugal folds. The distinction of the gastric wall layers is adequate and there is no impression of reduced peristaltic activity. No masses or focal lesions were observed.

The visualized areas of duodenum, jejunum and ileum have a relatively uniform diameter with minimal fluid distension. Wall thickness is normal. Bowel loops follow a curvilinear path with distinct wall layering maintaining the typical 1:3 muscularis:mucosa layer ratio. The duodenum measured as normal and the jejunum measured as normal (0.34 cm). Visualized peristalsis appears appropriate. There were no focal lesions consistent with obstruction or a mass effect observed.

The ileocecal junction was visualized and exhibited normal intact wall layering and is subjectively of normal thickness. Sections of colon are visualized with formed fecal material and gas shadowing distally. There is no observed focal or generalized colon wall thickening or loss of layering.

Pancreas

The pancreas is large and hypoechoic to surrounding mesentery. There is no evidence of nodules or cystic lesions. There is evidence of regional mesenteric inflammation. This is consistent with mild pancreatitis.

Free Abdomen

Evaluation of the peritoneal cavity did not reveal any evidence of effusion, or subjective lymphadenomegaly. The Medial iliac nodes appear normal and there was no evidence of a caudal aortic thrombus at the bifurcation. The omentum is of normal uniform echogenicity.

ULTRASONOGRAPHIC FINDINGS

PRIMARY FINDINGS:

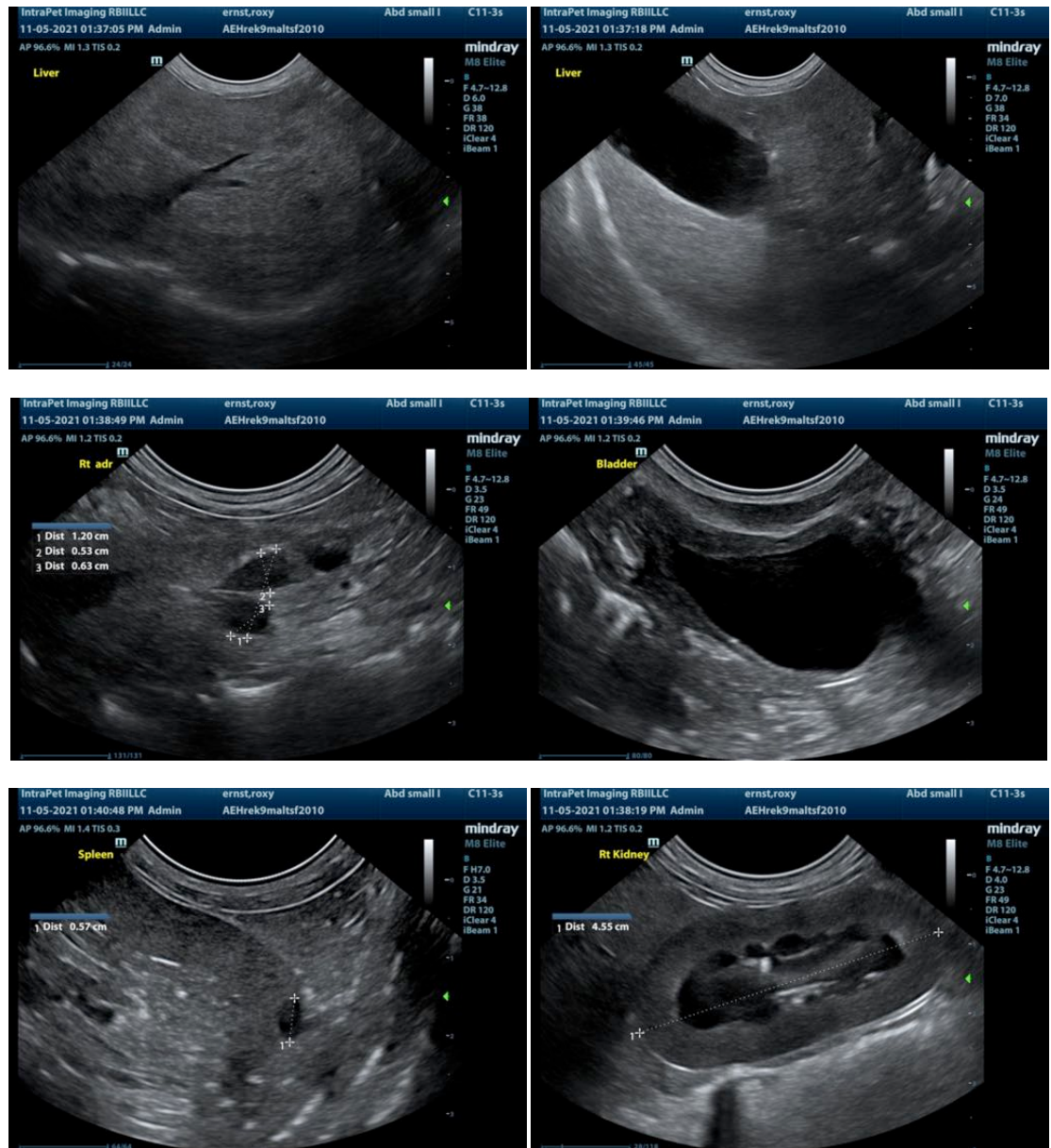
- Large heterogenous liver. The diffuse hepatic changes are non-specific and could be consistent with vacuolar hepatopathy, nodular hyperplasia, inflammatory/immune-mediated disease, fibrosis, extramedullary hematopoiesis, toxic hepatopathy (e.g., copper), infiltrative neoplasia (less likely) or other hepatopathy. Findings are most consistent with diabetic hepatopathy.
- Prominent, hypoechoic and mottled pancreas.
- Mildly mottled spleen with hypoechoic nodule. There is a non-cavitated, hypoechoic splenic nodule visualized. Differentials include lymphoid hyperplasia, extramedullary hematopoiesis, infiltrative neoplasia, inflammation, other. Cytology or histopathology would be necessary to get a definitive diagnosis

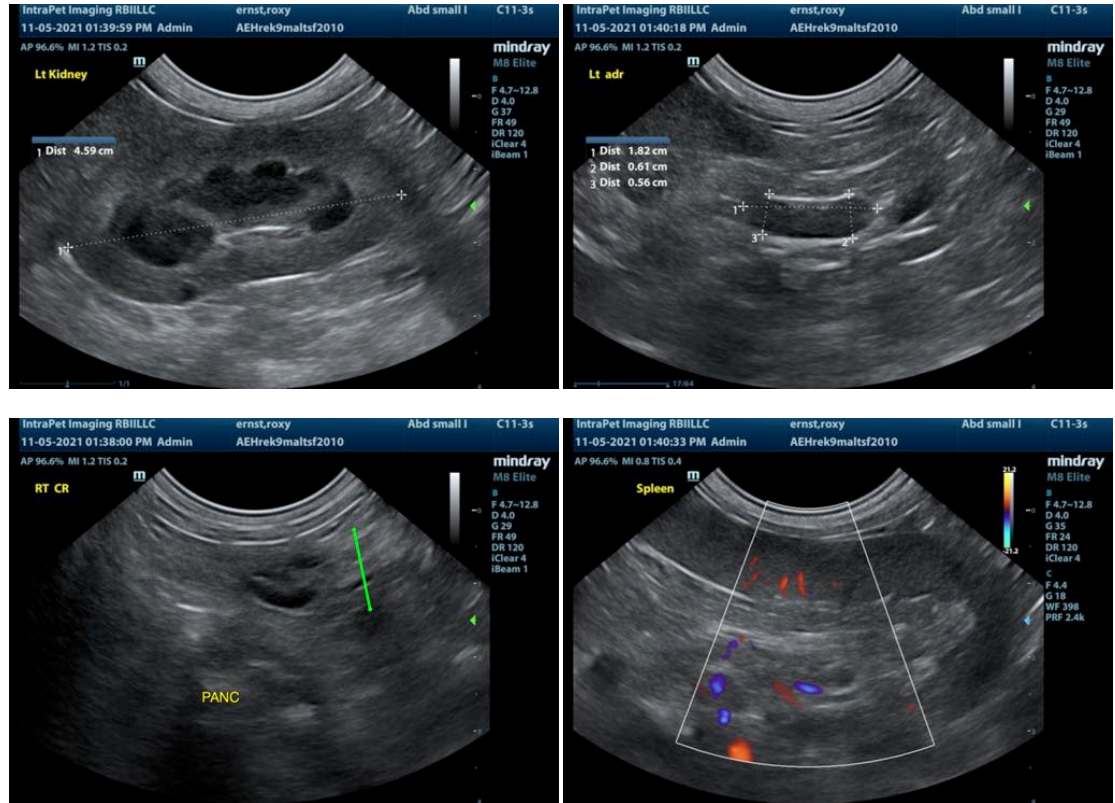
INTERPRETATION OF THE FINDINGS & FURTHER RECOMMENDATIONS

Many of the changes observed on today's scan are common in diabetic patients. The liver is large and heterogenous. The pancreas does appear somewhat inflamed so there is likely either a current pancreatitis or a previous episode of pancreatitis that is resolving. There is a very small hypoechoic splenic nodule observed. The kidneys appear relatively normal with no evidence of pyelectasia. Hopefully there is a significant pre-renal component to the azotemia reported.

I recommend aggressive therapy for the DKA with fluid resuscitation, insulin, electrolyte therapy, etc. I recommend urinalysis and culture along with blood pressure evaluation. I recommend a low fat diet with GI medications for possible concurrent pancreatitis.

Once the patient is stabilized and feeling well you can make decisions regarding the splenic nodule. Options moving forward include either continued monitoring with ultrasound or a FNA of the spleen.





The information and recommendations provided are based on the images presented by the referring veterinarian. No evaluation can be communicated regarding pathology that was not visible in the image/video clips provided.

Thank you for this referral. If the clinical or image interpretation does not parallel your findings or if I can be of any further assistance please contact me.

Kathleen Sennello DVM,MS, Diplomate ACVIM (Small animal Internal Medicine)
 kathleen.sennello@sonopath.com