

**DATE**

11/5/21

PRESENTING CLINICAL SIGNS

History: possible Cushing's.
Lab Results: pending.
Date of Previous IntraPet Ultrasound: No previous.
Sedation: Not required for scan.
Stat Report: Not requested, declined.

PATIENT

Remy Kalbskopf

SPECIES

Canine

BREED

Chihuahua

SEX

Neutered male

AGE

2009

WEIGHT

22 lbs

ULTRASONOGRAPHIC EXAMINATION OF THE ABDOMEN**Urinary System**

The urinary bladder is moderately distended with anechoic urine. The Bladder wall, trigone, ureteral papillae and visible urethra (to a depth of 2cm) appear normal with no evidence of wall thickening, mucosal irregularities, masses or cystic calculi.

The prostate is normal in size (0.96 cm) and shape for this neutered male dog. The parenchyma is homogenous and the external margins are smooth. The prostatic urethra appears normal with no evidence of irregularity, invasion, mass effect or calculi.

The left kidney has a normal shape and size (5.28 cm). Overall echogenicity is slightly hyperechoic with poor corticomedullary distinction and a typical 1:3 cortex:medulla ratio. There is no evidence of perinephric inflammation or effusion. Small cortical cysts were noted. There is no evidence of pyelectasia, nephroliths, infarcts or hydronephrosis. Renal vasculature is normal.

The right kidney has a normal shape and size (5.24 cm). Overall echogenicity is slightly hyperechoic with poor corticomedullary distinction and a typical 1:3 cortex:medulla ratio. There is no evidence of perinephric inflammation or effusion. Large cortical cysts were noted and measured 1.09 cm. Several smaller cysts were noted. There is no evidence of pyelectasia, nephroliths, infarcts or hydronephrosis. Renal vasculature is normal.

INTERPRETED BY

Kathleen Sennello
DVM, MS, Diplomate
ACVIM (Small Animal
Internal Medicine)

IMAGING PERFORMED BY

Rachel Brillhart RDMS

Adrenal Glands

The left adrenal gland is normal in size measuring 0.83 cm at the caudal pole. It is observed in its normal position cranial to the left renal artery. It is normal in appearance (uniformly hypoechoic) and shape with no evidence of a mass effect.

The right adrenal gland is large in size measuring 1.47 cm at the cranial pole, 2.13 cm at the caudal pole and 3.86 cm in length. There is a hypoechoic area in the caudal pole of the adrenal gland measuring 2.0 x 1.76 cm. The adrenal gland is in its normal position between the cranial aspect of the right kidney and the cranial vena cava. It is irregular in appearance and there appears to be an irregular caudal pole and this irregularity appears to extend within local vasculature making increasing suspicion for possible vascular invasion.

HOSPITAL NAME

AMC of Bel Air

Spleen

The spleen is subjectively normal in size, echotexture is homogenous, and the splenic capsule is smooth with no irregularities. The blood flow through the hilus and splenic parenchyma appears normal. No focal parenchymal abnormalities are visualized.

REFERRING VET

Dr. Chaudhry

Liver

The liver is subjectively normal in size, and echogenicity with smooth peripheral margins. The parenchyma is homogenous echotexture. The visible portions of the vasculature and biliary tract appear normal. No focal nodules or cystic lesions are observed. The gallbladder lumen is moderately distended. The wall of the gallbladder is not thickened and has a smooth mucosal surface. Luminal contents are primarily anechoic. The cystic and common bile ducts are normal/not visible.

INVOICE

92917

Gastrointestinal

The stomach contains minimal luminal contents. It measures at a normal thickness of <0.7cm with some variability due to the presence of rugal folds. The distinction of the gastric wall layers is adequate and there is no impression of reduced peristaltic activity. No masses or focal lesions were observed.

The visualized areas of duodenum, jejunum and ileum have a uniform diameter with minimal fluid distension. Wall appears subjectively, mildly increased. Some areas have significant mucosal speckling and fogging. Detailed wall layering appears normal to mildly diminished. Bowel loops follow a typical curvilinear path with distinct wall layering. The duodenum measured 0.8 cm and the jejunum measured 0.39 cm. Visualized peristalsis appears appropriate. There were no focal lesions consistent with obstruction or a mass effect observed

The ileocecal junction was visualized and exhibited normal intact wall layering and is subjectively of normal thickness. Sections of colon are visualized with formed fecal material and gas shadowing distally. There is no observed focal or generalized colon wall thickening or loss of layering.

Pancreas

The pancreas is prominent and mottled compared to the surrounding isoechoic mesentery. There is no evidence of nodules or cystic lesions. There is no evidence of regional mesenteric inflammation or fluid.

Free Abdomen

Evaluation of the peritoneal cavity did not reveal any evidence of effusion, or subjective lymphadenomegaly. The Medial iliac nodes appear normal and there was no evidence of a caudal aortic thrombus at the bifurcation. The omentum is of normal uniform echogenicity.

ULTRASONOGRAPHIC FINDINGS

PRIMARY FINDINGS:

- Right adrenal mass with possible vascular invasion. Left/right adrenomegaly could be consistent with neoplasia (e.g., adenoma, carcinoma, pheochromocytoma), hyperplasia, inflammation, other.
- Decreased corticomedullary distinction in both kidneys with cortical cysts. Mild loss of corticomedullary distinction in both kidneys could be consistent with chronic degenerative disease or interstitial nephrosis.
- Prominent, mottled pancreas. The pancreatic changes are most consistent with age-related parenchymal remodeling, potentially secondary to a prior inflammatory episode, early fibrosis or chronic pancreatitis.
- Large heterogenous liver. The diffuse hepatic changes are non-specific and could be consistent with vacuolar hepatopathy, nodular hyperplasia, inflammatory/immune-mediated disease, fibrosis, extramedullary hematopoiesis, toxic hepatopathy (e.g., copper), infiltrative neoplasia (less likely) or other hepatopathy.
- Thickened small intestine with mucosal speckling. Bright mucosal speckling has been proposed to represent dilated lacteals or focal accumulation of mucus, cellular debris etc.. in the mucosal crypts of the small intestine.

SECONDARY FINDINGS:

- Mild gallbladder debris. The significance of the aggregated gallbladder debris is unclear. This could represent an early mucocele, cholestasis, or may be secondary to fasting.
- Moderate ingesta within the gastric lumen. Correlate these findings with feeding history. If the patient is adequately fasted then consider delayed gastric emptying or partial obstruction (not observed).

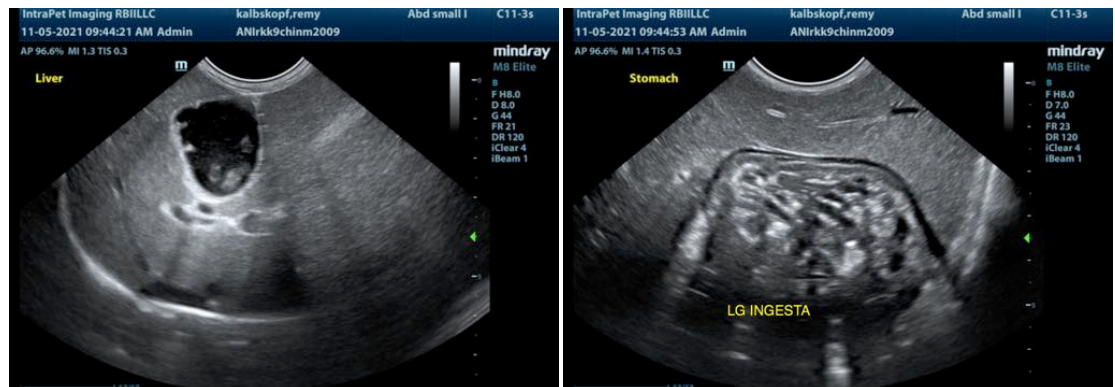
INTERPRETATION OF THE FINDINGS & FURTHER RECOMMENDATIONS

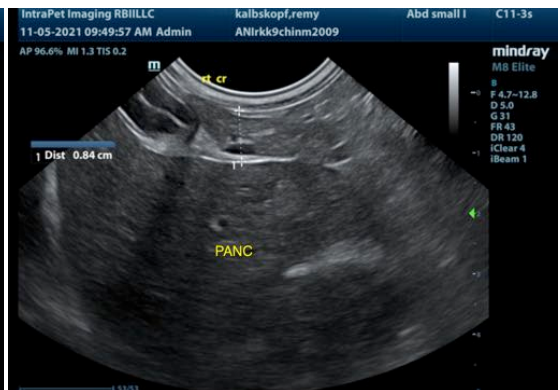
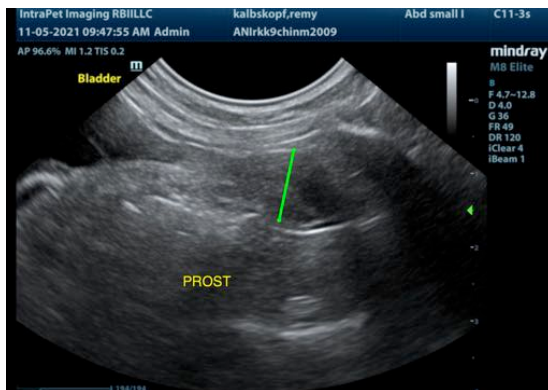
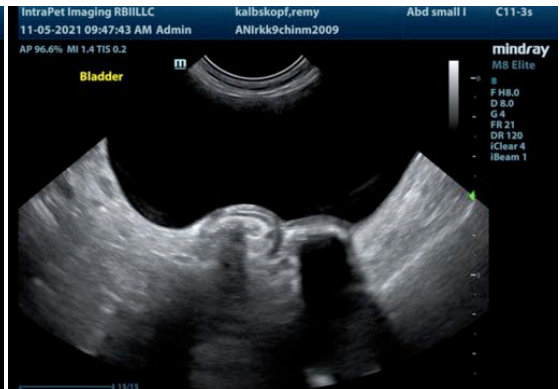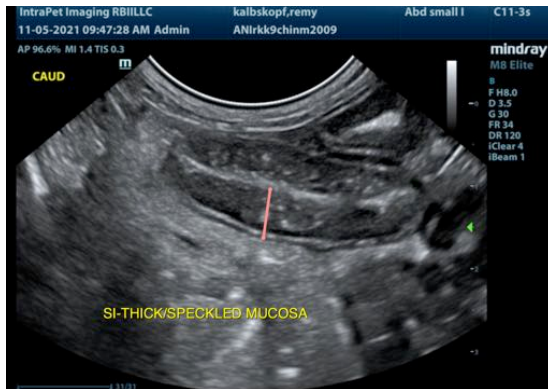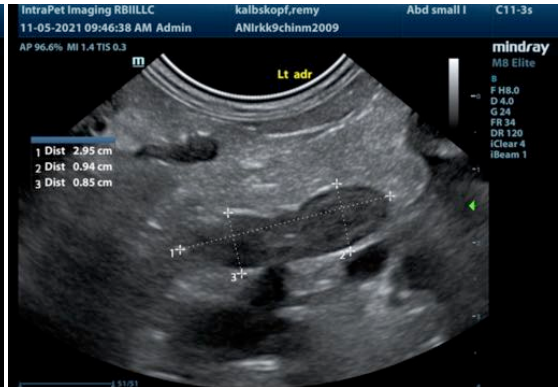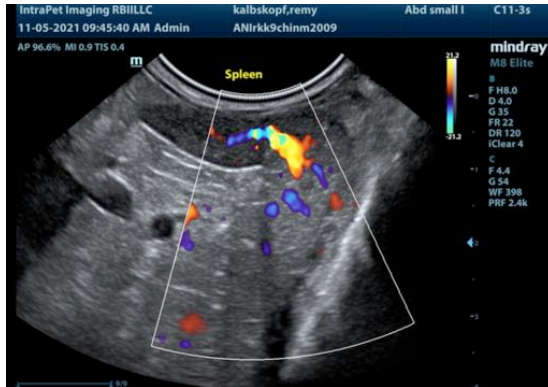
There is a mass present involving the right adrenal gland. This mass is somewhat irregular and there is evidence of possible early vascular invasion. These masses can be benign or malignant and can secrete hormones or be non-active. Based on the irregular appearance of this mass a cancerous process is considered more likely. Options moving forward include:

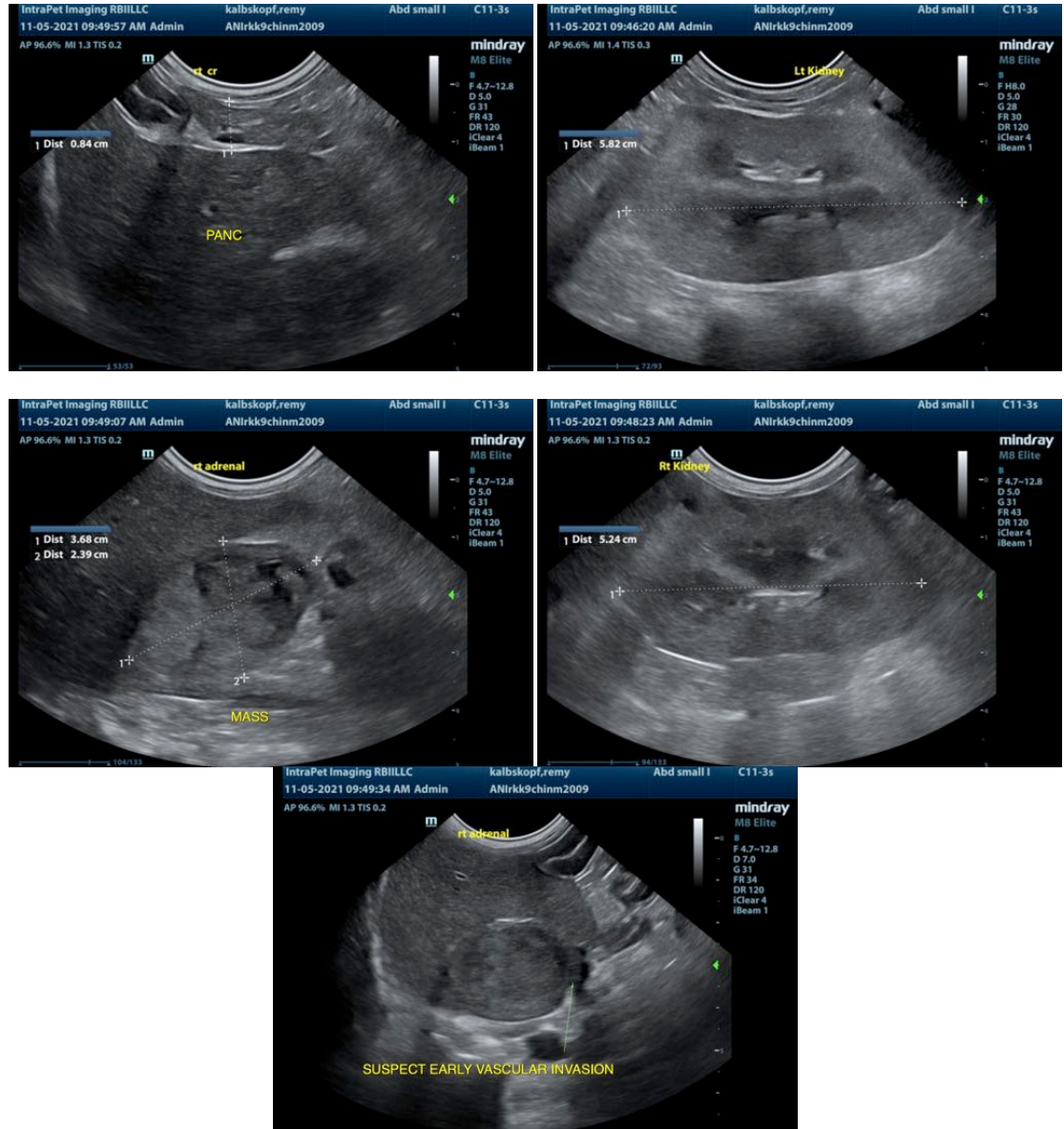
- If signs of Cushing's are present, consider adrenal function testing. I prefer an ACTH stimulation test combined with an adrenal panel to the University of Tennessee's endocrine lab to look for atypical adrenal hormones as well as cortisol. (other testing can suffice)
- If adrenal dependent Cushing's is suspected and supported by adrenal function testing consider medical therapy with Lysodren or Trilostane and/or consider surgical removal (recommend referral to a board certified veterinary surgeon and possible pre op CT)-This can be a challenging surgery with significant risk for complication
- Recommend blood pressure evaluation-if hypertensive consider testing catecholamine levels for a possible pheochromocytoma
- Due to the invasive nature of these masses a CT scan is recommended to evaluate for metastasis and vascular invasion.
- If no symptoms of Cushing's are present, consider either referral for surgery or if surgery is not an option consultation with a veterinary oncologist regarding chemotherapeutic options and continued monitoring with ultrasound (in 4-6 weeks) can be considered.
- Some aggressive adrenal tumors can grow quickly and there is risk for acute hemorrhage from vascular invasion.

The changes observed with the liver and kidneys are most likely consistent with either Cushing's or age related change.

The small intestine additionally appears thick and has some mucosal speckling. If there are no current signs of GI disease then this may be something to monitor if there is evidence of chronic vomiting, diarrhea, etc. then consider such differentials such as food allergy, IBD and most likely intestinal neoplasia, etc. I recommend three view thoracic radiographs.







The information and recommendations provided are based on the images presented by the referring veterinarian. No evaluation can be communicated regarding pathology that was not visible in the image/video clips provided.

Thank you for this referral. If the clinical or image interpretation does not parallel your findings or if I can be of any further assistance please contact me.

Kathleen Sennello DVM,MS, Diplomate ACVIM (Small animal Internal Medicine)
 kathleen.sennello@sonopath.com