



**PATIENT**

Ace Bellamy

**SPECIES**

Canine

**BREED**

Mini Pinscher

**SEX**

Neutered Male

**AGE**

9 Years

**WEIGHT**

18 Years

**INTERPRETED BY**

Kathleen Sennello DVM,  
MS, Diplomate ACVIM  
(Small Animal Internal  
Medicine)

**IMAGING PERFORMED BY**

Yvonna Aranda

**HOSPITAL NAME**

South Willamette  
Veterinary Clinic

**REFERRING VET**

Dr. Willaman

**INVOICE**

71543

**DATE**

11/4/25

**PRESENTING CLINICAL SIGNS**

Clinical Exam Findings: Mild lethargy reported. Abdominal enlargement noted on physical exam with a large firm abdominal mass mid to cranial abdomen.

Abnormal PE/Chem/CBC/UA Results: ABNORMAL Labwork Values not done recently Current Medications none

**ULTRASONOGRAPHIC EXAMINATION OF THE ABDOMEN**

**Urinary System**

The urinary bladder is moderately distended with anechoic urine. The Bladder wall, trigone, ureteral papillae and visible urethra (to a depth of 2cm) appear normal with no evidence of wall thickening, mucosal irregularities, masses or cystic calculi.

The prostate is normal in size (0.69 cm) and shape for this neutered male dog. The parenchyma is homogenous and the external margins are smooth. The prostatic urethra appears normal with no evidence of irregularity, invasion, mass effect or calculi.

The left kidney has a normal shape and size (4.42 cm). Overall echogenicity is normal with adequate corticomedullary distinction and a typical 1:3 cortex:medulla ratio. There is no evidence of focal perinephric inflammation or effusion. There is no evidence of pyelectasia, nephroliths, infarcts or hydroureter. Renal vasculature is normal.

The right kidney has a normal shape and size (4.69 cm). Overall echogenicity is normal with adequate corticomedullary distinction and a typical 1:3 cortex:medulla ratio. There is no evidence of focal perinephric inflammation or effusion. There is no evidence of pyelectasia, nephroliths, infarcts or hydroureter. Renal vasculature is normal.

**Adrenal Glands**

The left adrenal gland is normal in size measuring 0.50 cm at the cranial pole and 0.65 cm at the caudal pole. It is observed in its normal position cranial to the left renal artery. It is normal in appearance (uniformly hypoechoic) and shape with no evidence of a mass effect.

The right adrenal gland is normal in size measuring 0.64 cm at the cranial pole and 0.68 cm at the caudal pole. It is observed in its normal position between the cranial aspect of the right kidney and the caudal vena cava. It is normal in appearance (uniformly hypoechoic) and shape with no evidence of a mass effect.

**Spleen**

The spleen is subjectively normal in size (1.26cm), echotexture is homogenous, and the splenic capsule is smooth with no irregularities. The blood flow through the hilus and splenic parenchyma appears normal. No focal parenchymal abnormalities are visualized.

**Liver**

The liver is large in size, and normal in echogenicity with smooth peripheral margins. The parenchyma is heterogenous in echotexture with subtle, indistinct focal mottling. The visible portions of the vasculature and biliary tract appear normal. There are numerous ill-defined hypoechoic nodules



**PATIENT**

Ace Bellamy

**SPECIES**

Canine

**BREED**

Mini Pinscher

**SEX**

Neutered Male

**AGE**

9 Years

**WEIGHT**

18 Years

**INTERPRETED BY**

Kathleen Sennello DVM,  
MS, Diplomate ACVIM  
(Small Animal Internal  
Medicine)

**IMAGING PERFORMED BY**

Yvonna Aranda

**HOSPITAL NAME**

South Willamette  
Veterinary Clinic

**REFERRING VET**

Dr. Willaman

**INVOICE**

71543

**DATE**

11/4/25

throughout the parenchyma. Examples measure 1.5 cm and 1.51 cm in diameter. Additionally, there is a large, irregular, heterogeneous, multilobulated mid abdominal mass that is suspected to be of hepatic origin, but a vascular association cannot be confirmed. This measures >6.78 cm x 8.82 cm.

The gall bladder lumen is moderately distended. The wall of the gall bladder is not thickened and has a smooth mucosal surface. There is a moderate amount of non-organized echogenic debris. The cystic and common bile ducts are normal/not visible.

**Gastrointestinal**

The stomach contains minimal luminal contents. It measures at a normal thickness of <0.7cm with some variability due to the presence of rugal folds. The distinction of the gastric wall layers is adequate and there is no impression of reduced peristaltic activity. No masses or focal lesions were observed.

The visualized areas of duodenum, jejunum and ileum have a relatively uniform diameter with minimal fluid distension. Wall thickness is normal. Bowel loops follow a curvilinear path with distinct wall layering maintaining the typical 1:3 muscularis:mucosa layer ratio. Duodenum wall measures 0.39 cm. Jejunum wall measures 0.32 cm. Visualized peristalsis appears appropriate. There were no focal lesions consistent with obstruction or a mass effect observed.

Sections of colon are visualized with formed fecal material and gas shadowing distally. There is no observed focal or generalized colon wall thickening or loss of layering.

**Pancreas**

The area of the pancreas is normal and isoechoic to surrounding mesentery. There is no evidence of nodules or cystic lesions. There is no evidence of regional mesenteric inflammation or fluid.

**Free Abdomen**

Evaluation of the peritoneal cavity did not reveal any evidence of effusion. There are occasional prominent lymph nodes in the cranial abdomen. An example measures 0.74 cm x 1.2 cm. A prominent lymph node in the caudal abdomen measures 0.65 cm in diameter. The omentum is hyperechoic around the large mid abdominal mass lesion.

**Other**

A large, heterogeneous, irregular, multilobulated mid abdominal mass effect is described under liver. It is suspected to be of hepatic origin, but an association with the spleen, pancreas, etc. cannot be definitively ruled out.

**ULTRASONOGRAPHIC FINDINGS**

- Large, heterogeneous, multilobulated mid abdominal mass effect. This is suspected to be of hepatic origin. An association with the spleen or pancreas. cannot be definitively ruled out.
- Heterogeneous liver with ill-defined hypoechoic nodules – The diffuse hepatic changes are non-specific and could be consistent with vacuolar hepatopathy, nodular hyperplasia, inflammatory/immune-mediated disease, fibrosis, extramedullary hematopoiesis, toxic hepatopathy (e.g., copper), infiltrative neoplasia (less likely) or other hepatopathy. The nodules observed trend toward a more benign process but underlying neoplasia cannot be ruled out.



**PATIENT**

Ace Bellamy

**SPECIES**

Canine

**BREED**

Mini Pinscher

**SEX**

Neutered Male

**AGE**

9 Years

**WEIGHT**

18 Years

**INTERPRETED BY**

Kathleen Sennello DVM,  
 MS, Diplomate ACVIM  
 (Small Animal Internal  
 Medicine)

**IMAGING  
 PERFORMED BY**

Yvonna Aranda

**HOSPITAL NAME**

South Willamette  
 Veterinary Clinic

**REFERRING VET**

Dr. Willaman

**INVOICE**

71543

**DATE**

11/4/25

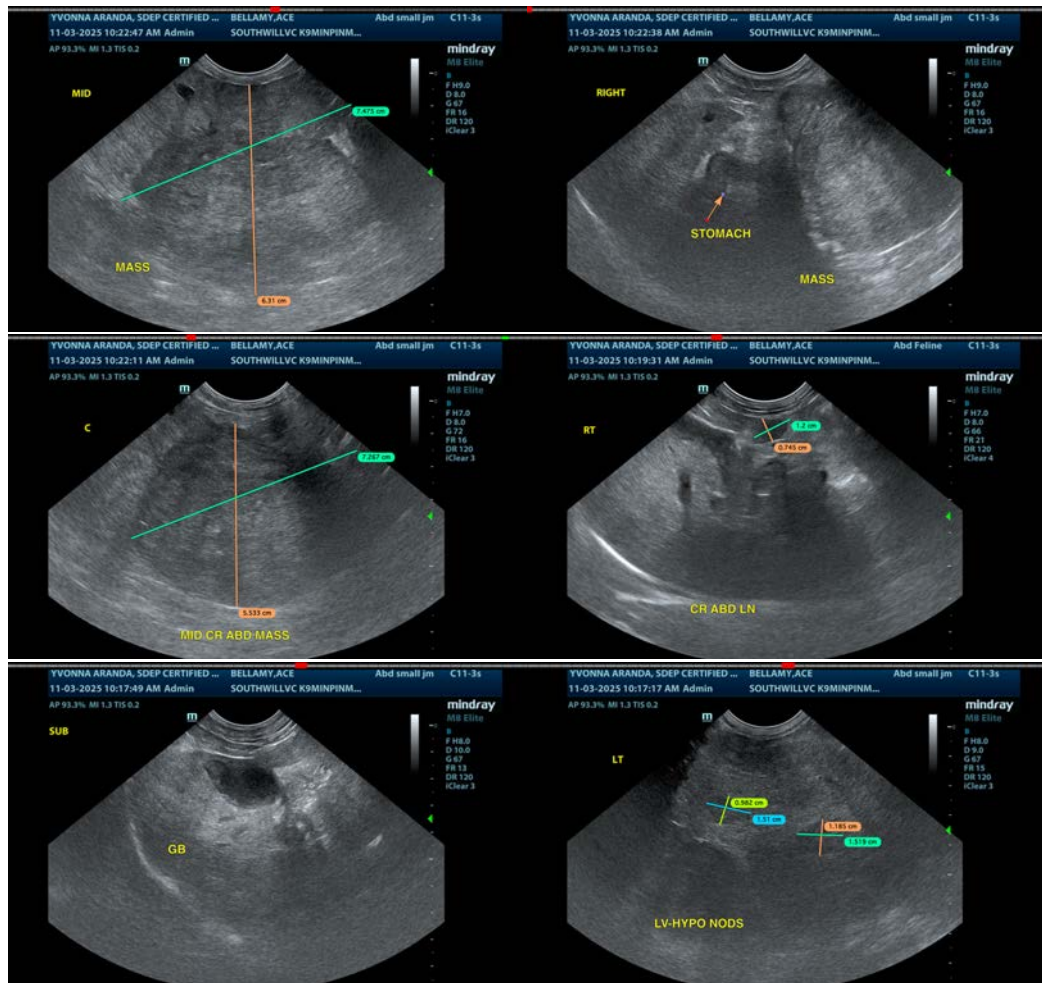
- Occasional prominent abdominal lymph nodes – Findings could be consistent with reactive lymph nodes or early metastatic lymph nodes.

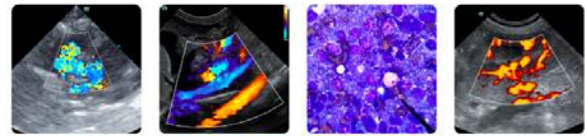
**INTERPRETATION OF THE FINDINGS & FURTHER RECOMMENDATIONS**

There is a large, multilobulated, irregular, heterogeneous mass effect visualized caudal to the stomach, extending almost to the level of the urinary bladder. This is strongly suspected to be of hepatic origin, but a direct vascular attachment is not clearly visualized, making an association with other structures such as the spleen, pancreas, etc. possible. Consider a fine needle aspirate of this lesion and a contrast CT scan to further evaluate for surgical removal. There are nodules visualized in the liver. These could represent unrelated regenerative nodules or metastatic lesions. If a safe window for sampling of a hepatic nodule is available, consider a fine needle aspirate.

Recommend three view thoracic radiographs to evaluate for possible concurrent thoracic disease/involvement (disregard if this has already been done).

Recommend sedation for future imaging to optimize image quality.





**PATIENT**

Ace Bellamy

**SPECIES**

Canine

**BREED**

Mini Pinscher

**SEX**

Neutered Male

**AGE**

9 Years

**WEIGHT**

18 Years

**INTERPRETED BY**

Kathleen Sennello DVM,  
 MS, Diplomate ACVIM  
 (Small Animal Internal  
 Medicine)

**IMAGING  
 PERFORMED BY**

Yvonna Aranda

**HOSPITAL NAME**

South Willamette  
 Veterinary Clinic

**REFERRING VET**

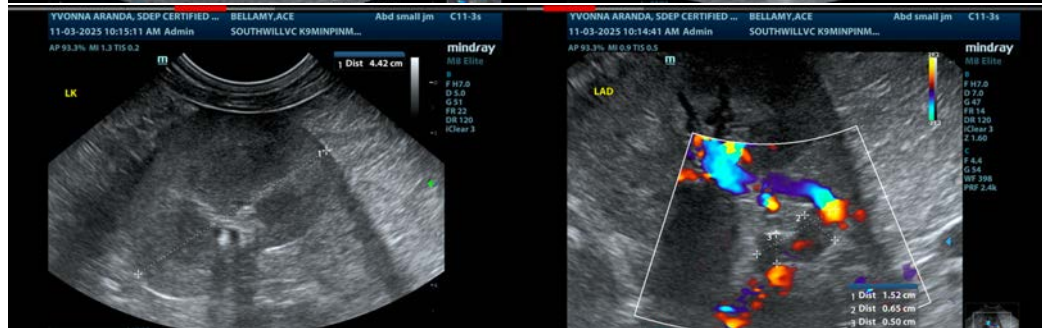
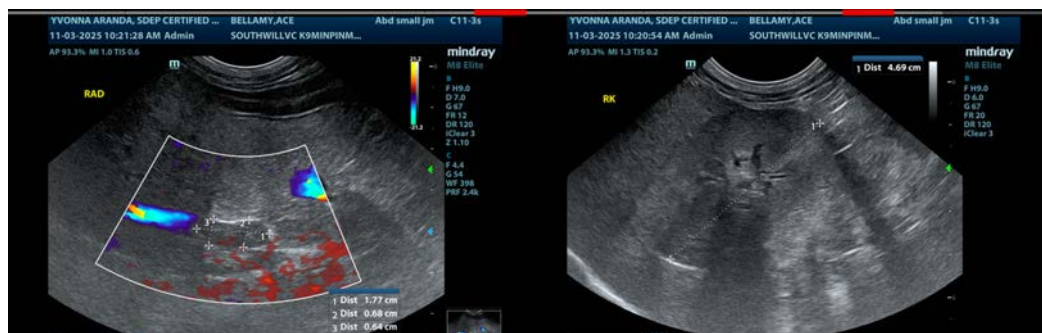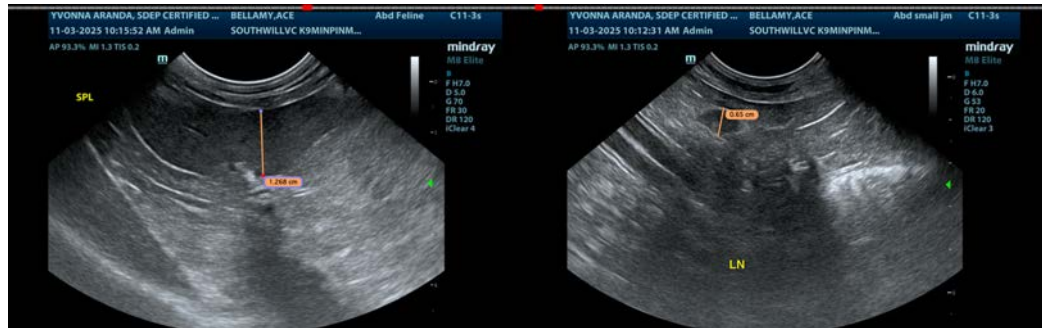
Dr. Willaman

**INVOICE**

71543

**DATE**

11/4/25



The information and recommendations provided are based on the images presented by the referring veterinarian/sonographer. No evaluation can be communicated regarding pathology that was not visible in the image/video clips provided.

Thank you for this referral. If the clinical or image interpretation does not parallel your findings or if I can be of any further assistance please contact me.

Kathleen Sennello DVM,MS, Diplomate ACVIM (Small animal Internal Medicine)

info@sonopath.com